

A Case Report Of A 14-Year-Old Male Patient With Breast Carcinoma

N Syeed, S Abdullah, A Sameer, M Siddiqi, N Chowdhri, S Hussain

Citation

N Syeed, S Abdullah, A Sameer, M Siddiqi, N Chowdhri, S Hussain. *A Case Report Of A 14-Year-Old Male Patient With Breast Carcinoma*. The Internet Journal of Surgery. 2009 Volume 24 Number 1.

Abstract

Breast carcinoma has been considered a female dominated disease, whereas male breast carcinoma is relatively rare accounting for less than 1% of all breast cancers. Cancer of the breast among men is rare, accounting for less than one percent of cancer incidence and mortality in this sex group. We present the case of a 14-year-old boy with infiltrating ductal breast carcinoma; this is the fifth report of the world and the third from India.

INTRODUCTION

Breast carcinoma has been considered as a female dominated disease, whereas male breast carcinoma is relatively rare accounting for less than 1% of all breast cancers (1). The peak incidence of the disease is usually around 60 years of age, and it is extremely rare in boys and young adults. Most of the cases are found to be infiltrating duct carcinomas (68%-94%), as in our case (2). Male breast carcinomas appear to be biologically similar to female breast cancers but there are some basic pathological differences. We found this rare case of breast carcinoma in a 14-year-old boy, which forms the source of this report.

CASE PRESENTATION

A 14-year-old male residing in south Kashmir, student by profession, visited our institute with the chief complaints of nipple discharge and severe pain in the right side of the chest. The patient was referred to the Medical Oncology Department for first-hand examination. On examination, it was found that the mass was painless, located at the lower inner quadrant of the right breast, firm to hard in consistency and not involving skin. Physical examination revealed palpable lymph nodes in the right axilla. Preliminary biochemical examination revealed the patient's Carcino-Embryonic Antigen (CEA) level to be 10 ng/ml (reference value: 0-3.7 ng/ml). Breast USG revealed a hypo-echoic and irregular solid lesion measuring 9.5 x 21 x 12mm. A provisional diagnosis of fibrous malignancy was made. The patient was then referred to the Department of Pathology for fine-needle aspiration cytology (FNAC) which confirmed the provisional diagnosis of fibrous carcinoma of the breast.

There were no distant metastases in chest radiography and abdominal ultrasonography (USG). The patient was then referred to the Department of General Surgery where a modified radical mastectomy (MRM) was performed as a curative measure of radical prevention of infiltration and metastasis. The excised tumor was subjected to a second histopathological examination which confirmed the FNAC findings but also revealed the actual tumor to be of 7.5 x 6 x 10mm. None of the lymph nodes dissected from the axilla was metastatic. Furthermore, the carcinoma was of infiltrating ductal type, with free surgical margin, ER/PR positive, and of stage IIA (T₃N₀M₀). All examinations were carried out by two independent and experienced pathologists. After the curative surgery, the patient received methotrexate 50 mg/m², and 5-fluorouracil 500 mg/m² on days 1 and 8, repeated every 28 days for six cycles, due to the large tumor size. The patient is disease-free and alive 12 months after surgery. The tumor tissue and the adjacent normal tissue of the patient were taken for mutational analysis of CAV-1 gene in our molecular biology laboratory.

Figure 1

Image showing the malignant tumor of the right breast.

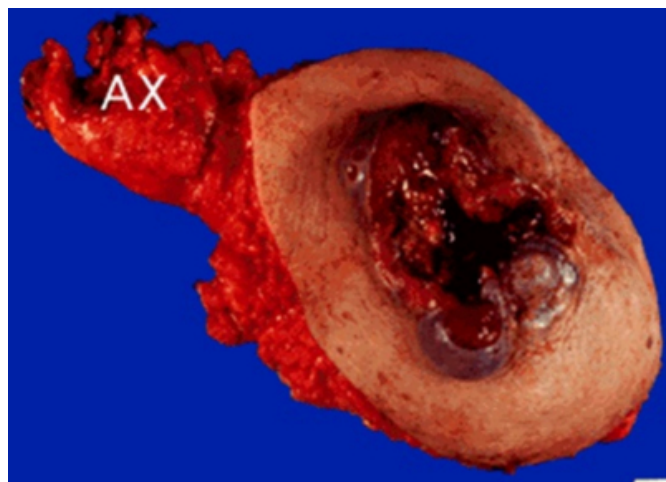
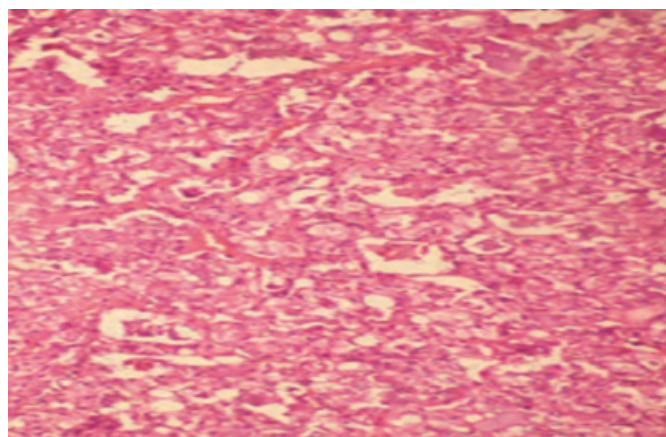


Figure 2

Photomicrograph showing infiltrating ductal carcinoma (H&E, $\times 100$).



DISCUSSION

Breast cancer is found to occur most commonly in middle-aged men, mostly at an advanced stage. Breast cancer in males is relatively rare and this is in accord with the general rule that cancer seldom occurs in vestigial organs (1). Breast cancer is more often hormone receptor-positive in men than in women, and approximately 80% of breast cancers in men have hormone receptors. Breast cancer occurs in males at relatively older age when compared to females and more often during the 5th to 7th decades of life (3,4,5,6), the main reason being late presentation and lack of self-awareness; men have more advanced disease at diagnosis and larger tumor size than women due to delayed diagnosis, resulting in a higher morbidity and mortality.

The youngest case of carcinoma of the male breast has been reported in a six-year-old male child by Hartman and

Magrith (7). Breast cancer incidence varies from 0.08 to 6.4% of total breast cancers, from 4.06% in India (8,9) to 0.06 in the West. A relatively high incidence of male breast malignancy has been reported (10) as 4.7%, and few others have reported it as 5.3% of total breast cancers (11). However, a somewhat lower incidence of 0.9 to 1.9% has been observed in male breast cancer by others (6, 12), some reported it as 1.8% (6), some as 2.6% (8) and few others as 2.3% as of total breast cancers (13). The male breast does not have lobular and acinar structures (14,15), in our case there also were no lobes or acini present.

Breast cancer is the third most common malignancy in the world (16). Breast cancer has been associated with a variety of risk factors (17), genetic and epigenetic changes (18). But its molecular pathogenesis remains somewhat unresolved. Environmental carcinogens have been shown to damage DNA at active fragile sites by disrupting surveillance, which has been shown to be tumorigenic (19,20). Development of human breast cancer is a multistep process, arising from genetic alterations that drive the transformation of normal mammary epithelial cells into highly malignant derivatives (21). The Caveolin 1 (CAV1) gene maps to 7q31.1 and encodes a 21- to 24-kDa integral membrane protein. CAV-1 is the principal structural protein of caveolae membranes that are found in most cells types, including mammary epithelial cells; the human CAV1 gene is a suspected tumor suppressor locus (7q31.1/D7S522) that is deleted in a variety of human cancers, as well as mammary tumors. Mutations in the gene encoding CAV-1 are associated with the development and progression of breast cancers. Moreover, on the molecular side we were able to detect CAV-1 mutations in this patient. We were able to detect a truncating mutation TGG>TAG leading to Trp>Stop codon at codon 128 of CAV-1 gene. The mutation was initially detected by allele-specific PCR, followed by conventional PCR-SSCP and then authenticated by DNA sequencing.

CONCLUSION

Our study showed the occurrence of male breast cancer in a young 14-year-old boy. This is the fifth report of the world and the third from India. Screening for male breast carcinoma is not practical due to the small percentage of involved patients. However, due to lack of self-awareness, these patients usually present late with delayed diagnosis, and larger tumor size resulting in a higher morbidity and mortality.

References

1. Payson BA and Rosh R: Carcinoma and other neoplasms of the male breast. *Radiology*; 1949; 52: 220-228.
2. Sasco AJ, Lowenfels AB, Pasker-de Jong P: Review. Epidemiology of male breast cancer. A metaanalysis of published case-control studies and discussion of selected aetiological factors. *Int J Cancer*; 1993; 53: 538-49.
3. Deodhar SD Mehendale VG: Carcinoma of the male breast. Report of 4 cases. *Ind J Surg*; 1978; 40: 514-516.
4. Kapur BML, Dhawan IJ, Gupta RK and Sinha SN: Clinicopathological study of breast tumours. *Ind J Cancer*; 1974; 2 (Supplement series No. III): 28-31.
5. Robins SL and Cotran RS: "Pathologic Basis of the Disease". 2nd Edition, W. B. Saunders Company, Philadelphia, London and Toronto, 1979, p. 1333.
6. Sirsat MV: Carcinoma of the male breast. - A study of 30 cases. *Ind J Surg*; 1957; 19: 83-86.
7. Hartman, AW and Magrith P: Carcinoma of breast in children. Case report. Six year old boy with adenocarcinoma. *Ann Surg*; 1955; 141: 792-798.
8. Dubey MM and Aggarwal S: Carcinoma of the male breast. *Ind J Surg*; 1971; 33: 62-65.
9. el-Gazayerli MM and Abdel-Aziz A: On bilharziasis and male breast cancer in Egypt. A preliminary report and review of literature. *Brit J Cancer*; 1964; 17: 566-571.
10. Sen AK and Das Gupta TK: Cancer of the breast and its treatment. *Ind J Surg*; 1982; 24: 833-847.
11. Dutta TK, Deka AC, Gupta BD and Kaushik SP: Carcinoma of the male breast. *Ind J Cancer*; 1975; 12: 67-71.
12. Somerville P: Carcinoma of the male breast. *Brit J Surg*; 1952; 39: 296-303.
13. Kapur BML, Dhawan IJ, Gupta RK and Sinha SN: Clinicopathological study of breast tumours. *Ind J Cancer*; 1974; 2 (Supplement series No. III): 28-31.
14. Willsher PC, Leach IH, Ellis IO, Bell JA, Elston CW, Bourke JB, et al.: Male breast cancer; pathological and immunohistochemical features. *Anticancer Res*; 1997;17:23 35-8.
15. Hecht JR, Winchester DJ: Male breast cancer. *Am J Clin Pathol*; 1994; 102 (4,suppl 1):S 25-30.
16. Sipetić S, Petrović V, Milić Z, Vlajinac H: Breast cancer incidence among women of Braničevo region in the period 1991-2000. *Med Pregl*; 2004; 57: 467-472.
17. Kaaks R, Rinaldi S, Key TJ, Berrino F, Peeters PH, Biessy C, et al.: Postmenopausal serum androgens, oestrogens and breast cancer risk: the European prospective investigation into cancer and nutrition. *Endocr Relat Cancer*; 2005; 12: 1071-1082.
18. Xie GS, Hou AR, Li LY, Gao YN, Cheng SJ: Aberrant p16 promoter hypermethylation in bronchial mucosae as a biomarker for the early detection of lung cancer. *Chin Med J*; 2006; 119: 1469-1472.
19. Gasser S, Raulet D: The DNA damage response, immunity and cancer. *Semin Cancer Biol*; 2006; 16: 344-347.
20. Arlt MF, Casper AM, Glover TW: Common fragile sites. *Cytogenet Genome Res*; 2003; 100: 92-100.
21. Hanahan D, Weinberg RA: The hallmarks of cancer. *Cell*; 2000; 100: 57-70.

Author Information

Nidda Syeed

Immunology and Molecular Medicine, Sher-I-Kashmir Institute of Medical Sciences

Safiya Abdullah

Immunology and Molecular Medicine, Sher-I-Kashmir Institute of Medical Sciences

A. Syed Sameer

Immunology and Molecular Medicine, Sher-I-Kashmir Institute of Medical Sciences

Mushtaq A. Siddiqi

Immunology and Molecular Medicine, Sher-I-Kashmir Institute of Medical Sciences

Nissar A. Chowdhri

General Surgery, Sher-I-Kashmir Institute of Medical Sciences

Syed Akhtar Hussain

Department of Biosciences, Jamia Millia Islamia