Management Of Unexpected Solid Benign Liver Tumors During Laparoscopic Surgery: Concerns A Propos Of One Case

H Konstantinidis, N Barbetakis, C Demertzidis, T Antoniadis, C Tsilikas

Citation

H Konstantinidis, N Barbetakis, C Demertzidis, T Antoniadis, C Tsilikas. *Management Of Unexpected Solid Benign Liver Tumors During Laparoscopic Surgery: Concerns A Propos Of One Case*. The Internet Journal of Surgery. 2006 Volume 10 Number 2.

Abstract

During the last two decades laparoscopic surgery became popular and has been used for the removal of several lesions and organs. Unexpected solid benign liver tumors are some of the incidental intraoperative findings which demand accurate diagnosis and appropriate treatment. The most common benign liver tumors include cavernous hemangioma, focal nodular hyperplasia, hepatic adenoma and nodular regenerative hyperplasia. Some of these tumors can cause serious complications, such as hemorrhage or malignant transformation. Thus, incidental discovery of solid benign hepatic tumors may require additional
therapeutic procedures. On occasion of a case, this article will focus on the
diagnosis and management of these tumors.

INTRODUCTION

During the early 1990s laparoscopic cholecystectomy became very popular all over the world and finally predominated over open surgical techniques.[1] Advances in laparoscopic technology have encouraged surgeons to extend this new approach to more exacting procedures, such as liver and other parenchymal organ surgery. It is generally accepted nowadays, that laparoscopic and minimal invasive surgery offer reduction of postoperative pain and disability, reduce hospital stay and patients' recovery time.[2]

Increased frequency of laparoscopic procedures is followed by a significant rate of unexpected findings during routine intraoperative examination of the abdomen. As a result, the initial surgical plan must be modified in several cases, in order to handle adequately these incidental findings. Laparoscopic removal of small tumors, located in anterolateral segments of the liver, can be accomplished safely, as long as enough experience in open hepatic surgery and mastery of laparoscopic skills are present.[3] Our aim is to present our concerns in the management of unexpected solid benign liver tumors during laparoscopic surgery a propos of one case treated in our department. Basic characteristics of the most common benign liver tumors and differential diagnosis criteria are also discussed.

CASE REPORT

A 31-year-old male patient was admitted to the operation room for laparoscopic cholecystectomy. He had an episode of acute cholecystitis 2.5 months ago, which was treated conservatively. His medical history was unremarkable. The patient underwent two sonograms before surgery. The first, during the cholecystitis episode, showed thickening of the gallbladder wall (15mm), a 2.5cm diameter gallstone and a mild inflammatory pericholecystic assortment. At the second sonogram, 40 days later, reduction of inflammatory signs was seen.

A standard four trocar placement was performed. During laparoscopy of the abdomen, after cephalic retraction of the gallbladder, a round shaped, solid tumor of about 3cm diameter was found at segment V of the liver, attached to the right side of the portal vein bipartition. The mass was lying on the hepatic surface, well circumscribed, lobulated, with a superficial central scar. Based on the macroscopic characteristics of the lesion, the most probable diagnosis was considered to be focal nodular hyperplasia, but without precluding the diagnosis of hepatic adenoma.

Resection was decided to be done, not only because of the dubiousness of the diagnosis, but also because of the

possibility of prospective portal vein or choledochal duct depression. A typical laparoscopic cholecystectomy was performed initially. The mass was afterwards easily retracted with a forceps and detached from liver surface and portal vein. Using an endoscopic ultrasonic dissector, the mass was resected and removed with a standard laparoscopic endobag. Biliary or vascular clipping was not needed and haemostasis was obtained by monopolar cautery. Biopsy revealed a scar compromising bile ductules, benign appearing hepatocytes (forming loosely cohesive sheets and clusters), cholangiolar proliferation with surrounding inflammatory infiltrates, and malformed vessels - except portal veins, all of them typical histological findings of FNH. The patient recovered normally with no complications, and was discharged home on the second postoperative day.

After surgery, the two sonograms were re-examined. At the first sonographic examination the region around the gallbladder was not imaged clearly because of local inflammatory phenomena. A more careful “second look” of that sonogram revealed a round shaped pattern of about 3cm diameter at segment V of the liver, beside and under the cervix of the gallbladder (Figure 1).

Figure 1

Figure 1: First sonogram showing acute cholecystitis phenomena due to solitary cholelithiasis. A solid, round shaped lesion is seen (camouflaged by pericholecystic inflammation and the acoustic shadow of the gallstone) at segment V of the right liver lobe.

At the second sonogram, reduction of the inflammatory phenomena was seen, but the pattern was again misdiagnosed, even though one could strongly speculate its existence at a more careful study of the examination (Figure 2).

Figure 2

Figure 2: Second sonogram, 40 days later. Reduction of inflammation can easily be seen. The acoustic shadow of the gallstone covers again the left edge of the lesion, probably deceiving the radiologist.

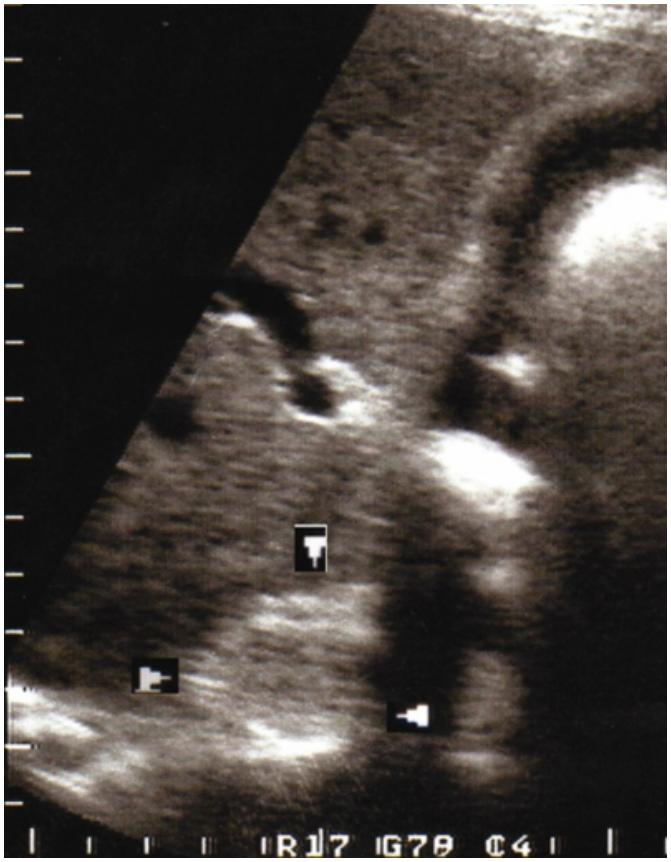

DISCUSSION

Small solid liver tumors, which eluded preoperative radiological examinations, can be a difficult clinical problem for the surgeon. Some of them are associated with serious complications, such as major haemorrhage or malignant transformation. Thus, the understanding of clinical, macroscopical, ultrasonographic (U/S) and microscopical characteristics of each tumor is important for accurate diagnosis and appropriate treatment.

Hemangioma is the most common benign hepatic tumor, with not well understood pathogenesis. According to autopsy series the incidence of hemangioma ranges from 3% to 20%, and most of them are seen in middle aged women.[4] They are usually located in the subcapsular region with diameter from 1 to more than 20 cm. Hemangiomas are well circumscribed and compressible tumors with dark colour. Major complications, such as spontaneous hemorrhage are rare even in large hemangiomas.[5] At intraoperative ultrasonography hemangioma typically appears as a well defined, lobulated, homogenous hyperechoic mass, or it can be hypoechoic due to hemorrhage.[6] Intraoperative biopsy is not suggested by all surgeons, because of the risk of hemorrhage.

Treatment is not indicated for asymptomatic patients with hemangiomas smaller than 5cm. Conservative treatment with 6 month interval radiological imaging studies can be followed. Indications for treatment include complications and inability to exclude malignancy. Treatment includes surgical enucleation, resection and chemoembolization.[7]

Focal nodular hyperplasia (FNH) is the second most common benign tumor of the liver and makes up approximately 8% of all primary hepatic tumors.[7] It is considered as a non neoplastic, but hyperplastic response to a congenital vascular malformation or liver trauma.[8] It usually occurs in childbearing aged women with a female to male ratio of 6 to 8:1. FNH most often presents as a solitary, well circumscribed, lobulated but not encapsulated tumor near the hepatic surface, with diameter less than 5cm, although multiple localization and larger dimensions are not excluded.[9] Spontaneous rupture leading to hemorrhage is extremely rare. Malignant transformation has not been clearly described in the international literature. The characteristic feature is a dense, central stellate scar and septa that radiate from the central scar. Biopsy reveals benign appearing hepatocytes, a scar compromised of bile ductules, cholangiolar proliferation with surrounding inflammatory infiltrates, and malformed vessels (except portal veins).[8] Intraoperative ultrasonography demonstrates a minor difference of echogenicity. FNH may be hypoechoic, isoechoic or slightly hyperechoic relatively to the surrounding hepatic parenchyma.[10] Treatment is not needed in patients with small and asymptomatic FNH. Radiological follow-up is usually suggested.

Resection is proposed in cases with undetermined nature of the tumor, possibility of prospective depression of portal vein or choledochal duct (as in our case), or suspicion of metastasis in patients previously operated for malignant diseases.[11] Instant laparoscopic removal of incidentally found benign hepatic lesions usually requires advanced laparoscopic skills and brings about a sum of intraoperative difficulties. This tactic can be argued by the option of better investigation and resection at a later stage. If resection of FNH or another benign lesion is decided, it can be performed with the use of ultrasonic dissectors, harmonic shears, stapling devices, crushing forceps, or endocauteries.[12]

Clipping or additional coagulation might be needed for parenchymal haemostasis or biliary control.[12]

Hepatic adenoma (HA), is a rare hepatic tumor that usually occurs in young women with a female to male ratio of 4:1. The pathogenesis of HA remains disputed, but the strong association with oral contraceptive use has been documented. Anabolic steroids may also increase the incidence, number and size of HA.[13] An other risk group for HA includes patients with glycogen storage diseases. HA may lead to spontaneous rupture, with severe and life threatening hemorrhage. Rare cases of malignant transformation have also been reported, especially in patients with large or multiple HA. Macroscopically, HA is usually solitary, well circumscribed, round, unencapsulated, but it often forms pseudo-capsules by compressing adjacent hepatic tissue. Hepatic adenomas have yellow tan colour, with a diameter up to more than 10cm. Intratumoral fat, necrosis, hemorrhage, or large vessels are commonly observed.[5] At intraoperative U/S, HA have variable and non specific appearances depending on the character of the tumor. Hyperechoic, hypoechoic or mixed echoic patterns represent simple adenoma, adenoma with fatty metamorphosis, hemorrhage or necrosis.[14] Microscopically, HA includes large plates of cells that resemble normal hepatocytes and are separated by dilated sinusoids, witch are perfused by many feeding arteries. Bile ductules are not found in HA.[15] Because of the possibility of spontaneous rupture and malignant transformation, HA must be identified and treated promptly. The treatment options include surgical enucleation and resection. Hepatic arterial embolization is also an effective option for the treatment of HA with acute hemorrhage.[16]

Nodular regenerative hyperplasia (NRH) is characterised by an accession of benign lesions with not well known pathogenesis. NRH is usually asymptomatic and discovered incidentally. Compression of the main portal vein can cause symptoms of portal hypertension.[6] Cholestatic symptoms can also occur. Macroscopically, NRH is characterized by multiple bulging regenerative nodules in clusters with a size raging from 0.1 to 4 cm. Biopsy reveals regeneration of hepatocytes with thickened regenerating hepatocytes and centrilobular atrophy.[16] In asymptomatic patients no treatment is recommended, except for periodic follow-up to monitor the development of hepatocellular cancer, although this is a rare complication. In patients with portal hypertension, appropriate management, including drug therapy, endoscopic therapy, or portocaval shunt is necessary.[16]

Macrogenerative nodules occur on the background of the cirrhotic liver and acute massive or submassive necrotic liver. Patients have no specific symptoms. The clinical importance of a macrogenerative nodule is its possible malignant transformation to hepatocellular cancer.[17] Macroscopically, a macrogenerative nodule has a greener or paler colour compared with the surrounding cirrhotic liver. Sometimes it demonstrates ischemic coagulative necrosis and hemorrhage, nuclear growing and microacinal formation that herald the development of hepatocellular cancer. Histological studies show cellular atypia in many cases.[16] Intraoperative U/S does not give valuable information.[18] A macrogenerative nodule is a benign but premalignant lesion, found in cirrhotic or fibrotic livers. Surgical resection is sometimes advocated, especially in those with atypia. The optimal management of a macrogenerative nodule remains unknown pending ongoing investigation.

In conclusion, the differential diagnosis of solid benign liver tumors remains difficult, even when modern imaging methods are used preoperatively. Unexpected detection of such findings during laparoscopy of the abdomen can be an accessional and complex problem for the surgeon. Intraoperative ultrasonography and biopsy, in combination with the knowledge of the clinical, macroscopical, and microscopical characteristics of each tumor, are important for accurate diagnosis and appropriate treatment.

CORRESPONDENCE TO

Dr Konstantinidis D. Harilaos Address: D. Karaoli 68 Kalamaria, Thessaloniki, TK: 55131. Telephone: 0030 6947560639, E-mail: haris4@panafonet.gr, Fax: 0030 2310421428

References

1. Dubois F, Berthelot G, Levard H. Laparoscopic cholecystectomy: historical perspective and personal experience. Surg Laparosc Endosc 1991;1:52-60
2. Soper NJ, Brunt LM, Kerble K. Laparoscopic general surgery. N Engl J Med 1994;330:409-419
3. Descottes B, Lachachi F, Sodji M, et al. Early experience with laparoscopic approach for solid liver tumors: Initial 16 cases. Ann Surg 2000;232(5):641-645
4. Merco PJ, Ros PR. Benign lesions of the liver. Radiol Clin North Am 1998;36:319-331
5. Trotter JF, Everson GT. Benign focal lesions of the liver. Clin Liv Dis 2001;5:17-42
6. Federle MB, Brancatelli G. Imaging of benign hepatic masses. Semin Liver Dis 2001;21:237-249
7. Buell JF, Thomas MJ, Doty TC, et al. An initial

experience and evolution of laparoscopic hepatic resectional surgery. Surgery 2004;136(4):804-811
8. Nguyen BN, Flejou JF, Terris B, et al. Focal nodular hyperplasia of the liver: a comprehensive pathologic study of 305 lesions and recognition of new histologic forms. Am J Surg Pathol 1999;23(12):1441-1454
9. Cherqui D, Rahmouni A, Charlotte F, et al. Management of focal nodular hyperplasia and hepatocellular adenoma in young women: a series of 41 patients with clinical, radiological, and pathological correlations. Hepatology 1995;22:1674-1681
10. Kehagias D, Moulopous L, Antoniou A, et al. Focal nodular hyperplasia: imaging findings. Eur Radiol 2001;11:202-212
11. Felsner J, Brody F. Laparoscopic resection for focal nodular hyperplasia. Surg Laparosc Endosc Percutan Tech 2003;13(4):276-279
12. Gigot JF, Glineur D, Santiago Azagra J, et al. Laparoscopic liver resection for malignant liver tumors: preliminary results of a multicenter European study. Ann Surg 2002;236:90-7
13. Cohen C, Lawson D, DeRose PB. Sex and androgenic steroids receptor expression in hepatic adenomas. Hum Pathol 1998;29:1428-1431
14. Von Herbay A, Vogt C, Haussinger D. Differentiation between benign and malignant hepatic lesions: utility of color stimulated acoustic emission with the microbubble contrast agent Levovist. J Ultrasound Med 2004;23:207-215
15. Herman P, Pugliese V, Machado MA, et al. Hepatic adenoma and focal nodular hyperplasia: differential diagnosis and treatment. Word J Surg 2000;24:372-376
16. Mortele KJ, Ros PR. Benign liver neoplasms. Clin Liver Dis 2002;6:119-145
17. Brunt EM. Benign tumors of the liver. Clin Liver Dis 2001;5:1-15
18. Krinsky GA, Lee VS, Theise ND, et al. Hepatocellular carcinoma and dysplastic nodules in patients with cirrhosis: prospective diagnosis with MR imaging and explantation correlation. Radiology 2001;219:445-454

Author Information

Harilaos D. Konstantinidis, M.D., Ph.D.
Departement of General & Thoracic Surgery, Theagenio Cancer Hospital

Nikolaos G. Barbetakis, M.D., Ph.D.
Departement of General & Thoracic Surgery, Theagenio Cancer Hospital

Charalampos I. Demertzidis, M.D., Ph.D.
2nd Departement of General Surgery, Hippokration General Hospital

Theodoros P. Antoniadis, M.D.
Departement of General & Thoracic Surgery, Theagenio Cancer Hospital

Christos G. Tsilikas, M.D.
Departement of General & Thoracic Surgery, Theagenio Cancer Hospital