

Ultrasound-controlled Acupuncture

G Litscher, N Yang, L Wang

Citation

G Litscher, N Yang, L Wang. *Ultrasound-controlled Acupuncture*. The Internet Journal of Anesthesiology. 1997 Volume 2 Number 4.

Abstract

The study describes a new construction and first measurements of simultaneous and continuous transcranial Doppler sonographic monitoring of the supratrochlear and middle cerebral arteries in two patients with ophthalmologic diseases, undergoing ultrasound-controlled acupuncture. When performing an eye acupuncture scheme, there was a significant increase in the mean blood flow velocity (vm) of the supratrochlear artery (+ 38% in patient 1; + 15% in patient 2; $p < 0.001$, t-test) in both patients. This effect was still evident after the needles were removed. There was a smaller increase in vm (+ 4% and + 3%; n.s.) in the middle cerebral artery. For the first time the new experimental arrangement seems to provide objectively measured proof regarding specific effect of acupuncture.

INTRODUCTION

Acupuncture has its origin in Traditional Chinese Medicine (TCM). Today, acupuncture is one of the most frequently used therapeutic methods worldwide. Conventional medicine primarily uses acupuncture as a complementary method of therapy. Hundreds of acupuncture points are located throughout the human body¹. According to the school and experience of TCM, the stimulation of these points can activate life energy, or "Qi". The most common manner is by using needles. By manipulating the needles under the skin, the therapist can induce further stimulation. Moreover, TCM teaches that the acupuncture points correspond to specific organs via meridians.

Recently, the investigation and quantification of the effects of acupuncture using modern biomedical monitoring methods has gained in importance. Initial evidence and promising results concerning measurable general effects of acupuncture in the brain, can be found in primary studies performed by our group^{2,3,4,5}.

In this study, a new transcranial Doppler sonographic (TCD) monitoring arrangement will be presented, which can simultaneously and continuously monitor the blood flow profiles of different cerebral vessels. For the first time, we can provide selective evidence with this method, concerning the specific effect of acupuncture on arterial vascular

structures of the cranium which is documented in this study.

METHODS AND MATERIALS


TCD-MONITORING ARRANGEMENT

A special bidirectional two-way spectacle probe holder was constructed for TCD-monitoring during acupuncture (Fig. 1). The sonographic signals were determined with a Multi-Dop T instrument (DWL Electronic Systems GmbH, Sipplingen, Germany) and a 2 MHz and 4 MHz probe was used.

Figure 1: Monitoring arrangement for simultaneous recording of Doppler sonographic signals in the right supratrochlear artery and right middle cerebral artery being fixed at the root of the nose and the outer auditory canal.

Figure 1

Figure 1



The orbital cavity was examined sonographically with the smallest power value able to reveal assessable signals (max. 20 mW/cm²). The blood flow profiles in the supratrochlear artery, the inner end branch of the ophthalmic artery, were measured transorbitally. This vessel can be easily isolated and is quite constant without direct scanning of the bulbous with ultrasonic waves⁶.

Monitoring of the supratrochlear artery was performed by lightly positioning the sound probe at the medial corner of the eye, in a slightly medial and parietal direction, using a specially constructed holder (compare Fig. 1). Under acoustic control, the angle and position of the probe was changed until the greatest possible signal amplitude was reached. In addition, changes in the blood flow velocity within the middle cerebral artery were registered continuously and simultaneously (compare Fig.1).

EVALUATED PARAMETERS

The mean blood flow velocity (vm) which can be determined from the Doppler frequency spectrum has proven to be an important parameter³. Contrary to the maximum value, vm can be determined without interference, even when undesirable signal noise is present.

In three phases (A: starting with five minutes before acupuncture, B: two minutes after positioning the needles, and C: five minutes after removal of the needles) the single values of vm were averaged (n = 400) in each patient. The averaged values of the three measured phases were then compared for each patient.

ACUPUNCTURE AND PATIENTS

Two patients from the Department of Ophthalmology of the University in Graz were examined. The patients were positioned in a relaxed and comfortable position on a bed during examination at the Biomedical Laboratory of the Department of Anesthesiology and Intensive Care Medicine in Graz. Then, the monitoring arrangement was carefully positioned. After a 10 minute resting period, the same acupuncture scheme was selected for both patients^{1,7,8}:

UB.2 ZANZHU

Location: On the medial end of the eyebrow, directly above the inner canthus of the eye.

Needling method: Perpendicular, 0.3-0.5 cun, then downward to point B 1 Jing Ming. The needle reaches M. frontalis and M. corrugator glabellae.

Indications: Frontal headache, migraine, impaired vision, tearing eyes caused by wind, red and swollen eyes, twitching eyelids¹.

SJ.23 SIZHUKONG

Location: In the small osseous depression on the lateral end of the eyebrow.

Needling method: Subcutaneously (horizontally) 0.5 to 1 cun in the sagittal direction towards the back or to the point Yuyiao.

Indications: Headache, facial nerve paralysis, strabismus, acute conjunctivitis¹.

SI.6 YANGLAO

Location: In the depression of the radial side of the styloid process of the ulna (channel in which the tendon of M. extensor carpi ulnaris is located). Since this depression is only easy to find when the hand is partially supinated, the patient is instructed to place his hand on his chest. The point then lies slightly proximal and radial from the processus styloideus ulnae.

Needling method: oblique, 0.3-0.5 cun toward the tendon in the proximal direction in order to avoid injury of the tendon itself.

Indications: Painful disorders along the channel e.g., painful restricted movement of the neck, shoulder, elbow or back, blurred vision¹.

GB.37 GUANGMING

Location: 5 cun proximal to the malleolus lateralis on the anterior side of the fibula.

Needling method: Perpendicular 0.7 -1 cun. The needle reaches the interosseal membrane and its vessels A./V. tibialis anterior and N. peroneus profundus, after passing through Mm. peroneus brevis and extensor digitorum longus.

Indications: Pain in the knee, pain and weakness in the lower extremities, eye pain, night blindness, optic atrophy, apoplexy, pain in the lateral side of the leg 1.

The points were punctured vertically with sterile, single-use needles (Huan Qui; Suzhou, China) after local disinfection of the skin. Stimulation was achieved by combining the rotation with the lifting and thrusting of the needles.

The experiments were conducted with the understanding and the consent of each subject, and the local ethical committee has approved the experiments.

STATISTICAL ANALYSIS

Statistical analysis was performed with the t-test with the support of the SigmaStat (Jandel Scientific Corp., Germany) computer program. The results were given as mean value \pm standard deviation. The criterion for significance was defined as $p < 0.001$.

RESULTS

PATIENT 1

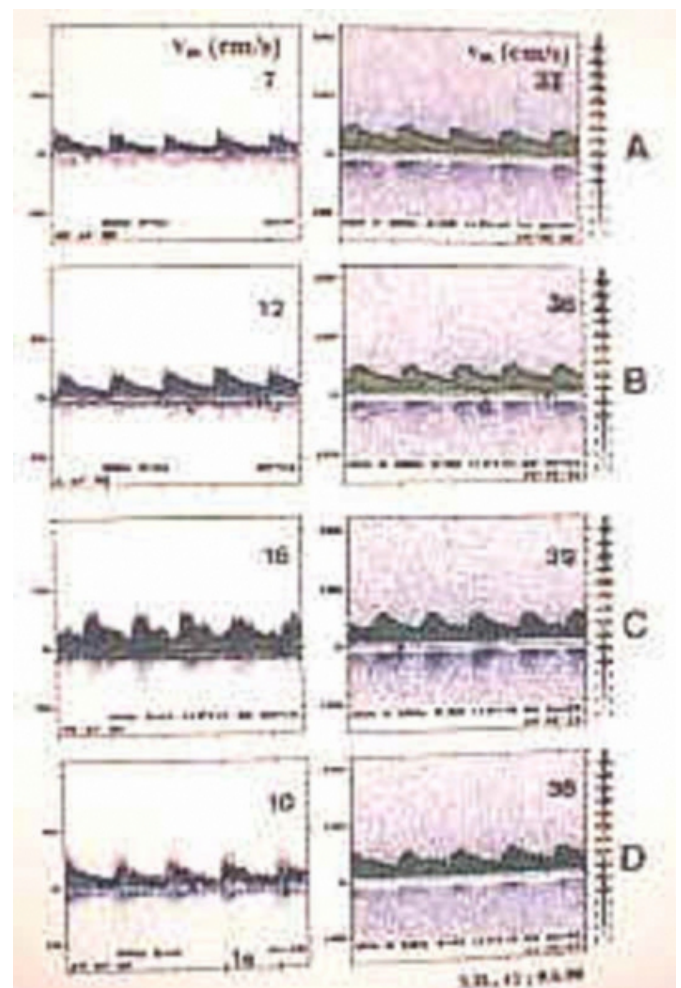
We report from a 41-year-old patient with bilateral pigmentary retinopathy since childhood suffering from night blindness and a concentric reduction of the visual-field.

Figure 2 shows 5.5 second sections of the blood flow profiles and the evaluation parameter v_m of the right supratrochlear artery (depth $D = 16$ mm) and the right middle cerebral artery (depth $D = 50$ mm). In this patient, a significant increase ($p < 0.001$) of v_m in the supratrochlear artery took place during acupuncture (A: 7.2 ± 0.7 , B: 11.6 ± 1.7 cm/s). Even after acupuncture, the specific effect of the increase in blood flow velocity in this particular vessel could still be registered and also reached the level of significance (C: 9.5 ± 2.2 cm/s). However simultaneously, when using the same acupuncture scheme, the changes in the v_m values during and after acupuncture in the middle cerebral artery were irrelevant (A: 36.0 ± 1.4 , B: 37.3 ± 2.0 , C: 37.5 ± 1.2 cm/s).

Figure 2: Example of changes in intensity of the TCD-color spectrum and representation of the mean flow velocity v_m in the supratrochlear artery and middle cerebral artery in patient 1. A: before acupuncture; B: immediately after acupuncture (Zanzhu); C: after positioning all needles; D: after removing needles.

Figure 2

Figure 2



PATIENT 2

A 26-year-old patient with keratoconjunctivitis was examined. Again, a significant increase in the mean flow velocity in the supratrochlear artery (A: 12.7 ± 1.0 , B: 14.9 ± 1.6 , C: 12.1 ± 1.3 cm/s) with a simultaneous minimal alteration in v_m in the middle cerebral artery (A: 44.4 ± 3.5 , B: 45.6 ± 3.0 , C: 43.7 ± 3.2 cm/s) occurred.

DISCUSSION

In addition to the ancient pre-scientific Chinese method of acupuncture, the patients were subjected to a modern method of biomedical research. The combination of high-tech and tradition showed the following: After the needles were

applied to special eye points the blood flow velocity in the supratrochlear artery increased significantly compared to the reference interval before acupuncture. This effect did not occur to the same extent in the middle cerebral artery. In this vessel, only a minimal but not significant increase in the blood flow velocity took place.

Already in 1987, Aaslid⁹ pointed out that a differentiation between the posterior cerebral artery and the superior cerebellar artery was possible with TCD by means of light exposition. When applying an optical stimulus, a 16% increase in blood flow through the posterior cerebral artery could be registered, however this did not take place in the superior cerebellar artery. When cognitive stimulation is used, changes (10-20% range) in the cerebral blood flow velocity during TCD-monitoring of the middle cerebral artery can occur which are dependant upon the particular process (calculation, memory, speech) and result in regional differences in activation¹⁰. In this connection, it is interesting that increases in blood flow velocity in the supratrochlear artery lies in the range of 38% (patient 1) and 15% (patient 2) in our study. This is higher than the values registered in the literature, when optical stimulation or cognitive processes were used. However, during the same time, an increase in the middle cerebral artery of only 4% (patient 1) and 3% (patient 2) occurred. To what extent the different diameters of the vessels influence the differences in blood flow velocity in these two arteries requires further investigation.

CONCLUSION

The results presented in this study could lead to extensive consequences in acupuncture research and practical clinical applications. For the first time, this experimental arrangement seems to provide objectively measured proof

regarding the specific effect of acupuncture on the brain. By using ultrasound-controlled acupuncture, the quality of patient treatment could be improved significantly. Extensive studies on test persons and patients must be performed to verify these results. Further investigations are definitely necessary to minimize the contradictions that often occur pertaining to the efficacy of acupuncture in western medicine. By using objective instrumental techniques, the gap between alternative and school medicine could be minimized leading to new possibilities in therapy.

References

1. Kitzinger E. Der Akupunktur Punkt: Topographie und chinesische Stichtechnik. Wien: Wilhelm Maudrich; 1995.
2. Litscher G, Schwarz G, Sandner-Kiesling A, Hadolt I: Transkranielle Dopplersonographie - Robotergesteuerte Sonden zur Quantifizierung des Einflusses der Akupunktur. Biomed. Technik 1997 42:116-22.
3. Litscher G, Schwarz G, Sandner-Kiesling A, Hadolt I, Eger E: Effects of acupuncture on the oxygenation of cerebral tissue. Neurol Res 1998; 20(S1):28-32.
4. Litscher G, Schwarz G, Sandner-Kiesling A, Hadolt I, Eger E, Lenhard H: Transcranial near infrared spectroscopy and Doppler sonography during acupuncture. In: Litscher G, Schwarz G, editors. Transcranial cerebral oximetry. Lengerich Berlin Dörf: Pabst Science Publishers; 1997. p.184-98.
5. Litscher G, Schwarz G, Sandner-Kiesling A, Hadolt I: Robotic transcranial Doppler sonography probes and acupuncture. Intern J Neurosci 1998; 95:1-15.
6. Keller H, Baumgartner G, Regli F: Carotisstenosen und -okklusionen. Diagnose durch perkutane Ultraschall-Doppler-Sonographie an der A. supraorbitalis oder A. supratrochlearis. Dtsch med Wschr 1973 98:1691-8.
7. Wenbin F: Clinical practice of eye acupuncture. Am J Acupuncture 1991 19:229-36.
8. Wong S, Ching R: The use of acupuncture in ophthalmology Am J Chin Med 1980 8:104-53.
9. Aaslid R: Visually evoked dynamic blood flow response of the human cerebral circulation Stroke 1987 17:771-5.
10. Diehl RR, Berlitz P: Funktionelle Dopplersonographie in der Neurologie. Berlin Heidelberg New York: Springer; 1996.

Author Information

Gerhard Litscher, Ph.D.

Nai-hua Yang, M.D.

Lu Wang, M.D.