

Testicular Microlithiasis: incidence In Symptomatic Patients And Its Association With Testicular Cancer

S Konstantinos, A Alevizos, B Konstantinos, M Anargiros, S Fragiskos

Citation

S Konstantinos, A Alevizos, B Konstantinos, M Anargiros, S Fragiskos. *Testicular Microlithiasis: incidence In Symptomatic Patients And Its Association With Testicular Cancer*. The Internet Journal of Urology. 2005 Volume 3 Number 2.

Abstract

Purpose: To determine prospectively the prevalence of testicular microlithiasis in symptomatic patients who were referred for scrotal ultrasound examination and to evaluate the possible association of testicular microlithiasis with testicular cancer.

Material and method: 391 men who were referred to our institution between July 02 and May 05 for any type of symptoms from the testicles underwent clinical examination and scrotal ultrasound examination. The presence of testicular microlithiasis, the number of lesions and the involvement of both testicles in relation to the symptoms and the coexistence of other lesions were studied. Patients found with testicular microlithiasis alone were submitted in biochemical tumour markers examination and placed in annual follow-up with physical examination and ultrasound.

Results: Eighteen (4.6%) of 391 men enrolled into the study had testicular microlithiasis. Two out of the eighteen patients (11%) had active testicular cancer which has been confirmed pathologically in the orchiectomy specimen. One of patients with testicular microlithiasis presented a rising in biochemical tumour markers (LDH, and HCG) and underwent orchidectomy one year later. Only five of the rest 373 (1.3%) patients without microlithiasis were found with active testicular cancer. The correlation between testicular cancer and testicular microlithiasis found in our study was confirmed with both parametric and non parametric tests ($P < 0.001$). The most commonly reported symptoms related to the presence of testicular microlithiasis alone were a dull ache or discomfort in the scrotum reported by all patients with testicular microlithiasis alone.

Conclusion: There is a possible association of testicular microlithiasis with testicular cancer in symptomatic patients.

INTRODUCTION

Microcalcifications can be found in inside the testicular parenchyma in 0.6-9% of men referred for testicular ultrasound (1,2,3). The clinical importance in terms of symptoms burden and potential malignancy is not well known. Microcalcifications themselves are not malignant but they have been reported in association with germ cell tumors in a variable proportion. Since the incidence seems to increase with the use of high-frequency ultrasound machines (4), the true incidence in the general population is unknown.

PURPOSE

To determine the prevalence of testicular microlithiasis in symptomatic patients who were referred for scrotal ultrasound examination and to evaluate the association of testicular microlithiasis with testicular cancer.

MATERIAL AND METHOD

Patients in this study included 468 men who were referred to our institution between July 02 and May 05 for any type of symptoms from the testicles (feeling of weight, pain, painful or painless inflation, etc). All were aged between 15 and 76 years (median age 45,5 mean age 37) and all were from Piraeus and suburban locations. There was no discretion in profession, social class and place of birth. Men were eligible for enrollment if they had not a primary diagnosis of testis cancer or any history of testis surgery and previous scrotal infection. All patients underwent clinical and laboratory examination and subjected to a scrotal ultrasound examination by two expert radiologists. Ultrasonographic criteria for the diagnosis of testicular microlithiasis were the presence of at least five pinpoint hyper echoic foci of size smaller than 3mm in scrotal ultrasound. per testicle in one field of view without posterior shadowing (5). The presence of testicular microlithiasis, the number of lesions and the

involvement of both testicles in relation to the symptoms and the coexistence of other lesions were studied. Patients found with testicular microlithiasis were submitted in biochemical tumour markers examination, chest x ray and if necessary in abdominal and pelvic CT and placed in semestral follow-up with physical examination and scrotal ultrasound. All patients underwent the appropriate therapy. The associations of pathologically confirmed testicular microlithiasis and testicular cancer were assessed with both parametric and non parametric statistical analyses. A P value of less than 0.5 was considered to indicate a statistically significant difference.

RESULTS

Eighteen (4.6%) out of 391 men enrolled into the study of had testicular microlithiasis. Testicular microlithiasis was the only finding in 10 patients, three patient had a concomitant varicocele, while both cases of torsioned cryptorchid testis had testicular microlithiasis in orchiectomy specimen. One of them was the only case of bilateral testicular microlithiasis. (Figure 1). From 12 patients diagnosed with torsion of the spermatic cord only one had testicular microlithiasis in orchiectomy specimen. From the remaining patients 149 had epididymitis, 78 patients had varicocele, 24 patients had blunt trauma on left or right testis, 17 had hernia, 14 spermatocele, 13 had an urinary stone in the lower third of left or right ureter, and 11 patients had periorchitis diagnosed clinically and confirmed with both laboratory and echographic examination. None of them had microcalcifications (in terms of testicular microlithiasis) in his scrotum ultrasound. Seven patients had testicular cancer diagnosed clinically and confirmed with both biochemical tumour markers and echographic examination. All cases of testicular cancer were germ cell tumours. Two of them had coexistent testicular microlithiasis confirmed pathologically in orchiectomy specimen (11.1%). Interestingly the number of calcifications in these cases was significantly higher than that obtained from normal testes. Only five of the 373 (1.3%) patients without microlithiasis were found with active testicular cancer. One of patients with testicular microlithiasis presented a rising in biochemical tumour markers (LDH, and HCG) and underwent orchidectomy one year later. No diagnosis was obtained for the rest of the cases. Even the low number of cases there is a clear correlation between testicular cancer and testicular microlithiasis confirmed with both parametric and non parametric tests ($P < 0.001$). The most commonly reported symptoms related to the presence of testicular microlithiasis alone were demersal pain and/or discomfort reported by all patients with testicular

microlithiasis alone. Additional symptoms such as painful or painless inflation, fever and scrotal tenderness are probably connected to coexistent conditions.

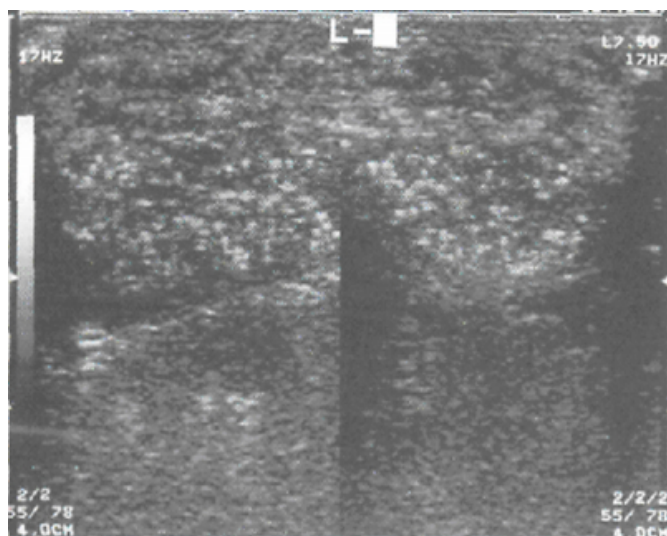
DISCUSSION AND CONCLUSIONS

Since the first description of this ultrasonographic entity (⁶), many studies have answered several important questions about the pathogenesis of this condition, however their biological meaning is not well known. Several authors suggested that testicular microlithiasis should be considered a premalignant condition but since wide variation in the reported incidence of Testicular microlithiasis in men with germ cell malignancy has been reported between different studies [6-75% (^{1,7,8,9})] the prognostic value of this entity as a precancerous lesion for testicular cancer remains controversial (¹⁰). Furthermore, whether TM is present before development of testicular germ cell tumours and the time needed to develop testicular cancer is not well known. In addition TM is more often found in men with a benign testicular condition [cryptorchidism, testicular dysgenesis, male infertility, testicular torsion and atrophy, Klinefelter's syndrome, hypogonadism, male pseudohermaphroditism, varicocele, epididymal cysts and non-Hodgkin's lymphoma) and the microcalcifications themselves are not malignant. Their correlation to these non malignant conditions is well documented (^{11,12,13})]. Testicular calcifications are heterogeneous. Two types of calcifications were mainly described: hematoxilin bodies consisting of amorphous calcific debris and laminated calcifications consisting of cellular debris and glucoprotein accumulation. While Hematoxilin bodies is been considered specific for germ cell tumors since are not seen in the absence of germ cell neoplasia, while laminated calcifications even more common in germ cell tumors also occur in otherwise normal testis. The pathogenesis of laminated microcalcifications is probably due to dysgenesis of the testis, with slough of degenerated cells inside an obstructed seminiferous tubule and failure of the Sertoli cells to phagocytize the debris. Secondly, calcification occurs. This may explain why microlithiasis is been found to accompany both germ cell tumours and non malignant conditions connected to infertility. Since the incidence of testicular microlithiasis and the incidence of coexistent testicular cancer was found in similar proportion the reported (0.6-9% and 6-75% respectively), our findings are generally in agreement with most of the aforementioned studies. Although bilateral microlithiasis has been connected to the pre-invasive stage of germ cells testicular cancer (¹⁴) this was not the case in

our study. Our finding of rapid onset of testis cancer (within 15 months) in a patient with known testicular microlithiasis is in agreement with several authors (₁₅) but is not in agreement to other [testicular cancer has been developed seven years after the primary diagnosis of testicular microlithiasis (₁₆)]. Testicular microlithiasis may cause a dull ache or discomfort in the scrotum. In such symptomatic patients, an ultrasonographic examination should be performed in order to exclude possible microlithiasis and a concurrent early stage testicular cancer.

Figure 1

Figure 1: Case of bilateral testicular microlithiasis



CORRESPONDENCE TO

Dr. Stamatiou Konstantinos Salepoula 2, 18536 Piraeus, Greece Tel: +302104526651 Fax: +302104296987 E-mail: alvise@tellas.gr

References

1. Parra BL, Venable DD, Gonzalez E, Eastham JA. "Testicular microlithiasis as a predictor of intratubular germ cell neoplasia". *Urology* 1996;48:797-799.
2. Peterson AC, Bauman JM, Light DE, McMann LP, Costabile RA. "The prevalence of testicular microlithiasis in an asymptomatic population of men 18 to 35 years old". *J. Urology* 2001;166:2061-2064.
3. Bach AM, Hann LE, Shi W, Giess CS, Yoo HH, Sheinfeld J, Thaler HT. Is there an increased incidence of contralateral testicular cancer in patients with intratesticular microlithiasis? *AJR Am J Roentgenol* 2003;180:497-500.
4. Pierik FH, Dohle GR, van Muiswinkel JM, Vreeburg JT, Weber RF. "Is routine scrotal ultrasound advantageous in infertile men?" *J. Urology* 1999;162:1618-1620.
5. Bach AM, Hann LE, Hadar O, Shi W, Yoo H, Giess C, Sheinfeld J, Thaler H. "Teasicular microlithiasis: What is its association with testicular cancer?" *Radiology* 2001; 220: 70-75
6. Doherty F., Mullins T., Sant G., Drinkwine M., Ucci A. "Testicular microlithiasis: a unique sonographic appearance". *J. Ultrasound Med.* 1987;6:389-392
7. Derogee M, Bevers RF, Prins HJ, Jonges TG, Elbers FH, Boon TA. "Testicular microlithiasis, a premalignant condition: prevalence, histopathologic findings, and relation to testicular tumor". *Urology* 2001;57:1133-1137.
8. Giwercman A, Muller J, Skakkebaek NE. "Prevalence of carcinoma in situ and other histopathological abnormalities in testes from 399 men who died suddenly and unexpectedly". *J Urology* 1991;145:77-80.
9. Patel MD., Olcot EW., Kershmann M., Gallen PW., Gooding GA. "Sonographically detected testicular microlithiasis and testicular carcinoma". *J. Clin. Ultrasound* 1993; 24: 447-452
10. Miller FN, Sidhu PS. Does testicular microlithiasis matter? A review. *Clin Radiol* 2002;57:883-990.
11. Vegni Talluri M., Bigliardi E., Vanni MG., Totz G. "Testicular microlithiasis: Their origine and structure". *J. Urol.* 1980; 124:1625-1628.
12. von Eckardstein S, Tsakmakidis G, Kamischke A, Rolf C, Nieschlag E. Sonographic testicular microlithiasis as an indicator of premalignant conditions in normal and infertile men. *J Androl* 2001;22:818-824.
13. Thomas K, Wood SJ, Thompson AJ, Pilling D, Lewis-Jones DI. The incidence and significance of testicular microlithiasis in a subfertile population. *Br J Radiol* 2000;73:494-497
14. de Gouveia Brazao CA, Pierik FH, Oosterhuis JW, Dohle GR, Looijenga LH, Weber RF. Bilateral testicular microlithiasis predicts the presence of the precursor of testicular germ cell tumors in subfertile men. *J Urol* 2004;171:158-160.
15. Frush D., Kliwer M., Madden J., Testicular microlithiasis and subsequent development of metastatic germ cell tumor. *AJR Am. J. Roentgenol.* 1996; 167: 889-890
16. Furness P., Husmann D., Brock J. Multi institutional study of testicular microlithiasis in childhood. *J. Urol* 1998; 160:1151-1154.

Author Information

Stamatiou Konstantinos

Department of Urology, (Department of Urology), (School of Medicine), Tzaneion General Hospital, (University of Crete)

Alevizos Alevizos

Department of General Practice/Family Medicine, Health Center of Vyronas

Bovis Konstantinos

Department of Urology, Tzaneion General Hospital

Mariolis Anargiros

Department of General Practice/Family Medicine, Health Center of Vyronas

Sofras Fragiskos

Department of Urology, School of Medicine, University of Crete