

Evaluation Of The Amount Of Intact Alveolar Bone In Dentulous Mandibular Ridges In Institution Of Rural Area: A Radiographic Study

A Naeem, U Pai

Citation

A Naeem, U Pai. *Evaluation Of The Amount Of Intact Alveolar Bone In Dentulous Mandibular Ridges In Institution Of Rural Area: A Radiographic Study*. The Internet Journal of Dental Science. 2008 Volume 7 Number 2.

Abstract

Objective: "EVALUATION OF THE AMOUNT OF INTACT ALVEOLAR BONE IN DENTULOUS MANDIBULAR RIDGES IN INSTITUTION OF RURAL AREA: A RADIOGRAPHIC STUDY"**Methods:**A study was conducted in a representative sample of randomly selected 30 subjects (19 males and 11 females), aged 20-65 years, by means of panoramic projectionOrtho Pantomogram (OPG) **Results:**The present study found (c/a) ratio of 2.72 ± 0.29 from a total of 30 radiographs analyzed. The use of data obtained might be the predicting of relative long-term success of complete denture for patients. For example, if the treatment plan for the two patients of the same age includes full extractions and complete dentures, the individual with the higher (c/a) ratio may be able to wear complete dentures more successfully for a longer period of time, simply more alveolar bone is available than in the other person. Patients with ratio on the lower end of 'normal' could more enthusiastically be encouraged to keep their teeth, if this is a reasonable treatment option. **Conclusion:**This study describes a method of estimating intact alveolar bone height on panoramic radiographs by using constant anatomic landmarks as reference points and calculating ratio of given distances between certain of these landmarks in dentate patients with no radiographic evidence of horizontal bone loss.

INTRODUCTION

Alveolar tooth atrophy following tooth extraction is a well recognized occurrence. Reduction of the mandibular ridge is particularly marked in comparison with the maxillary ridge. The use of lateral cephalograms for this purpose may involve a fairly large error since at times there is difficulty in differentiating the left and right sides on this type of projection and it may not always be useful for studying the alveolar bone loss. Since the panoramic projection (pantomograph) is a commonly used radiographic view in all disciplines of dentistry, methods of quantifying alveolar bone loss on panoramic films would be of value, particularly in clinical studies. Expressing the ratio of the height of alveolar bone to a measurable distance by using consistent anatomic landmarks is probably a better method. This study randomly selected 30 dentulous adult subjects showing minimal or no radiographic evidence of alveolar resorption. Analysis was made bilaterally at the sites of the mental foramen perpendicular to the inferior and superior borders of the body of the mandible by using a thin, transparent plastic millimeter scale. Measurements were made of the distance

from the lower edge of the mental foramina to the inferior surface of mandible and of the total height of mandible. Ratios were then calculated of the total height of the body of the mandible to the distance from the lower edge of the mental foramen to the inferior border of the mandible.

MATERIALS AND METHODS

A total of 30 panoramic radiographs of randomly selected subjects seen at Rural Dental College Loni, were studied to assess the normal height of mandible. These 30 radiographs were produced by Panorex-E machine.

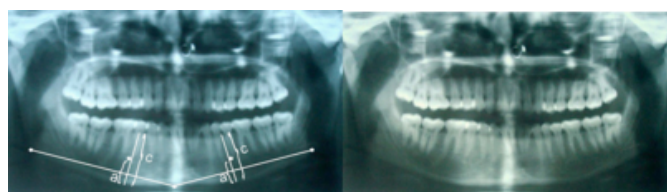
Criteria for selection of the radiographs:

- Only films of adult patients between 20-65 yrs of age or older were used,
- All teeth in the region of measurement had to be present and in normal relationship,
- Evidence of alveolar crest resorption in premolar and first molar regions was minimum or absent,

- Radiographic images of the mental foramen and the borders of the mandible were distinct.
- Radiographs had to be free of artefacts in the site of measurement,

One investigator was responsible for selecting the panoramic radiographs and performing the measurements. For the mandibular alveolar bone, the lower edge of the mental foramen was identified and traced. A line joining the most prominent point on chin the 'menton' and the most prominent point of the angle of mandible 'gonion' was drawn. By using a protractor, a line perpendicular to this tangent was drawn from the inferior mandibular border to the alveolar crest such that it intersected the inferior edge of the mental foramen. The technique was repeated on the opposite side of the mandible. The distance from the inferior surface of the mandibular body to the height of the alveolar crest was designated as 'c' and the distance from the inferior surface of the mandible to the inferior edge of the mental foramen was designated 'a'. The means and standard deviations of the ratio (c/a) were calculated.

Figure 1



RESULTS

The mean and standard deviation of the ratio (c/a) for all radiographs studied was calculated.

Figure 2

Table 1

Studies	Ratio	SD	No. of films taken
Wical & Swoope	2.90	± 0.23	130
Packta & Neufeld	2.60	± 0.30	309
Present study (Naeem et al)	2.72	± 0.29	30

Z=3.18 (P value is significant)

Figure 3

Table 2

Sex	No. of films taken	Ratio (c/a) mean	SD
Male	19	2.75	± 0.27
Female	11	2.70	± 0.32

Z=0.65 (P value is non-significant)

Figure 4

Table 3

Age Groups	No. of films taken	Ratio (c/a) mean	SD
20-35 yrs	16	2.83	± 0.20
36-50 yrs	7	2.73	± 0.23
50-65 yrs	7	2.61	± 0.42

DISCUSSION

Various studies done on the mandible have used mental foramen as a constant anatomic landmark based on the relative constancy of the relationship of the mental foramen to the inferior border of the mandible in spite of resorption of the edentulous alveolar process. Alveolar ridge height was expressed as ratios instead of absolute measurements because differences in patient size and positioning of patient may make absolute measurements less meaningful for purposes of comparison between patients and in the same patient at different times. In the present study, it was thought that by using a protractor to accurately determine the direction of the line perpendicular to the line joining the 'menton' and the 'gonion', more consistent results could be obtained. Wical & Swoope study found ratio (c/a) to be 2.90 ±0.23 in 130 radiographs G.Pakota & B.Neufeld study found ratio (c/a) to be 2.60 ±0.30 in 309 radiographs.

In comparison, the present study found (c/a) ratio of 2.72 ±0.29 from a total of 30 radiographs analysed. The use of data obtained might be the predicting of relative long-term success of complete denture for patients. For example, if the treatment plan for the two patients of the same age includes full extractions and complete dentures, the individual with the higher (c/a) ratio may be able to wear complete dentures more successfully for a longer period of time, simply more alveolar bone is available than in the other person. Patients with ratio on the lower end of 'normal' could more enthusiastically be encouraged to keep their teeth, if this is a reasonable treatment option.

CONCLUSION

This study describes a method of estimating intact alveolar bone height on panoramic radiographs by using constant

anatomic landmarks as reference points and calculating ratio of given distances between certain of these landmarks in dentate patients with no radiographic evidence of horizontal bone loss.

References

1. Tallgren A. The continuing reduction of the residual alveolar ridges in complete denture wearers: A mixed longitudinal study covering 25 yrs. J PROSTHET DENT 1972; 27:120-32.
2. Carisson GE, Ragnarson N, Asurand P. Changes in height of alveolar process in edentulous segments. A longitudinal clinical radiographic study of full upper denture cases with residual lower anteriors. ODONT TIDSKR 1967; 75:193-208.
3. Mercier P, Lafontant R. Residual alveolar ridge atrophy, classification and influence of facial morphology J PROSTHET DENT 1979;41:90-100.
4. Astrand P. Measurements on casts of the partially edentulous mandible. A method for registration of changes in height of the alveolar process. ODONT REV. 1969; 20:181-8.
5. Wical KE, Swoope CC. Studies of residual ridge resorption Part: 1 Use of panoramic radiographs for evaluation and classification of mandibular resorption. J PROSTHET DENT 1974; 32; 7-12.
6. Packota GV, Neufeld BD, Hoover JN. A study of the height of the intact alveolar bone on panoramic radiographs of adult patients. J PROSTHET DENT 1988; 80:504-509.

Author Information

Ahmad Naeem

PG student, Department of Prosthodontics, RDC

U. Pai

Senior Lecturer, Department of Prosthodontics, RDC