

Osteonecrosis in the Lateral Femoral Condyle following Core Decompression for medial Spontaneous Osteonecrosis

S Naqvi, S Gangoo, S Mirza, M Shannon

Citation

S Naqvi, S Gangoo, S Mirza, M Shannon. *Osteonecrosis in the Lateral Femoral Condyle following Core Decompression for medial Spontaneous Osteonecrosis*. The Internet Journal of Orthopedic Surgery. 2008 Volume 11 Number 1.

Abstract

Spontaneous Osteonecrosis of the Knee is a rare condition and is common after 60yrs of age with male to female ratio of 1:3. It commonly involves the medial femoral condyle and infrequently the lateral condyle with MRI being the investigation of choice. We present a case of Spontaneous Osteonecrosis in a 69 yr old male. MRI Scan showed Aglietti Stage1 osteonecrosis of the medial femoral condyle which was treated with core decompression. Arthroscopy was done at the time of Core Decompression and showed the knee joint to be absolutely normal. Another MRI scan was undertaken four months later to assess flare up of the symptoms and to our surprise showed resolution of the problems in the medial condyle and SPONK now in the lateral femoral condyle. The literature search didn't show any report of the recurrence in lateral condyle after medial condyle decompression.

INTRODUCTION

Spontaneous osteonecrosis of the knee (SPONK) was first described by Ahlback et al. (2) in 1968 and is the second most common site after the hip. It was defined as pain to the medial side of the knee in elderly people and was based upon its radiological and pathological features. Initial radiographs may be entirely negative or may typically show a subchondral radiolucent lesion in weight bearing surface of the medial femoral condyle. Scintimetry, even in the first few days may show increased uptake in medial condyle (8) but MRI has been reported to be more sensitive than scintigraphy.(7)

flare-up of symptoms at two months. Another MRI scan was undertaken to assess the situation and to our surprise showed resolution of the problems in the medial condyle and SPONK now in the lateral femoral condyle (Image 3). The patient decided not to go ahead with decompression due to personal reasons.

CASE REPORT

We present a case of 69 year old patient who presented with pain to the medial side of the right knee for 3 months and didn't recall any history of trauma. The examination of the knee was unremarkable. Plain radiographs didn't reveal any pathology (Image 1). MRI scan showed Aglietti Stage I Osteonecrosis of the medial femoral condyle (Image 2). The patient underwent arthroscopy of the knee which was normal. The patient was treated with core decompression and tissue was sent for histology. The histology showed normal tissue with minimal evidence of fat necrosis. He was mobilised touch weight bearing and initially made some improvement but before symptoms had resolved developed a

Figure 1

Image 1: Normal Appearance on Plain Radiograph

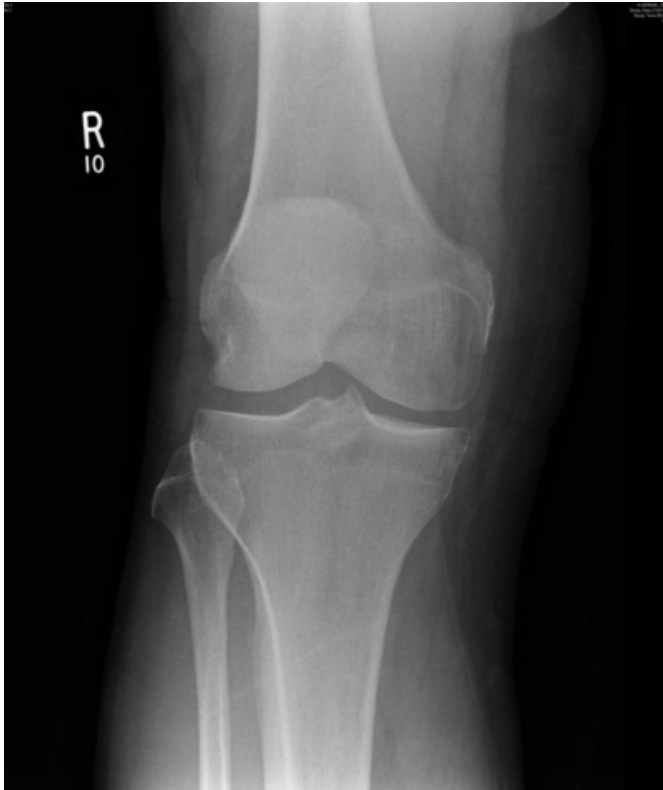


Figure 2

Image 2: SPONK of the Medial Femoral Condyle

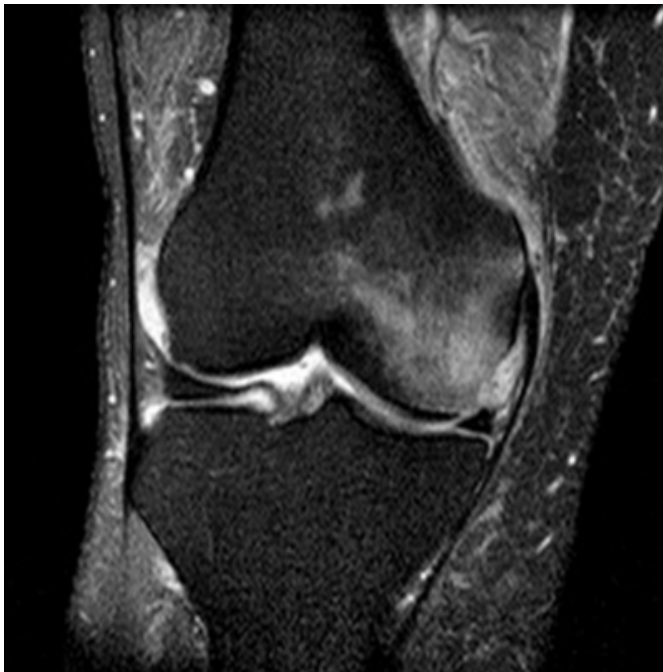
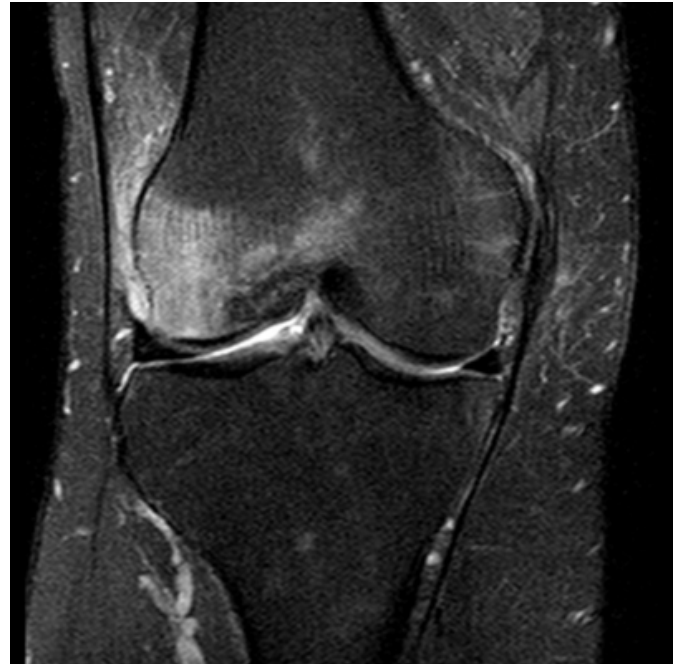
Figure 3

Image 3: SPONK of Lateral Femoral Condyle after Core Decompression



DISCUSSION

Etiology of spontaneous osteonecrosis is not well understood and two theories of pathogenesis have been advanced. The vascular theory proposes that interference with microcirculation by unknown cause produces edema in a nonexpendable bone marrow compartment. Edema leads to a rise in intraosseous pressure that further compromises blood flow, thus worsening ischemia and necrosis. Uchio et al. (6) hypothesized venous stasis in the medullary canal in the condyle increased intraosseous pressure and decreased arteriovenous pressure, leading to osteonecrosis.

Lotke and Ecker (5) suggested microfracture within osteoporotic subchondral bone might be the underlying cause of spontaneous osteonecrosis.

Aglietti (1) modified Koshino's classification system for SPONK.

- Stage I: Normal plain radiograph, MRI or bone scan needed for diagnosis.
- Stage II: Radiographs show flattening of the weightbearing portion of the condyle.
- Stage III: A radiolucent area surrounded by sclerosis on plain radiograph.

- Stage IV: Radiographs show a more defined ring of sclerosis, subchondral bone collapse forming a calcified plate, sequestrum, or fragment.
- Stage V: Narrowing of the joint space, osteophyte formation, and/or femoral and tibial subchondral sclerosis is shown.

The treatment options are either conservative or surgical. Lotke et al treated thirty six of eighty seven knees with SPONK conservatively (with protected weight bearing, physiotherapy and NSAIDS) with only 1 progressing to arthroplasty. (4)

Surgical options include Core Decompression, High tibial osteotomy, and Knee Arthroplasty. The principal behind core decompression is reduction of interosseous pressure, thereby restoring adequate circulation. Forst et al. treated five patients with early stage lateral spontaneous osteonecrosis with core decompression and reported it to be an effective treatment. Aglietti et al described thirty-one patients treated with high tibial osteotomy, reporting good results in 87% and only two knees progressed to arthroplasty. (1). Marmor reported an 89% success rate in a study of thirty-four knees with medial femoral condyle osteonecrosis treated with unicondylar replacement. (6) Total knee arthroplasty is recommended for late-stage of osteonecrosis with functional disability. It has had varying success with SPONK. Bergman and Rand (3) reported that 87% of thirty-eight knees treated with total knee arthroplasties had excellent or good results. Of those knees,

twenty-seven had SPONK, and nine had secondary osteonecrosis. These results were inferior to those of total knee replacements performed for other diagnoses.

We performed a literature search and were unable to find any published case of recurrence of osteonecrosis in the lateral femoral condyle following core decompression of the medial femoral condyle. We suggest that recurrence should be suspected in patients not having relief in symptoms following treatment and should be investigated again.

References

1. Aglietti P, Insall JN, Buzzi R Idiopathic osteonecrosis of the knee. Aetiology, prognosis and treatment. J Bone Joint Surg Br (1983) 65: 588-97
2. Ahlback S, Bauer GC, Böhne WH Spontaneous osteonecrosis of the knee. Arthritis Rheum (1968) 11: 705-33
3. Bergman NR, Rand JA Total knee arthroplasty in osteonecrosis. Clin Orthop Relat Res (1991) 273: 77-82
4. Lotke PA, Ecker ML Osteonecrosis-like syndrome of the medial tibial plateau. Clin Orthop Relat Res (1983) 176: 148-53.
5. Lotke PA, Ecker ML Osteonecrosis of the knee. Orthop Clin North Am (1985) 16: 797-807
6. Marmor L Unicompartmental arthroplasty for osteonecrosis of the knee joint. Clin Orthop Relat Res (1993) 294: 247-53
7. Pollack MS, Dalinka MK, Kressel HY, Lotke PA, Spritzer CE. Magnetic resonance imaging in the evaluation of suspected osteonecrosis of the knee. Skeletal Radiol (1987) 16: 121-7.
8. Rozing PM, Insall J and Böhne WH. Spontaneous osteonecrosis of the knee J Bone Joint Surg (Am) (1980) 62-A: 2-7
9. Uchio Y, Ochi M, Adachi N, Nishikori T and Kawasaki K Intraosseous hypertension and venous congestion in osteonecrosis of the knee. Clin Orthop Relat Res (2001) 384: 217-223

Author Information

Syed Ghafran Ali Naqvi, MRCS

Registrar Trauma and Orthopaedics, Weston General Hospital

Shafaat Gangoo, MRCS

Registrar Trauma and Orthopaedics, Weston General Hospital

Saqeb Mirza, MRCS

Registrar Trauma and Orthopaedics, Weston General Hospital

Mark Shannon, FRC SA(Orth)

Consultant Trauma and Orthopaedics, Weston General Hospital