

# Comparative Study of Laparoscopic versus Open Ventral Hernia Repair.

M Porecha, S Mehta, A Thanthvalia, D Udani

## Citation

M Porecha, S Mehta, A Thanthvalia, D Udani. *Comparative Study of Laparoscopic versus Open Ventral Hernia Repair..* The Internet Journal of Surgery. 2009 Volume 22 Number 2.

## Abstract

Ventral hernias (VH) occur as a result of weakness in the musculofascial layer of the anterior abdominal wall. The most popular classification is: congenital, acquired, incisional and traumatic. A successful series of laparoscopic repair for VH was done by LeBlanc in 1993. Operative costs may be optimized with selection of mesh and optimal use of trans-abdominal suture and fixation devices. This original article reveals recent advances and progression in laparoscopic ventral hernia repair technique, even in patients with incisional and umbilical hernia.

## INTRODUCTION

Ventral hernias (VH) occur as a result of weakness in the musculofascial layer of the anterior abdominal wall<sup>1</sup>. The most popular classification is: congenital, acquired, incisional and traumatic<sup>2</sup>. A successful series of laparoscopic repair for VH was done by LeBlanc in 1993<sup>3</sup>. Operative costs may be optimized with selection of mesh and optimal use of trans-abdominal suture and fixation devices. This original article reveals recent advances and progression in laparoscopic ventral hernia repair technique, even in patients with incisional and umbilical hernia.

## AIMS

The aim of this article is to compare the effectiveness and safety of laparoscopic and open repair of ventral hernia and to discuss important controversial issues for both procedures like,

1. Patient selection
2. Technique and operative care for laparoscopic repair of ventral hernia
3. Operative time of laparoscopic repair of ventral hernia
4. Intraoperative and postoperative complications
5. Postoperative pain and amount of different drugs used
6. Time until resumption of diet and movement

7. Postoperative morbidity
8. Length of hospital stay
9. Cost effectiveness and mesh selection
10. Recurrence and re-recurrence after both procedures.

## PATIENTS AND METHODS

This study which is non-randomized and prospective, involved 50 patients with ventral hernia that presented during the period of July 2006 to January 2007 in our institute (G.G. Hospital Jamnagar) and were subjected either to repair by laparoscopy or to open repair.

## INDICATION FOR LAPAROSCOPIC REPAIR OF VENTRAL HERNIA:

1. Ventral hernia more than 3cm in size.
2. Obesity and recurrent incisional hernia even with small size.
3. Swiss cheese type hernia (because clearer laparoscopically).

## CONTRAINDICATIONS

1. Multiple scars on the abdominal wall, which make intra-peritoneal access difficult<sup>3</sup>.
2. Large defect where 3 to 5 cm meshes overlap is not

possible intra-abdominally<sup>2</sup>.

3. Patient with large amount of redundant skin and fat on the abdominal wall are better suited for abdominoplasty procedures<sup>3</sup>.
4. Infection and peritonitis.
5. Acute and subacute intestinal obstruction.
6. Severe cardiopulmonary disease.
7. Portal hypertension.

## **RISK FACTORS**

Morbid obesity, prostatism, chronic cough, wound infection, large incision, and malnutrition are considered as risk factors for ventral hernia and incisional hernia<sup>6</sup>.

## **EVOLUTION OF LAPAROSCOPIC REPAIR OF VENTRAL HERNIA**

Laparoscopic repair of ventral hernias was done at a time when laparoscopic appendectomy and cholecystectomy had shown definite benefit over open procedures. Although technically demanding and time-consuming<sup>9</sup>, it is safe and feasible. With introduction of different prosthetic meshes and great improvement in the laparoscopic techniques, it is hoped that an improvement in the complication rate would be realized<sup>8</sup>. Increasing application of laparoscopic surgery all over the world indicates that these goals might indeed be achieved. There are many controversies but laparoscopic surgery continues to evolve with regard to laparoscopic repair of ventral hernias and there is more data in the literatures available as compared to the past due to the increased popularity of this procedures<sup>5</sup>.

## **OPERATIVE PROCEDURES**

In our study, 25 patients underwent open repair and 25 patients underwent laparoscopic repair of ventral hernia.

## **OPEN MESH TECHNIQUES**

Open surgical technique was popularized by Rives, Stoppa and Wantz<sup>3</sup>. After taking patients to operation theater and under general anesthesia, endotracheal intubation and close monitoring, the operation started. Foleys catheter was put for patients with lower abdominal ventral hernia repair and nasogastric tube for upper abdominal hernia repair with perioperative single-dose antibiotic in form of cefotaxime. Then, after proper cleaning, painting and draping of the abdomen, the skin incision was made according to site and

size of defect, a subcutaneous flap was raised up to 3 to 5cm around the defect and after the hernia sac was found, the contents were reduced. Then posterior rectus sheath and muscle were dissected, and rectus muscle and peritoneum in the lower abdomen. The posterior rectus sheath and peritoneum were closed primarily with 2:0 absorbable suture, then polypropylene meshes of suitable size with a minimum of 3cm overlap beyond the margin of the defect were placed over posterior rectus sheath/peritoneum and rectus muscle and fixed in four corners with 2:0 polypropylene sutures taken out through abdominal muscle on the anterior rectus sheath. The anterior rectus sheath was closed over the mesh with a loop of polypropylene or nylon without tension. Then the skin was closed over the drain depending upon size and extension of the wound.

## **LAPAROSCOPIC REPAIR OF VENTRAL HERNIA**

Almost all types of ventral hernia can be repaired by minimal access surgical techniques and it should be clear to the patient that laparoscopic repair will not help cosmetically if the skin is lax, hanging loosely in large hernias. In laparoscopic repair of ventral hernia, evacuation of the urinary bladder in lower abdominal surgery and nasogastric tube in upper abdominal surgery is a must, because in most cases the access is through Palmer's point, 2 to 3cm below the left costal margin in the mid-clavicle line. Bowel should be prepared to make more room in the abdominal cavity.

Laparoscopic repair of ventral hernia can be done with intraperitoneal meshplasty.<sup>7</sup>

## **ANESTHESIA**

General anesthesia with endotracheal intubation, close monitoring, I.V. cannula and proper fluid and electrolyte balance

## **PATIENT POSITION**

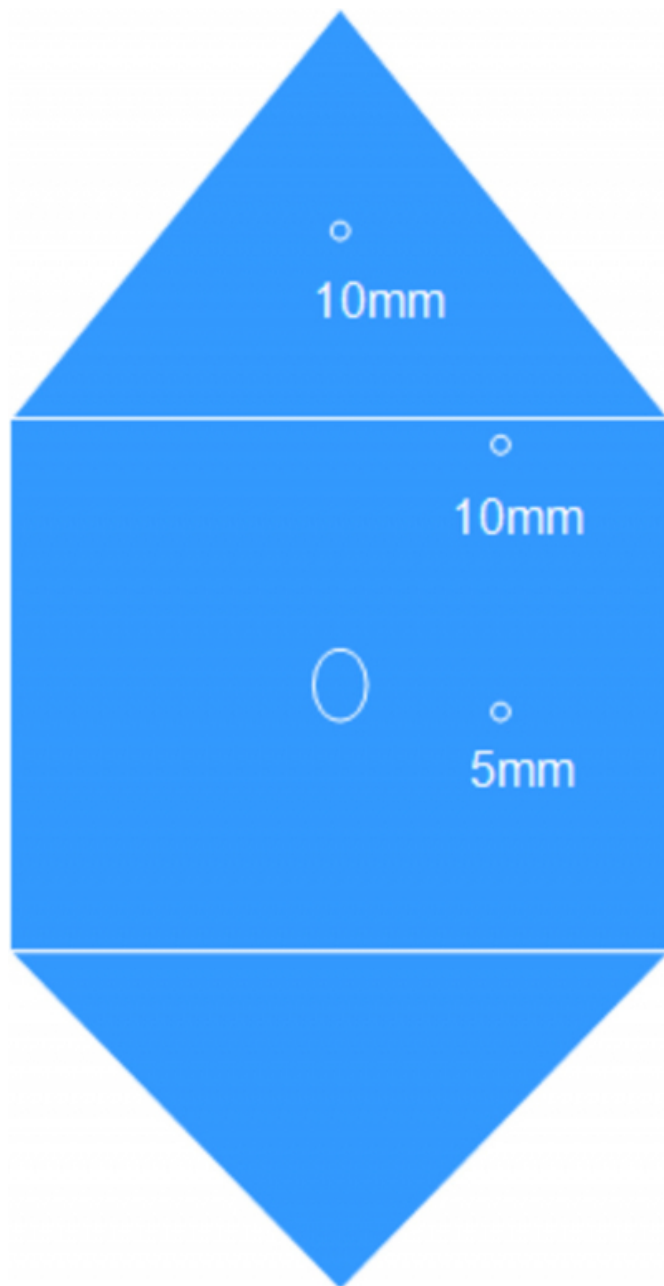
Supine position without any tilt, so that the bowel is distributed evenly

## **POSITION OF SURGICAL TEAM**

The surgeon stands left to the patient with the camera man on his left or right depending upon the location of the ventral hernia. If the hernia is below the umbilicus the camera operator stands right to the surgeon and if the defect is above the umbilicus, the camera operator should stand left to the surgeon. The monitor should be placed opposite to the surgeon and the instrument trolley should be towards the leg of the patient.<sup>3</sup>

**Figure 1**

Port position



### **PORT PLACEMENT TECHNIQUE AND OPERATIVE PROCEDURE**

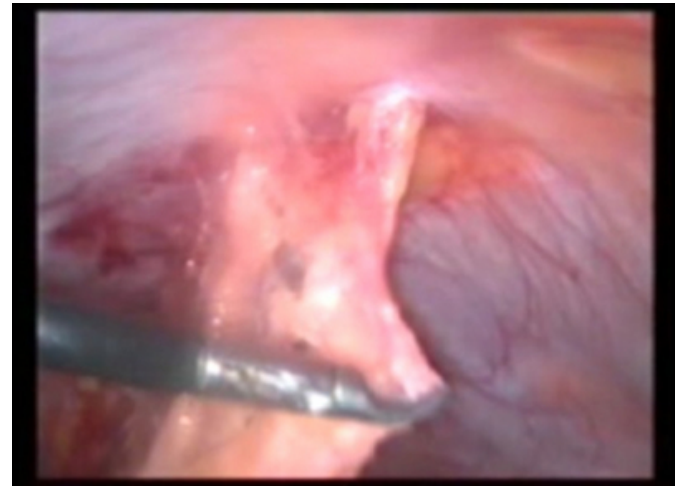
The patient should be cleaned, painted and draped with checking light cable, insufflation tube, electro-surgical cautery wires and suction/irrigation tube. A 10mm-trochar is inserted in the epigastrium with open method and the pneumoperitoneum is created. Once the pneumoperitoneum is created, a 5-mm port and another 10mm-port are put under vision according to the Baseball diamond concept, after diagnostic laparoscopy.

If there is any adhesion, careful adhesiolysis is performed

and the content of the hernia sac which is either omentum or bowel is returned as shown below.

**Figure 2**

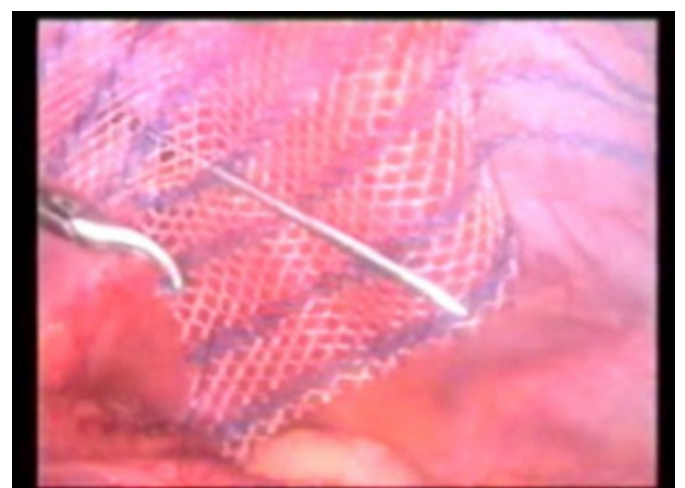
Fig. 1: Contents in the sac separated



Then the extent of the defect is assessed thoroughly. The measurement of the defect is drawn on the external surface of the anterior abdominal wall and a mesh of adequate size that covers the whole defect overlapping up to 3 to 5cm from the edge is selected. All the necessary precautions are to be taken to avoid contamination of the mesh with skin pathogens. Then the mesh is rolled and inserted in a port of adequate caliber to the abdominal cavity, the mesh is unrolled and fixed by stitches to the abdominal wall without dissecting peritoneum. This is called onlay technique.

**Figure 3**

Fig. 2: Mesh fixation

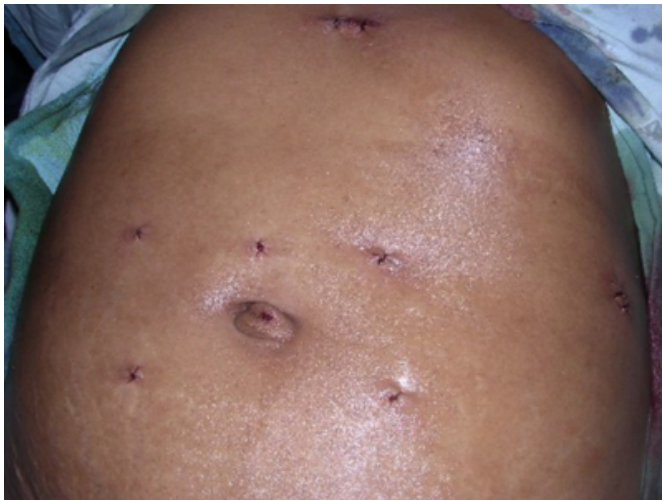

.Finally the omentum is laid over the underlying bowel loops to prevent direct contact with the mesh. After completing the procedure the ports are withdrawn under vision and the

telescope port is the last to be removed with keeping some instrument or the telescope itself inside to prevent traction of any part of omentum or bowel. The insertion sites of the 10mm-ports are better repaired because of the chances of incisional hernia. A sterile dressing is applied.

**Figure 4**

Fig. 3: Post-operative scars after laparoscopic ventral hernia repair



## CHOICE OF MESH

Meshes for laparoscopic hernia repair have undergone many changes over the last several years. In general, the ideal mesh is characterized by economic aspects, functionality and operative handling, sterility or even anti-infectivity and optimized biocompatibility<sup>8</sup>, and all seek to achieve two goals:

1. Rapid and permanent ingrowth into the prosthesis
2. Diminution of the risk of intestinal adhesion

There are two types of mesh: synthetic and collagen-based ePTFE<sup>8</sup> (expanded

polytetrafluoroethylene) were used with polypropylene. Because of a low affinity for adhesion, the PTFE mesh is probably the first choice for an intraperitoneal position of the prosthesis. In summary, the use of a mesh can reduce the recurrence rate from 40-50% to about 10% only.<sup>2</sup>

## VENTRAL HERNIA AND OPERATION CHARACTERISTICS

The most frequent content of the hernia sac was omentum, there were no intraoperative complications such as bowel or vascular injury requiring conversion to open technique and,

significantly, there was not much blood loss, no patient required blood transfusion. A closed suction tube was put more often for open procedures. The majority of incisional hernias in the lower abdomen were due to gynecological operations and primary ventral hernias were located at or around umbilicus.

## POSTOPERATIVE COMPLICATIONS

### 1. Wound infection

Wound-related infection was less frequent in laparoscopic repair and few of the patients required drainage and antibiotic cover in comparison with open cases.

### 2. Mesh infection

Mesh infection was very rare when compared to the open technique; skin pathogens were responsible for most of the infections. Infections with polypropylene mesh can be managed locally but infections with ePTFE meshes need removal of the mesh.

### 3. Seroma formation

Seromas develop above the mesh and within a retained hernia sac; the mean incidence is at 4 to 8 weeks (11.4%). They rarely result in long-term problems, only aspiration may be recommended for those who enlarge or persist before they reach a large size.

### 4. Recurrence

The incidence of recurrence of ventral hernia described in the literature is decreasing depending upon treatment of infection, adequate mesh fixation, adequate overlap and diagnosing missed hernias laparoscopically; however, few cases of re-recurrence were reported in some articles.

### 5. Chronic pain

After laparoscopic repair of ventral hernia, chronic pain at suture sites is not uncommon. A possible explanation may be due to trans-abdominal sutures entrapping intercostals nerves as they course through abdominal muscles, and local ischemia of the port is another possibility. Treatment is by NSAIDs and local anesthetic injection.

### 6. Postoperative morbidity

Postoperative morbidity may be due to unrecognized enterotomy, wound infection, intraperitoneal abscess or respiratory failure. Such complications increase the duration of hospital stay and costs.

## RESULTS OF OUR STUDY

**Figure 5**

Table 1

	Laparoscopic repair	Open repair
<b>No. of patients</b>	<b>25</b>	<b>25</b>
<b>Types of hernia</b>		
1) incisional	14	20
2) umbilical	06	04
3) paraumbilical	02	01
4) epigastric	03	00
<b>Duration of operation (min.)</b>	<b>100</b>	<b>120</b>
<b>Postop. hospital stay (days)</b>	<b>03</b>	<b>07</b>
<b>Analgesic requirement (days)</b>	<b>03</b>	<b>07</b>
<b>Antibiotic requirement (days)</b>	<b>02</b>	<b>07</b>
<b>Postop. NBM (days)</b>	<b>01</b>	<b>03</b>
<b>Complications</b>		
1) bleeding	02	05
2) bowel injury	00	02
3) wound infection	01	04
4) recurrence	00	01
<b>Return to normal activities (days)</b>	<b>08</b>	<b>20</b>

## DISCUSSION

Laparoscopic ventral hernia repair was started by LE BLANC in 1993. After that, evaluations were done to make laparoscopic surgery easier and safer for ventral hernia repair.

The results of our non-randomized controlled study revealed that, as compared to open repair, laparoscopic repair is associated with lesser time for surgery, reduced post-operative pain, analgesic requirement and antibiotic requirement, shorter hospital stay and earlier return to normal daily activities. The complication rate for

laparoscopic repair was low. The laparoscopic procedure was associated with potentially less wound infection compared with open repair.

The excellent results of our study are quite comparable with other studies as shown in table 2, which supports our strong recommendation that laparoscopic ventral hernia repair should be the procedure of choice in an experienced laparoscopic surgeon's hand. Comparison of our study with other studies is as follows:

**Figure 6**

TABLE 2: Comparison with other studies

Observation	Holzman <sup>4</sup>		Park <sup>10</sup>		Carbajo <sup>7</sup>		Ramshaw <sup>11</sup>	
	Lap/Open		Lap./Open		Lap./Open		Lap./Open	
<b>Operating time (min.)</b>	128	98	95	78	87	112	58	82
<b>Length of stay (days)</b>	1.6	05	3.4	6.5	2.2	9.1	1.7	2.8
<b>Postop. complication rate (%)</b>	23	31	18	37	20	50	15	26
<b>Infection rate (%)</b>	05	06	00	02	00	18	00	03
<b>Seroma rate (%)</b>	05	00	04	02	13	67	00	00
<b>Follow-up (months)</b>	10	19	24	54	27	27	21	21
<b>Recurrence (%)</b>	10	13	11	35	00	07	03	21
<b>Patients</b>	20	16	56	49	30	30	79	174

## CONCLUSION

Nowadays, laparoscopic repair of ventral hernia is being accepted by most of the surgeons and patients. Almost all ventral hernias can be repaired by laparoscopy, regardless of morbid obesity and age group. It is believed that laparoscopic repair is beneficial in terms of less post-operative pain, shorter hospital stay, less wound infection, less cost and less recurrence. It is even possible to reduce operative time because of standardized techniques, surgeons

getting more skill, use of mesh fixation devices and new mesh implantation. So, laparoscopic repair is considered as first choice for ventral hernia repair.

## References

1. Bailey and Love's Short Practice of Surgery, 24th edition, pp. 1272-1293.
2. Zinner MJ, Ashley SW: Maingot's Abdominal Operations, 11th edition, pp. 1138-1143.
3. Bruce Ramshaw: Mastery of Surgery, 5th edition, pp. 1947-1964.
4. Holzman MD, Purut CM, Reintgen K, Eubanks S, Pappas TN: Laparoscopic ventral and incisional hernioplasty. Surg Endosc; 1997; 11: 32-5.
5. Chowbey Pradeep K, Sharma Anil, Mehrotra Magan, Khullar Rajesh, Soni Vandana, Baijal Manish: Laparoscopic repair of ventral/incisional hernias. Journal of Minimal Access Surgery; 2006; 2: 192-198.
6. Muysoms F, Daeter E, Vander Mijnsbrugge G, Claeys D: Laparoscopic intraperitoneal repair of incisional and ventral hernias. Acta Chir Belg; 2004; 104: 705-8.
7. Carbajo MA, Martin del Olmo JC, Blanco JI, de la Cuesta C, Vaquero C, Inglada L: Laparoscopic treatment versus open surgery in the solution of major incisional and abdominal wall hernias with mesh. Surg Endosc; 1999; 13: 250-2.
8. Lau H, Patil NG, Yuen WK, Lee F: Laparoscopic incisional hernioplasty utilising on-lay expanded polytetrafluoroethylene DualMesh: prospective study. Hong Kong Med J; 2002; 8: 413-7.
9. Pham CT, et al.: Laparoscopic Ventral Hernia Repair: An Accelerated Systematic Review. ASERNIP-S Report No. 41. Adelaide, South Australia: ASERNIP-S, July 2004. <http://www.surgeons.org/asernip-s>
10. Park A, Birch DW, Lovrics P: Laparoscopic and open incisional hernia repair: A comparison study. Surgery; 1998; 124: 816-21; Discussion 831-2.
11. Ramshaw BJ, Esartia P, Schwab J, Mason EM, Wilson RA, Duncan TD, Promes J: Comparison of laparoscopic and open ventral herniorrhaphy. Am Surg; 1999; 65: 827-31; discussion 831-2.

**Author Information**

**M. M. Porecha, (M.S.)**

Senior Associate Professor & Laparoscopic Surgeon, Department of General Surgery, M.P.Shah Medical College and G.G.Hospital

**S. G. Mehta, (M.S.)**

Senior Professor & Laparoscopic Surgeon Head of Department, Department of General Surgery, M.P.Shah Medical College and G.G.Hospital

**Arvind Thanthvalia**

Senior Resident Doctor, Department of General Surgery, M.P.Shah Medical College and G.G.Hospital

**Dhaval Udani**

Assistant Professor and Laparoscopic Surgeon, Department of General Surgery, M.P.Shah Medical College and G.G.Hospital