

An Unusual Presentation Of Perineal Sinus: A Case Report

S Duvvura, R Singh, K Anwar

Citation

S Duvvura, R Singh, K Anwar. *An Unusual Presentation Of Perineal Sinus: A Case Report*. The Internet Journal of Gynecology and Obstetrics. 2006 Volume 7 Number 1.

Abstract

Foreign body in the form of vegetable debris in a perineal sinus is an unusual presentation. A high index of suspicion of a foreign body was present because of persistent non healing sinus, but finding vegetable debris in it was a surprise.

INTRODUCTION

Foreign body is the most common cause of non healing sinus. A perineal sinus with vegetable matter is a very rare presentation. We are reporting an unusual case of vegetable debris in a perineal sinus.

CASE REPORT

A 54 year old lady was referred to the gynecology outpatients for a suspected Bartholin's sinus. She complained of perineal discomfort and discharge for a couple of months and was treated with antibiotics with no relief. Significant past history included incision and drainage of a Bartholin's and a perineal abscess.

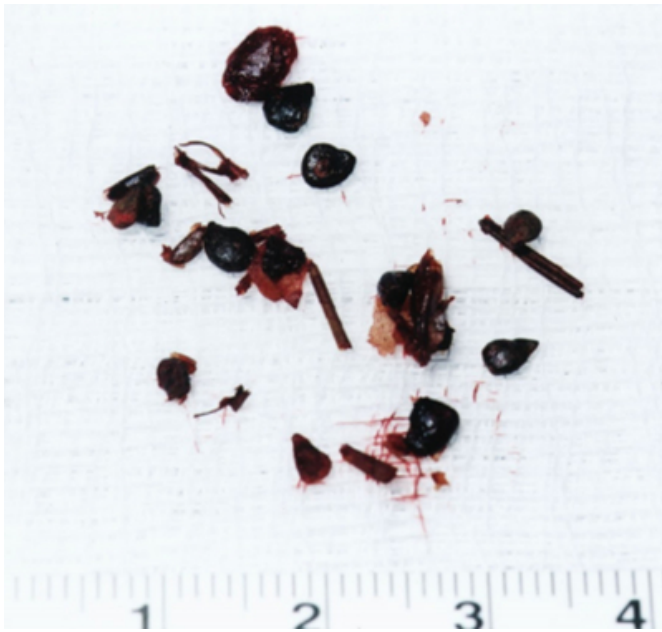
On examination, a small perineal sinus just posterior to the posterior fourchette was seen discharging yellowish brown fluid on pressing. Per rectal and per vaginal examinations were unremarkable. She was planned for an elective examination and exploration under anesthesia and possible excision of sinus.

Examination under anesthesia revealed a sinus tract through the perineal muscle as seen in (Fig. 1). On deroofing the sinus, a 2cm cyst was found in the perineal body which was full of foreign bodies looking like apple seeds and fibres (Fig. 2). There didn't appear to be any deep extensions of the sinus tract. There was no connection to the vagina or the rectum. Histopathology of the material revealed vegetable matter and the cyst wall to consist of hyperplastic stratified squamous epithelium.

Figure 1

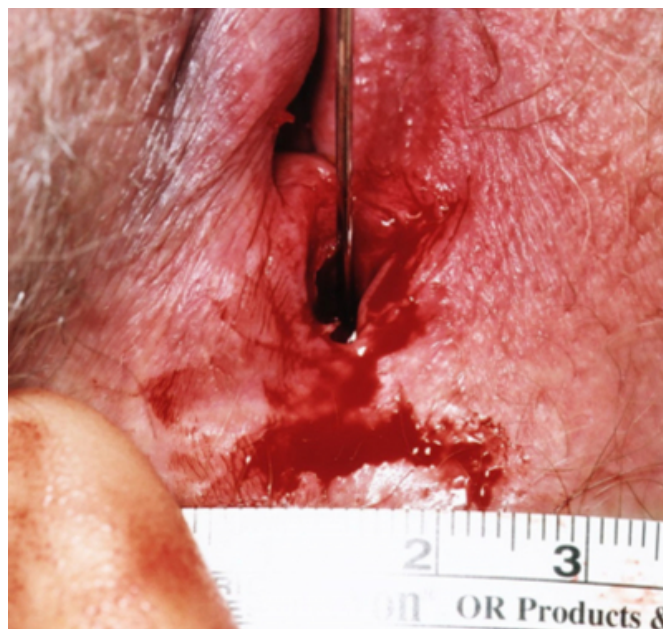

Figure 2



Post operative period was uneventful and she was discharged with a follow-up appointment in 6 weeks. Unfortunately the patient developed an abscess two weeks after the operation for which she was treated with antibiotics. At follow-up, a perineal sinus was seen discharging pus with a 2 cm hard area between this sinus and posterior vaginal wall. The patient was subsequently referred for a surgical opinion. Exploration under anesthesia by surgeons revealed a trans-sphincteric fistula in ano with the internal opening at the dentate line. She was treated with a silastic seton and discharged with a follow-up appointment for anorectal physiology studies and endoanal ultrasound.

DISCUSSION

Perineal sinus is a discharging blind end track that extends from the skin to an underlying area or abscess cavity (1). The commonest cause of abscess formation is the presence of underlying infection. Frequently sinuses are formed due to the presence of foreign body such as hair as in the case of pilonidal sinus. Iatrogenic causes may include retained non

absorbable suture material, cotton wool fibres or gauze. Accurate detection of any associated deep abscess cavity or complex deep extensions of the sinus tract is paramount for successful treatment. Failure to do so will result in recurrence of the sinus either at the same site or an adjacent location (1). Chronic abscesses that have been epithelialised eventually become a fistula-in-ano (2). The external opening is often visualized as a small dimpled area of granulation tissue draining pus or blood on manual compression (2). Trans-sphincteric fistulas pass through the internal and external sphincter into the ischioanal fossa and to the perianal skin. These fistulas usually involve only a small portion of the external sphincter and may be effectively treated with a fistulotomy. If a greater portion (over half) of the external sphincter is involved, a cutting seton may be employed. The seton will allow fibrosis and scarring proximal to the ligature allowing the muscle to hold together while the fistulous tract fibroses (3).

Vegetable material was the cause of non healing sinus in this case. Literature search did not reveal any such cases before. A high index of suspicion for fistula-in-ano is important when dealing with chronic non healing perineal abscesses or sinuses.

COMMUNICATING AUTHOR

Dr Satya Arathi Duvvur 3 Panama Road Burton – on – Trent
Staffordshire DE13 0SQ United Kingdom Tel :
00441283509097 Mobile : 00447812639511 E mail :
arathi_satya@yahoo.co.in

References

1. Bailey and Love's Short practice of surgery: 24th edition: Sinuses 209-210
2. Mantyh C. American society of colon and rectal surgeon (ASCRS). 2004 Core Subjects. Anal fistula / abscess. http://www.fascrs.org/displaycommon.cfm?an=1&subarticle_nbr=237
3. Theerapol A, So BY, Ngoi SS. Routine use of Setons for the treatment of anal fistulae. Singapore Med J. 2002 Jun; 43(6):305-7

Author Information

S. Duvvura

Senior house officer, Department of Obstetrics and Gynecology, Queen's Hospital, Burton Hospitals NHS Trust

R. Singh

Specialist registrar, Department of Obstetrics and Gynecology, Queen's Hospital, Burton Hospitals NHS Trust

K. Anwar

Consultant, Department of Obstetrics and Gynecology, Queen's Hospital, Burton Hospitals NHS Trust