

Missed Instrument and Surgical Sponge (Gauze and Pack)

G Nasir

Citation

G Nasir. *Missed Instrument and Surgical Sponge (Gauze and Pack)*. The Internet Journal of Surgery. 2008 Volume 20 Number 1.

Abstract

Retained surgical instruments or sponges as small gauze and packs are unusual but dangerous complications of abdominal surgery. A missed instrument remains silent and is discovered accidentally because it is sterile and inert while the sponge produces infection and usually presents as local or general peritonitis. Ten cases of missed operative instruments and sponges were recorded during the last 8 years. Presentation and complications of these 10 cases, and how to prevent that in the future, are discussed.

INTRODUCTION

To perform any laparotomy requires, beside the surgical team, a set of surgical instruments of that special laparotomy, a set of swabs, packs and tubes for suction and irrigation and other accessory instruments for cauterization. Missing one of the surgical instruments, swabs or packs during laparotomy is a mistake for the surgical team especially the scrub and circulating nurses. But this has happened especially under the following conditions:

1. Difficult surgery, especially emergency surgery at night
2. Surgery for obese patients
3. Excision of a big abdominal tumor
4. Necessity to arrest massive intra-abdominal bleeding using multiple instruments and packs
5. Bad general condition of the patient during G.A. and need to cut short the operation.
6. Presence of an untrained or newly trained nurse
7. Absence of the circulating nurse.
8. Absence of a swab and instrument counting system
9. Many teams sharing in the surgical operation
10. Improper lighting in the theater with bad surgical theater environment

PATIENTS AND METHODS

During the last 8 years, 10 patients of different age groups, 3 males and 7 females with history of previous laparotomy presented to us with features of acute abdomen and presenting symptoms and signs as in table No. I:

Figure 1

Table 1: Presenting Signs and Symptoms

	No. of pt.	Percent
1. Abdominal pain	10 pt.	100%
2. Fever	9 pt.	90%
3. Vomiting	5 pt.	50%
4. Abdominal tenderness	9 pt.	90%
5. Abdominal mass	6 pt.	60%

Urgent plain X-Ray of the abdomen with U/S examination was done in some of them. The diagnosis was reached before surgery in 3 cases while the others were considered acute abdomen and emergency laparotomy was done for them.

RESULTS

The result of 10 laparotomies was found to be missed instruments, swab gauze and packs. The details are given in table No. II:

Figure 2

Table 2: Three of our cases were diagnosed pre-operatively.

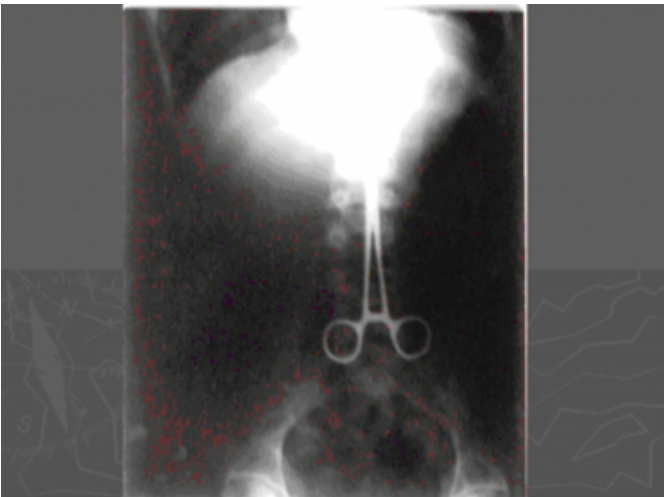Instrument (big artery forceps)	1
Swab gauze	3
Packs	6

CASE NO. 1

A 20-year-old male patient with a history of laparotomy for excision of a big abdominal tumor one year ago, presented to us with colicky abdominal pain and mild fever (37.5°C). On examination his abdomen was soft but there was slight central abdominal tenderness and no mass was palpable. His plain X-Ray of the abdomen (fig. 1) showed a big artery forceps missed from previous surgery. This forceps was taken out by re-laparotomy and the patient was discharged well from hospital after a smooth postoperative period.

Figure 3

Figure 1



CASE NO. 2

A 60-year-old female patient with a history of cholecystectomy abroad 7 month ago, presented to us with right hypochondrial pain, tenderness and a mass, her temperature was 38.5°C. Plain X-Ray of the abdomen (fig. 2) showed a missed pack in the area of the operation. A laparotomy was done with removal of the missed pack and drainage of collected pus in the area. She was discharged well with a mildly septic wound.

Figure 4

Figure 2



CASE NO. 3

A 53-year-old female patient had a history of laparoscopic cholecystectomy that was converted to laparotomy for persistent bleeding in the field, the bleeding was controlled and the laparotomy wound closed. After two weeks, she presented with massive upper GIT bleeding from a duodenal ulcer at its first part. After resuscitation, a tender mass was felt at the right hypochondrial region, and her U/S examination revealed a hypo-echoic mass in the fosse of the removed gallbladder in favor of a missed pack (fig. 3). The pack was removed after re-laparotomy (fig. 4).

Figure 5

Figure 3: Ultrasound features of missed pack

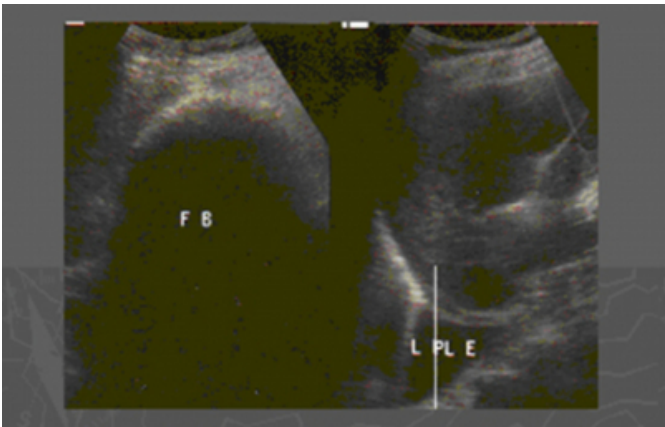
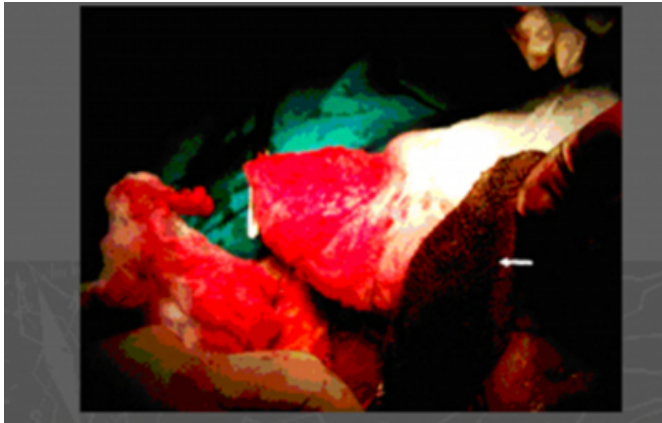


Figure 6

Figure 4: The pack is soaked with altered blood and purulent exudate (arrow)



DISCUSSION

Retained surgical instruments or sponges as small gauze or packs are unusual but dangerous complications of abdominal surgery ¹⁴. Yet this has happened, continues to happen, and will happen because of carelessness.

These surgical sponges (gauze and packs) are easy to be missed, as the gauze and the pack appears obvious before the operation, but it becomes a small ball of red material when it is soaked with blood, can not be seen in the surgical field and is easily missed in one of the abdominal recesses ⁵.

The usual presentation of these missed sponges has the features of acute abdomen. Because they are made up of cotton, they will be disintegrated and lead to infection in the area, appearing as wound infection, discharging sinus, localized intro-abdominal abscess, tender abdominal mass or as generalized peritonitis, as in 6 of our cases, presenting as acute abdomen and generalized peritonitis without diagnosis of the cause. Sometimes, these missed sponges presented as intestinal obstruction due to migration of intro-luminal gauze and packs ⁴⁶.

Missed instruments remain silent usually because they are sterile and inert and may be discovered accidentally if radiography of the abdomen was taken for another reason, or during post-mortal dissection, or in the ashes after a cremation ³.

But sometimes these missed instruments may cause abdominal pain, bowel obstruction, or bowel perforation as one of our cases presented as colicky abdominal pain ²³.

Gawande found the risk factors for retained instruments and sponges after surgery significantly increased

1. in emergency operations
2. with unplanned changes in the procedure
3. with higher body-mass index ¹⁷.

In our case No. 1, the cause was a big abdominal tumor and a lot of instruments and packs were used; case No.3 was due to intra-operative bleeding.

Prevention of missing instruments and sponges in the future:

1. This is the duty of all the surgical team. The surgeon is the first, the assistant doctor is the second, the scrub nurse is the third and the circulating nurse is the fourth person responsible. So all the surgical team must be well trained and keen, and work with precautions.
2. The surgical theater must be well equipped for the operation and all facilities must be adequate such as good lighting, good suction machines, etc.
3. All gauze and packs must be marked by radio-opaque lines, for the employment of X-ray or other technology such as radiofrequency to detect a missed one.
4. A counting system for instruments and packs must be used. When a discrepancy is reported, the surgeon is notified immediately and a thorough search is made for the item. The search shall include: A. the operative field (surgeon); B. the sterile field (scrub nurse) and C. all the waste receptacles and all appropriate areas within the O.T. (circulating nurse).
5. When a discrepancy cannot be reconciled: An X-ray of the operative site shall be taken and reviewed by a radiologist and the operating surgeon before the patient leaves the O.T.
6. No one from the surgical team is changed during operation and if we are obliged to change, a formal handling over is made including full instrument and pack count.
7. Also after closure of any open cavity during laparotomy such as retroperitoneal space, counting of the instruments and packs must be done.
8. The circulating nurse is an important member of

the operating team and must be present.

9. Certain precautions must be taken if more than one surgical team is sharing in the operation.

The American College of surgeons has issued a statement of policy designated to prevent the problem of leaving foreign bodies inside surgical patients₈.

References

1. Gawande AA, et al. Risk factors for retained instruments and sponges. *N Engl J Med* 2003; 348: 229-235
2. Surgical craft and technology. Cuschieri A, Mossa AR.

- Essential Surgical Practice. Butterworth and Heinemann. Oxford, Boston and New Delhi, 4th edition 2000: 27-60
3. Barnouti HN. Missed swabs and instruments. *MJBU* 1992; 10: 1-6
 4. Tikriti FN, Al-Biati AR. Small bowel obstruction caused by intro-luminal migration of missed gauze packs. *J Fac Med Baghdad* 1989, 31: 87-92
 5. Hawkins C. Mishap or malpractice. London; H.K. Lewis 1985: 143-149
 6. Becker WF. Intestinal obstruction - an analysis of 1007 cases. *South Med J* 1955; 48: 41-6
 7. McLeod RS, Bohnen, JM. CAGS evidence-based reviews: Risk factors for retained foreign bodies after surgery. *Canadian Journal of Surgery* 2004; 47: 57-59
 8. Bulletin of the American College of Surgeons, Vol.90, No.10, October 2005.

Author Information

G.A.A. Nasir, FRCS (ED), FICS

Senior Consultant Surgeon, Faculty of Medicine, UiTM