

Nasolabial Cyst: Presentation and Management

Z Zahirrudin, B Gendeh, G Tan, M Marina

Citation

Z Zahirrudin, B Gendeh, G Tan, M Marina. *Nasolabial Cyst: Presentation and Management*. The Internet Journal of Otorhinolaryngology. 2008 Volume 9 Number 2.

Abstract

Objective: To review our experience in managing five cases of nasolabial cyst. **Design:** Retrospective study. **Setting:** Tertiary Center, Malaysia. **Subjects:** Five patients, all female. **Intervention:** Data from patient's diagnosed as nasolabial cyst were reviewed. **Main Outcome measures:** Comparing the clinical presentation, radiology finding, intraoperative finding and treatment outcome. **Results:** The commonest presenting complaint was swelling in nasolabial region. The duration of symptoms ranged from 1 to 5 years. There is no correlation between duration of symptom and size of the nasolabial cyst. Computed Tomography (CT) scan finding in cases with prolonged symptoms (between 1 to 3 years) had shown scalloping of the bone. Evidence of pressure remodelling on CT scan was seen in the case where the symptom was present for 5 years. **Conclusion:** In the majority of cases, one should be able to diagnose nasolabial cyst on clinical assessment. Radiological investigation such as CT scan can help to establish the diagnosis. Duration of the symptoms does not correlate to the size of lesion but can cause thinning and bone remodeling of the bone. Complete surgical excision via sublabial incision is the treatment of choice.

INTRODUCTION

Nasolabial cyst is a non-odontogenic, soft tissue cyst characterized by its extra osseous location in the nasal alar region. It is synonymous with nasoalveolar cyst, nasal vestibule cyst, nasal wing cyst and mucoid cyst of the nose. It also called Klestadt's cyst. The first documentation^[1] of nasolabial cyst was by Zuckerkandl in 1882.

It is more common reported in Eastern population than the West.

In this study, we would like to highlight the clinical presentation and the radiological features of nasolabial cyst in order to assist other healthcare providers in the diagnosis and treatment of this uncommon entity.

PATIENTS AND METHODS

Five patients were diagnosed with nasolabial cyst during the 7-year span between January 1st, 2000, and June 30th, 2007, at Department of Otorhinolaryngology and Head and Neck Surgery, Hospital Universiti Kebangsaan Malaysia. The diagnosis in each case had been established by correlating the clinical, histologic, and in some cases radiologic findings. Information on the clinical picture, duration of symptoms, size and location of the cyst, and treatment option was obtained from a retrospective review of patient's medical record.

RESULTS

Dermographic of the 5 patients presenting with nasolabial cyst were presented in Table 1.

F : Female

Figure 1

Table 1: Dermography of patients with nasolabial cyst

Patient	Age	Sex	Symptom	Duration (years)	Site	Size (cm)
BP	28	F	Swelling in nasal cavity	3	right	2 x 2
CI	41	F	Unilateral nasal blockage	3	left	2 x 2
FH	42	F	nasolabial fold swelling	2	right	1 x 1
RU	50	F	nasolabial fold swelling	5	right	2 x 2
YY	55	F	Swelling in nasal cavity	1	left	3 x 3

AGE, SEX AND RACE

All of the 5 patients were females. Age of the patient range from 28 to 55 years (average 43.2). The racial distribution was three Malays, one Chinese and one others.

SIZE AND SITES

The size of the cysts ranged from 1 x 1 to 3 x 3 cm. The cyst was located on the left in three patients and on the right in

two patients.

SIGNS AND SYMPTOMS

The most common complaint was swelling in the nasolabial region and nasal cavity in 4 patients (80%). One patient presented with progressive unilateral nasal blockage with post nasal drip and rhinorrhoea. She was subsequently noted to have a swelling inferior to left inferior turbinate during follow up.

DURATION OF SYMPTOMS

The interval between the onset of symptoms and the first visit to an otolaryngology clinic ranged from 1 year to 5 years (mean 2.8).

RADIOLOGIC FINDINGS

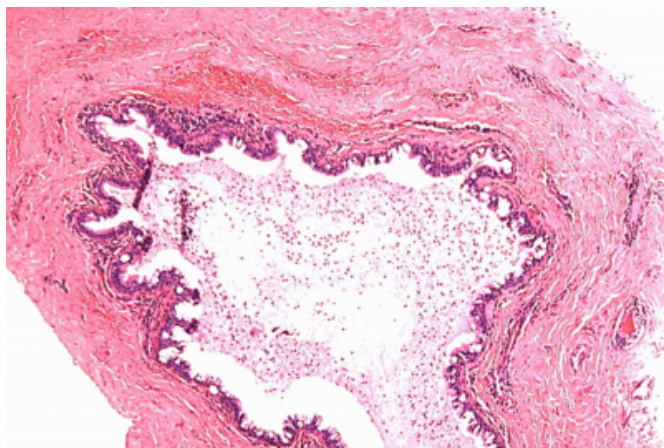
Computed tomography (CT) was performed on 4 patients, and it generally showed a well-demarcated, low-density soft tissue lesion at the nasolabial region. There was evidence of scalloping and bone remodelling.

HISTOPATHOLOGIC FINDINGS

The histopathological report showed evidence of pseudostratified columnar epithelium, mucin secreting columnar epithelium in two patients each, and double layer columnar and cuboidal epithelium in one.(Figure 1).

Figure 2

Figure 1: Fibrocollagenous cyst wall lined by ciliated pseudostratified columnar epithelium (H&E,x40).



TREATMENT AND PROGNOSIS

Surgical excision via the sublabial approach was performed on all patients. No postoperative complications or other recurrences were reported on follow up.

DISCUSSION

Nasolabial cyst is a non-odontogenic, soft tissue cyst

characterized by its extra osseous location in the nasal alar region. It is synonymous with nasoalveolar cyst, nasal vestibule cyst, nasal wing cyst and mucoid cyst of the nose. It also called Klestadt's cyst. The first documentation^[1] of nasolabial cyst was by Zuckerkandl in 1882.

Two theories^[1] have been suggested to explain the origin of nasolabial cyst.

Klestadt in 1913 suggested that they arise from trapped epithelium at the point where the maxillary, medial nasal, and lateral nasal processes fuse which become inclusion cyst. However, a lack of evidence to support the idea of embryonic epithelial entrapment in this location prompted many researchers to discard this hypothesis.

Bruggeman in 1920 had suggested that nasolabial cysts develop from remnants of the embryonic nasolacrimal ducts. This theory is supported by the fact that the nasolacrimal ducts are lined with pseudostratified columnar epithelium, which is the type of epithelium found in the nasolabial cyst cavity.

Although nasolabial cyst is developmental in origin, they rarely present during childhood. Yuen et al^[2] in his series of 18 patient, reported the mean age was 41 (range 31-75) years which was similar to our series (43.2 years).

All the patients in our series were females. This finding is consistent with other series that shows that nasolabial cyst predominantly occur in females.

Nasolabial cyst is usually asymptomatic. The patient presents only when the cyst become infected or when it cause unilateral fullness in the nasolabial region. Retrospectively, patients initially noticed a fullness in the nasolabial region before it becomes symptomatic. Occasionally in late presentation, it can present with nasal obstruction when it pushes on the inferior turbinate causing it to medialize. All of our patient except for one presented with noticeable swelling over nasolabial fold or nasal cavity.

Due to its location, patient can present to an otolaryngologist, dental surgeon or plastic surgeon and this well explains why we have only five referrals in the period of seven years.

On inspection, nasolabial cyst appears to be either normal pink or bluish in color.

The cyst is best palpated bimanually with a finger in the floor of the nose and other in the labial sulcus. The cyst

appears underneath the ala nasi as a painless fluctuant swelling extending laterally into the cheeks, often obliterating the nasolabial sulcus, and extending anteriorly into the lip and mucobuccal vestibule ^[3].

The differential diagnosis should include odontogenic, developmental and neoplastic lesions.

The odontogenic cysts that should be excluded are periapical inflammatory lesions (granuloma, cyst or abscess) that have thinned out the bone. Careful examination of the adjacent teeth and testing its vitality can help to rule out this possibility. Orthopantomogram will show evidence of non vital tooth with radiolucency.

Dentigerous cyst also need to be excluded. Usual radiographic appearance of dentigerous cyst is that of a well-demarcated radiolucent lesion attached at an acute angle to the cervical area of an unerupted tooth.

Radiographic finding of cyst in the nasolabial region that are separated from bony structure and teeth is suggestive of nasolabial cyst.

Another possible cyst of non-odontogenic origin is the epidermoid or epidermal inclusion cyst. As opposed to the normal pink or bluish coloration of a nasolabial cyst, this cyst is yellow hue in colour.

An example of neoplasm that need to be excluded in this area is minor salivary gland tumor. As oppose to nasolabial cyst, minor salivary gland tumors are usually non fluctuant ^[4].

Panoramic radiograph can help to differentiate between nasolabial cyst and odontogenic cyst. Ultrasonography does not offer much other than to confirm its cystic content.

Computed tomography (CT) is able to demonstrate the soft tissue nature of the cyst as well as bony involvement. As the cyst is benign in nature, there is no bony erosion other than expansile lesion causing thinning of the bone.

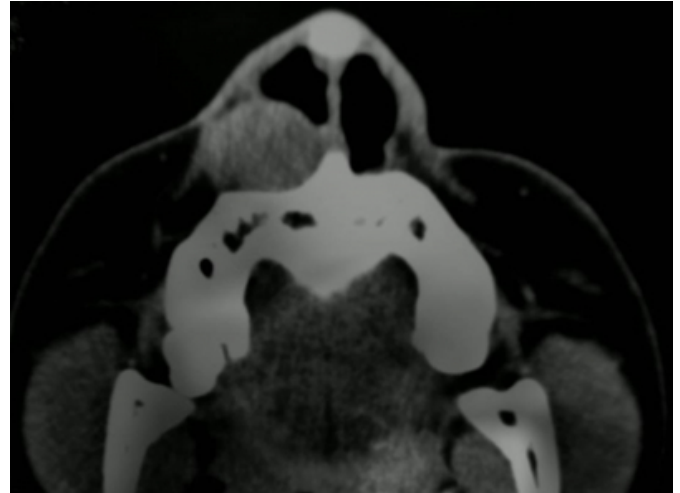
In our series, 4 out of 5 patient had CT scan done prior to surgery. There is no correlation between the duration of symptoms and the size of the nasolabial cyst.

Three cases which had the nasolabial cyst between 1 to 3 years had shown scalloping of the bone with evidence of bony remodeling. However, one patient who presented with 5 years duration of the nasolabial cyst had shown evidence of pressure remodeling erosion of the maxillary bone (Figure

2).

Figure 3

Figure 2: Axial CT shows right nasolabial cyst with evidence of obliteration of right nasolabial fold, nasal cavity and scalloping of right maxillary bone.



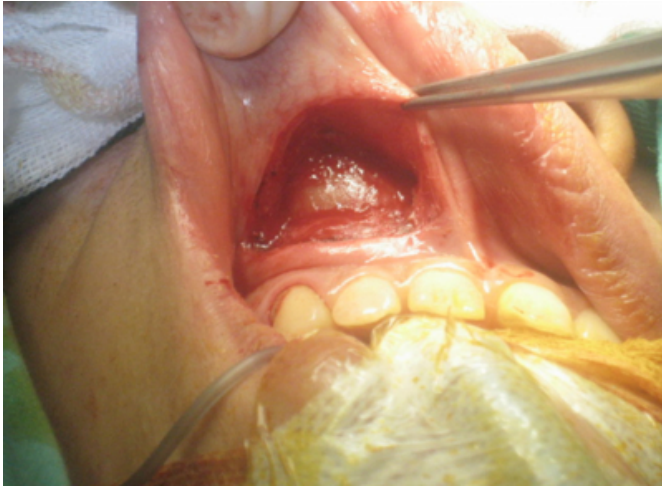There is a reported case using MRI for diagnosing nasolabial cyst to differentiate it from minor salivary gland tumor. In minor salivary gland tumor, MRI will show contrast enhancement of internal lesion compared to non enhancement in nasolabial cyst ^[5].

Clinically, the nasolabial cyst is usually asymptomatic and can present with infection or causing cosmetic deformity. Therefore, the treatment is aimed to prevent infection, to ameliorate a cosmetic deformity, and to establish a histopathological diagnosis.

The current treatment of nasolabial cyst is complete excision. In our series, all cases were completely removed via sublabial incision. Care must be taken not to rupture the cyst, and it should be removed intact (Figure 3).

Figure 4

Figure 3: Intraoperative finding of right nasolabial cyst.



Other mode of treatment that had been described are simple aspiration, injections with a sclerosing agent, destruction by cautery, needle aspiration, and incision and drainage. However, these method are associated with high recurrence rates.

Marsupialisation of cyst had been previously reported to have high recurrence rate. Recent article and literature review by Ramos et al^[6] using transnasal marsupialisation of nasolabial cyst which open into nasal cavity have reported no recurrence of cyst.

CONCLUSION

Nasolabial cyst is a benign condition and the most common complaints was a swelling or fullness in the nasolabial

region and nasal cavity. In the majority of cases, one should be able to diagnose it on clinical assessment. Radiological investigation such as CT scan can help to establish the diagnosis. Duration of the symptoms does not correlate to the size of lesion but can cause thinning and bone remodeling of the bone. Complete surgical excision via sublabial incision is the treatment of choice.

CORRESPONDENCE TO

Dr ZAHIRRUDIN ZAKARIA E-mail :
zahir776@gmail.com Phone : 603-91456045 Fax :
603-91737840 ADDRESS Department of
Otorhinolaryngology-Head and Neck Surgery, Universiti
Kebangsaan Malaysia Medical Centre, Jalan Yaacob Latif,
56000, Kuala Lumpur, Malaysia.

References

1. Patil K, Mahima VG, Divya A. Kelstadt's cyst: A rarity. *Indian Journal Dental Research* 2007;18 : 23-6.
2. Yuen HW, Julian LCW, Samuel CLY. Nasolabial cysts: Clinical features, diagnosis, and treatment. *British Journal of Oral and Maxillofacial Surgery* 2007; 45 : 293-7.
3. Choi JH, Cho JH, Kang HJ et al. Nasolabial cyst: a retrospective analysis of 18 cases. *Ear, Nose & Throat Journal*, Feb. 2002; 81(2):94-6.
4. Nixdorf DR, Peters E, Lung KE. Clinical Presentation and Differential Diagnosis of Nasolabial Cyst. *J Can Dent Assoc* 2003; 69(3):146-9.
5. Tanimoto K, Kakimoto N, Nishiyama H, Murakami S, Kishino M. MRI of nasoalveolar cyst: Case report. *Oral Surg Oral Med Oral Pathol Oral Radiol Endod* 2005; 99 : 221-4.
6. Ramos TCV, Mesquita RA, Gomez RS, Henriques W. Transnasal Approach to Marsupialization of the Nasolabial Cyst: Report of 2 Cases. *J Oral Maxillofac Surg* 2007; 65 : 1241-3.

Author Information

Z. Zahirrudin, MD

Department of Otorhinolaryngology-Head and Neck Surgery, Universiti Kebangsaan Malaysia Medical Centre

B.S. Gendeh, MS ORL-HNS

Department of Otorhinolaryngology-Head and Neck Surgery, Universiti Kebangsaan Malaysia Medical Centre

G.C. Tan, MPath

Department of Otorhinolaryngology-Head and Neck Surgery, Universiti Kebangsaan Malaysia Medical Centre

M.B. Marina, MS ORL-HNS

Department of Otorhinolaryngology-Head and Neck Surgery, Universiti Kebangsaan Malaysia Medical Centre