

Alteration Of The Axis Of Injury From Alkali Ingestion By Prior Vagotomy And Pyloroplasty

V Avidan, O Olsha, D Gimelreich, J Alberton, P Reissman

Citation

V Avidan, O Olsha, D Gimelreich, J Alberton, P Reissman. *Alteration Of The Axis Of Injury From Alkali Ingestion By Prior Vagotomy And Pyloroplasty*. The Internet Journal of Surgery. 2006 Volume 10 Number 1.

Abstract

Damage from caustic ingestion is usually confined to the esophagus, stomach and, in more serious cases, adjacent organs. A unique case is described of far more extensive contiguous injury to the gastrointestinal tract in a patient after ulcer surgery. Mechanisms of alkali injury in the patient with vagotomy and pyloroplasty and possible explanations for the extensive small intestinal injury in this setting are discussed. The surgical procedure may be simpler if damage is confined to the axis of the intestine.

INTRODUCTION

In self-inflicted injuries due to alkali ingestion, whether accidental or intentional, the damage is usually confined to the esophagus and stomach as a result of pylorospasm. It also, rarely, causes irregular damage to adjacent organs if damage by liquefaction necrosis is severe and if there is time for passage of the alkali through the esophageal or gastric wall. We describe a case of alkali ingestion with alteration of the axis of injury resulting in extensive, contiguous small intestinal necrosis in a patient who previously underwent vagotomy and pyloroplasty.

CASE STUDY

A 57-year-old male presented to the emergency department several hours after attempting suicide by ingestion of an estimated 200-400 ml of liquid drain cleaner (pH 8.8). He had had a vagotomy and pyloroplasty for a perforated peptic ulcer a year and a half earlier. The medical history was otherwise unremarkable and he was on no regular medication. On admission the patient was alert and complaining of severe abdominal pain. No dysphonia or stridor was noted. There were burns on the lips, tongue and oral mucosa. The lungs and heart were normal to auscultation. The abdomen had a midline scar and was soft with epigastric tenderness but no rebound. Laboratory tests revealed mild respiratory alkalosis, elevated liver enzymes and hyperbilirubinemia. Amylase level and blood count were normal.

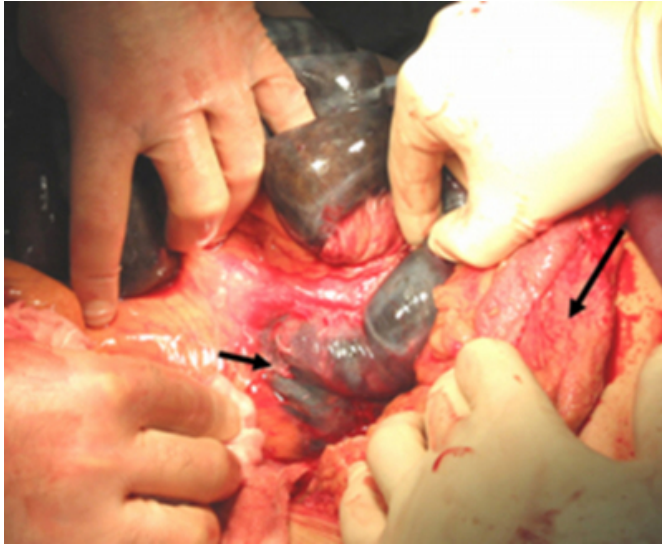
Resuscitation was commenced with intravenous fluids,

oxygen was administered by mask, intravenous ampicillin and gentamycin were given, and the bladder was catheterized. The patient was intubated after fiberoptic laryngoscopy demonstrated edema of the epiglottis and false cords. Esophagogastroscope demonstrated second degree burns along the entire length of the esophagus with ulceration and the entire visible gastric mucosa was edematous with exudates but no obvious necrosis. Computerized tomography of the chest and abdomen with oral and intravenous contrast demonstrated thickened gastric and duodenal walls, dilated small bowel loops and pneumoperitoneum.

Laparotomy revealed diffuse peritonitis, patchy necrosis of the stomach and duodenum with a small perforation of the posterior gastric wall, and extensive contiguous necrosis of the duodenum, jejunum and proximal ileum with edema of the adjacent transverse colon serosa and omentum [figure 1].

Figure 1

Figure 1: Effects of alkali ingestion after vagotomy and pyloroplasty showing loops of jejunum with contiguous necrosis (short arrow - duodenojejunal ligament of Treitz with patchy necrosis; long arrow - edematous omentum).



The distal esophagus and a small segment of the proximal stomach were deemed completely viable. The patient underwent subtotal gastrectomy, duodenectomy without pancreatectomy, resection of necrotic jejunum and proximal ileum, cholecystectomy with insertion of a T-tube to the common bile duct stump, oversewing of the common opening of the common bile duct and pancreatic ducts at the level of the papilla of Vater, insertion of a large Pezzer catheter to the proximal gastric remnant as a tube esophagostomy and exteriorization of the ileal stump as a mucous fistula. The remaining distal ileum was 140 cm long. The transverse colon burn did not require intervention. After abdominal closure a cervical esophagostomy and tracheostomy were performed.

The post-operative course was complicated by sepsis and the development of a pancreaticocutaneous fistula through an abdominal drain. On the 35th post-operative day, the patient was weaned off the ventilator and fed through the ileostomy. Contrast films of the esophagus with barium demonstrated a widely patent esophagus with normal mucosa.

Unfortunately, a few days later the T-tube was dislodged, pouring contaminated bile into the peritoneal cavity, causing another bout of severe peritonitis and sepsis which did not improve despite percutaneous biliary drainage. A salvage laparotomy was carried out but the patient died of sepsis on the 86th post-operative day.

DISCUSSION

In caustic ingestion, factors related to the caustic agent, the victim, and the duration of exposure influence the extent and severity of the injury. Attributes of the caustic agent include the concentration, volume, strength (expressed as pKa), pH, buffering capacity, physical form (solid versus liquid, liquids being worse) and viscosity. Factors in the victim include pre-existing gastrointestinal content (food, secretions) and pre-morbid condition of the intestinal tract (_{1, 2}). Time is of the essence in caring for caustic injury patients. Early surgical resection of all injured organs is crucial not only for survival, but also to prevent further extension of damage. In alkali ingestion, tissue damage will progress until the alkali is completely neutralized (₂). This is in contrast to mesenteric ischemia in which the damage is limited by the extent of the ischemia, which allows leaving segments of doubtful viability intact for later review in a “second look” operation.

Ingestion of corrosive liquids is associated with different pathological forms of injury, affecting the extent of the damage. The injury can progress along what we classify as two possible “axes”: the “longitudinal axis” along the length of the intestine (esophagus, stomach, duodenum, small intestine, etc.); and the “horizontal axis” across the intestinal wall, to adjacent organs.

Ingestion of acid is painful, so the amount ingested is usually smaller. Acids cause coagulation necrosis. The resulting eschar limits the progression of damage in the horizontal axis(₃). Spasm of the pylorus, which occurs when the acid reaches the stomach, limits the damage in the longitudinal axis. In contrast, liquid alkali is tasteless, odorless and painless when ingested, allowing ingestion of large amounts(₄) that cause severe, extensive injuries. Alkalis cause liquefaction necrosis, saponification of fat and thrombosis. The dissolved tissues allow continued progression of the damage in the horizontal axis to neighboring structures. As in acid ingestion, pyloric spasm limits the damage in the longitudinal axis.

Spasm of the pylorus, stomach and cricopharyngeal muscles causes back and forth movement of the alkaline liquid between the esophagus and stomach, aggravating the damage to these organs (_{4, 5}). Pylorospasm is therefore protective for the small bowel but injurious to the esophagus and stomach. Most victims of alkali ingestion suffer injuries limited to the esophagus and stomach and reports of alkaline injury distal to the stomach are rare. Extensive gastrointestinal and abdominal injury in the horizontal axis

including the colon, spleen, gallbladder and liver after alkali ingestion has been described in 9 cases (^{6,7,8,9}). Damage to organs in anatomical proximity rather than in continuity in the long axis can be explained by transmural spread of the alkali through perforations and foci of full thickness necrosis. The prognosis of extensive abdominal alkaline injury in the "horizontal axis" is unknown because of the rarity of such injuries, but from the published case reports, an estimate of 50% mortality can be made (^{6,7,8,9}).

In our patient, the organs damaged were in continuity in the long axis of the intestinal tract, including the esophagus, stomach, duodenum, jejunum and the proximal ileum, which does not match the pattern of direct horizontal spread to adjacent organs as suggested above. Only the superficial burn of the transverse colon and omentum can be explained by transmural spread of alkali from the full thickness necrosis of the small intestine and perforation of the stomach. The extensive small intestinal injury appears to have resulted from rapid, unhindered passage of the alkaline liquid distally through the intestinal tract owing to the prior vagotomy and pyloroplasty. Although it slows the passage of solid food, vagotomy speeds the transit time of liquids, as does pyloroplasty(¹⁰). Pyloroplasty obliterated the pylorospasm reflex, allowing alkali to run down and injure the small intestine, while limiting the extent of esophageal and gastric damage. The lack of gastric acid, a potential neutralizer of some of the ingested alkali, may have had a minor role in causing the extensive injury seen in our patient(¹¹), although the total alkalinity of even small amounts of strong alkalis usually overwhelms the neutralizing capacity of gastric acid(⁴).

Surgery for peptic ulcer with vagotomy and pyloroplasty seems to alter the normal axis of injury from alkali ingestion, primarily causing extensive and contiguous small intestinal injury rather than mainly damaging the esophagus, stomach and adjacent organs. For patients with alkali injury who have had ulcer surgery in the past, the possible confounding

effects of the prior surgery should be considered in their assessment because damage control surgery confined to the longitudinal axis may be simpler than in the horizontal axis injuries that normally occur.

CORRESPONDENCE TO

Dr. O. Olsha, Shaare Zedek Medical Center, PO Box 3235, Jerusalem 91031, Israel. E-mail: olsha@szmc.org.il, Telephone: +972 2 6666310, Fax: +972 2 6666253.

References

1. Gumaste V, Dave P. Ingestion of corrosive substances by adults. *Am J Gastroenterol* 1992;87:1-5.
2. Sivilotti M, Ford M. Alkali Ingestions. In: Ford M, Delaney K, Ling L, Erickson T, eds. *Clinical Toxicology*. 1st ed. Philadelphia, PA: WB Saunders Company, 2001:1002-7.
3. Schneider S, Wax P. Caustics. In: Marx J, Hockberger R, Walls R, eds. *Rosen's Emergency Medicine: Concepts and Clinical Practice*. 5th ed. St. Louis, MO: Mosby, 2002:2115-9.
4. Loeb P, Nunez M. Caustic Injury to the Upper Gastrointestinal Tract. In: Feldman M, Friedman L, Sleisenger M, eds. *Sleisenger & Fordtran's Gastrointestinal and Liver Disease*. 7th ed. Philadelphia, PA: Saunders, 2002:399-405.
5. Zwischenberger J, Alpard S, Orringer M. Esophagus. In: Jr. Townsend C, Beauchamp R, Evers B, Mattox K, eds. *Sabiston Textbook of Surgery: The Biological Basis of Modern Surgical Practice*. 16th ed. Philadelphia, PA: WB Saunders Company, 2001:709-53.
6. Guth A, Pachter H, Albanese C, Kim U. Combined duodenal and colonic necrosis - an unusual sequela of caustic ingestion. *J Clin Gastroenterol* 1994;19:303-5.
7. Losanoff J, Kjossev K. Multivisceral injury after liquid caustic ingestion. *Surgery* 1996;119:720.
8. Cattan P, Munoz-Bongrand N, Berney T, Halimi B, Sarfati E, Celerier M. Extensive abdominal surgery after caustic ingestion. *Ann Surg* 2000;231:519-23.
9. Wu M, Lai W. Surgical management of extensive corrosive injuries of the alimentary tract. *Surg Gynecol Obstet* 1993;177:12-6.
10. Ashley S, Evoy D, Daly J. Stomach. In: Schwartz S, Shires G, Spencer F, Daly J, Galloway A, Fischer J, eds. *Principles of Surgery*. 7th ed. New York, NY: McGraw-Hill, 1999:1181-215.
11. Homan C, Maitra S, Lane B, Thode HJ, Finkelshteyn J, Davidson L. Effective treatment for acute alkali injury to the esophagus using weak acid neutralization therapy: an ex-vivo study. *Acad Emerg Med* 1995;2:952-8.

Author Information

Vered Avidan, M.D.

Department of Surgery, Shaare Zedek Medical Center (affiliated with the Faculty of Health Sciences, Ben Gurion University of the Negev)

Oded Olsha, MBBS

Department of Surgery, Shaare Zedek Medical Center (affiliated with the Faculty of Health Sciences, Ben Gurion University of the Negev)

Dimitry Gimelreich, MD

Department of Surgery, Shaare Zedek Medical Center (affiliated with the Faculty of Health Sciences, Ben Gurion University of the Negev)

Joseph Alberton, MD

Department of Surgery, Shaare Zedek Medical Center (affiliated with the Faculty of Health Sciences, Ben Gurion University of the Negev)

Petachia Reissman, MD

Department of Surgery, Shaare Zedek Medical Center (affiliated with the Faculty of Health Sciences, Ben Gurion University of the Negev)