

Giant hibernoma of the neck: A case report

C Amine, B Amine, H Amal, O abdelatif, E Nouredine

Citation

C Amine, B Amine, H Amal, O abdelatif, E Nouredine. *Giant hibernoma of the neck: A case report*. The Internet Journal of Tropical Medicine. 2009 Volume 6 Number 2.

Abstract

Hibernoma is a rare benign tumour arising from remnants of fetal brown adipose tissue. We reported a rare case of hibernoma located in the neck. We also discuss the radiographic findings, pathologic features, and management of hibernomas.

INTRODUCTION

The hibernoma is an uncommon, benign soft tissue tumor arising from vestigial remnants of so-called brown fat. It most commonly occurs in the interscapular regions, but there are also a number of cases originating in sites normally devoid of brown fat. A hibernoma in the head and neck region is very rare, and few cases in this location have been reported. We present the clinical, radiographic, and pathologic features of giant hibernoma that was located in the neck.

CASE REPORT

A 44-year-old man was referred to our institution for evaluation of an enlarging soft-tissue mass on his neck. The patient had noticed the mass 16 months earlier, and it had gradually increased in size (Figure 1). On physical examination, a 26 x 16-cm mass from the posterior region of the neck back of the neck and coming into contact with the upper back. The mass was firm, rubbery, and slightly tender to palpation. No overlying warmth or erythema was noted, and no lymphadenopathy was found. The patient had no neurological deficit. CT scan demonstrated a well defined large mass in the back of the neck (Figure 2). The mass did not invade the surrounding structures. Open biopsy was undertaken, and pathology findings were consistent with a hibernoma. Surgical resection was performed under general anesthesia, yielding a 26 x 16 x 12, 5-cm, rubbery, encapsulated mass (Figure 3). It was excised from the surrounding tissue without difficulty. Histology confirmed tumor characteristics consistent with a hibernoma, showing large multivacuolated cells, scant cytoplasm, and central nuclei (Figure 4). The postoperative course was unremarkable and the patient remains free of disease 2 years after the diagnosis.

Figure 1

Fig1: Profil view of the large hybernoma of the posterior neck.

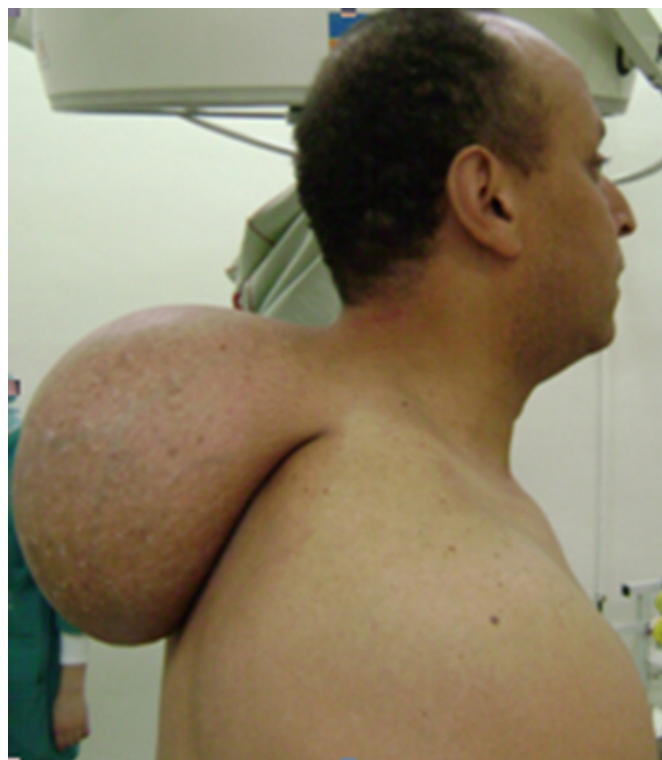

Figure 2

Fig.2: Sagittal scanview of the hibernoma.

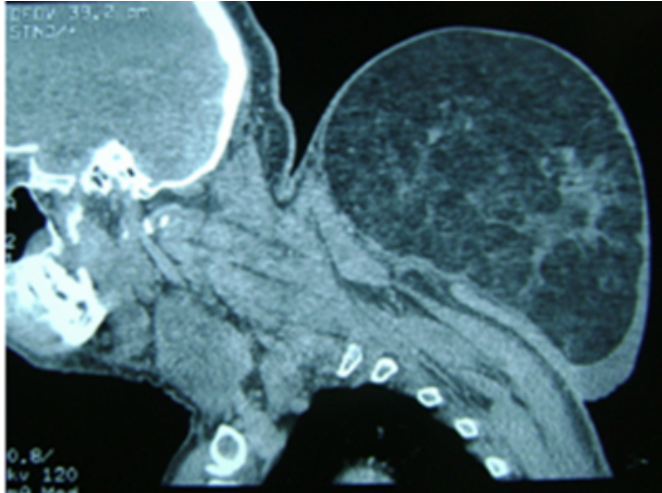


Figure 3

Fig.3: Macroscopic view of the specimen.

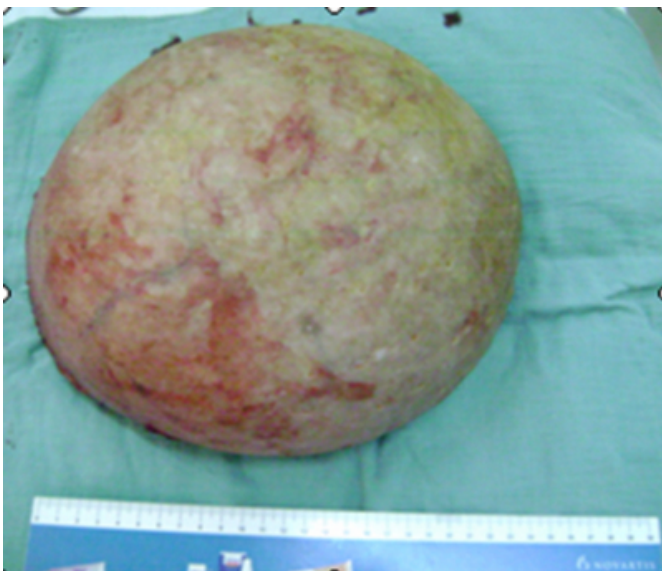
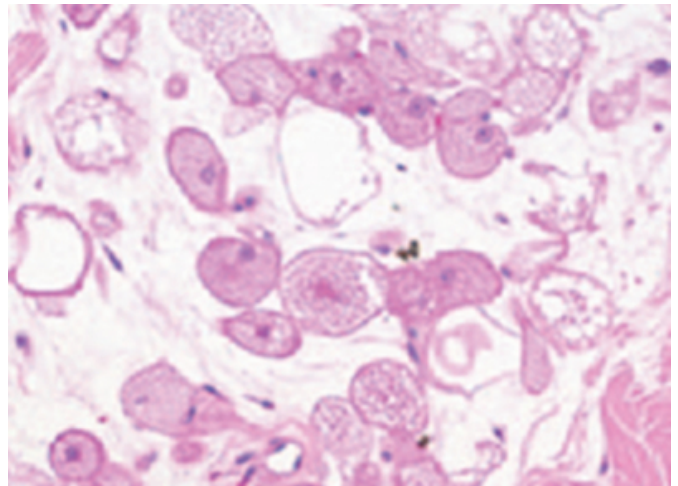


Figure 4

Fig.4: Histology showing finely vacuolated cytoplasm and small, dark, centrally placed nuclei.



DISCUSSION

Hibernoma is an unusual subcutaneous or intramuscular lipomatous tumor, whose cells show differentiation toward brown fat (1,2).

This entity was first recognized in 1906 by Merkel (3). However, Gery was the first to coin the term hibernoma, in 1914 (4) because of its resemblance to the brown fat in hibernating animals.

It usually affects adults, with a slight male predominance and a peak of incidence between the 3rd and 5th decades (5).

These tumors usually arise from areas in which vestiges of brown fetal fat persist beyond fetal life, such axilla, back, and mediastinum and rarely the other sites such the neck (6).

Hibernoma grow slowly and usually present with painless enlargement. Symptoms related to the compression of adjacent structures rarely develop (7).

Hibernomas are typically fatty, hypervascular lesions that are grossly similar to lipomas. They are well-defined, encapsulated, and mobile masses. Their color varies from tan to red brown, depending on the amount of intracellular lipid. The diameter usually ranges from 5 to 10 cm, but they may reach up to 20 cm like our case (7).

On computed tomography scanning, hibernomas are heterogeneously hypodense because of their lipid and fibrovascular content. On MRI, they appear bright on T1-weighted images and have moderate signal intensity on T2-weighted images. Their high vascular content on MRI commonly results in the diagnosis of liposarcoma (8).

Diagnosis can be made by fine needle biopsy, which allows a positive diagnosis, with a minimal surgical excision, preserving vital structures.

Upon microscopic examination, the tumors are characterized by cells of various degrees of differentiation. Multivacuolar adipocytes and brown fat cells with granular eosinophilic cytoplasm are interspersed with univacuolar adipocytes. Hypervascularity combined with abundant mitochondria give hibernomas their color. (9)

The treatment of hibernomas consists of complete surgical resection and local recurrence does not occur. There are no reports of metastases or malignant transformation.

CONCLUSION

Hibernomas are rare benign lipomatous tumors that can become large masses over time and compress surrounding structures. It's rarely occurring in the neck. Their clinical and radiologic appearance is commonly mistaken for malignant liposarcomas. A tissue diagnosis is essential to ensure appropriate treatment, which is complete excision of

the hibernoma.

References

1. Fletcher, C.D.M. Soft tissue tumors. In: Fletcher, C.D.M. Diagnostic histopathology of tumors, 2nd edition, Hong Kong: Churchill Livingstone, 2000, 2: 1473-540.
2. Furlong, M.A.; Fanburg-Smith, J.C. & Miettinen, M. The morphologic spectrum of hibernoma: a clinicopathologic study of 170 cases. *Am. J. Surg. Pathol.*, 25, 6: 809-14, 2001.
3. Merkel H. On a pseudolipoma of the breast. *Beitr Pathol Anat.* 1906;39: 152-157.
4. Gery L. In discussion of MF Bonnel's paper. *Bull Mem Soc Anat (Paris)* 1914; 89:111-12
5. Carinci F, Carls FP, Pelucchi S, et al. Hibernoma of the neck. *J Craniofac Surg* 2001;12: 284-86.
6. . Rigor VU, Goldstone SE, Jones J, et al. Hibernoma. A case report and discussion of a rare tumor. *Cancer* 1986;57: 2207-11
7. Murphey MD, Carroll JF, Flemming DJ, et al. From the archives of the AFIP: benign musculoskeletal lipomatous lesions. *Radiographics* 2004;24:1433-66.
8. Santambrogio L, Cioffi U, De Simone M, et al. Cervicomediastinal hibernoma. *Ann Thorac Surg.* 1997;64(4):1160-1162.
9. Ritchie DA, Aniq H, Davies AM, et al. Hibernoma — correlation of histopathology and magnetic-resonance-imaging features in 10 cases. *Skeletal Radiol* 2006;35: 579-89.

Author Information

Cherkaoui Amine

Senior resident, Department of Otolaryngology-Head and Neck Surgery, University Hospital

Benlemlih Amine

Resident, Department of Otolaryngology-Head and Neck Surgery, University Hospital

Hajjij Amal

Resident, Department of Otolaryngology-Head and Neck Surgery, University Hospital

Oudidi abdelatif

Professor, Department of Otolaryngology-Head and Neck Surgery, University Hospital

El alami Nouredine

Professor Chief of otorhinolaryngology department., Department of Otolaryngology-Head and Neck Surgery, University Hospital