

# Anesthetic Management of Huge Goiter with Retrosternal Extension

A Thallage, T Al-Zahrani

## Citation

A Thallage, T Al-Zahrani. *Anesthetic Management of Huge Goiter with Retrosternal Extension*. The Internet Journal of Anesthesiology. 2004 Volume 10 Number 1.

## Abstract

Goiter is a known risk factor for difficult airway management. We report the anesthetic management of a case with a huge multinodular goiter which compromised the airway with retro-sternal extension and tracheal compression.

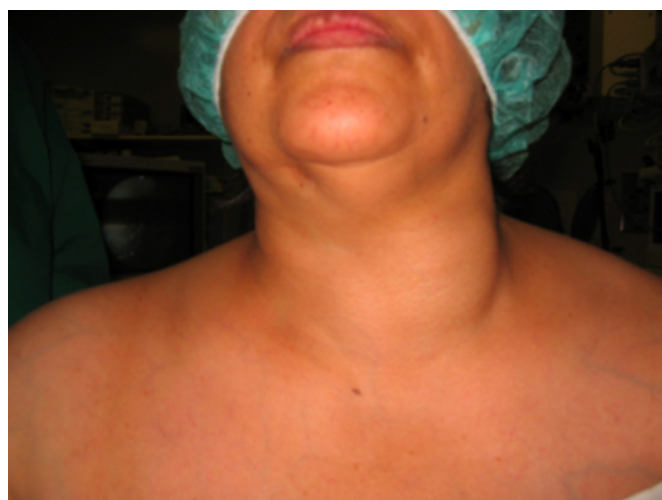## CASE REPORT

A 44-year-old female patient with a known case of sarcoidosis, bronchial asthma, osteoporosis and secondary infertility, presented with history of diffuse neck swelling noted for the first time 10 years ago. The swelling was increasing gradually in size and was associated with dyspnea especially when lying supine, slightly change of voice and dysphagia. There was no suggestive history of hyper or hypothyroidism. She had history of many dilatation and curettage 11yr ago without any complication. She also had a history of asthma.

On examination, she looked well, not in distress or sweating. Her body weight 91.5 Kg, heart rate 65 beats/min and blood pressure 130/85mmHg. Neck examination showed a huge swelling mainly on the left side 8x4cm large, right side about 6x3cm, moving with swallowing, firm in consistency, nodular surface, not tender with normal overlying skin (Figure 1). A plain neck x-ray showed huge mass involving the paratracheal and paravertebral areas (Figure 2). Percussion note was dull over the upper sternum with no systolic bruit over the lump. Trachea was displaced to the right side. No neck veins engorgement or cervical lymphadenopathy.

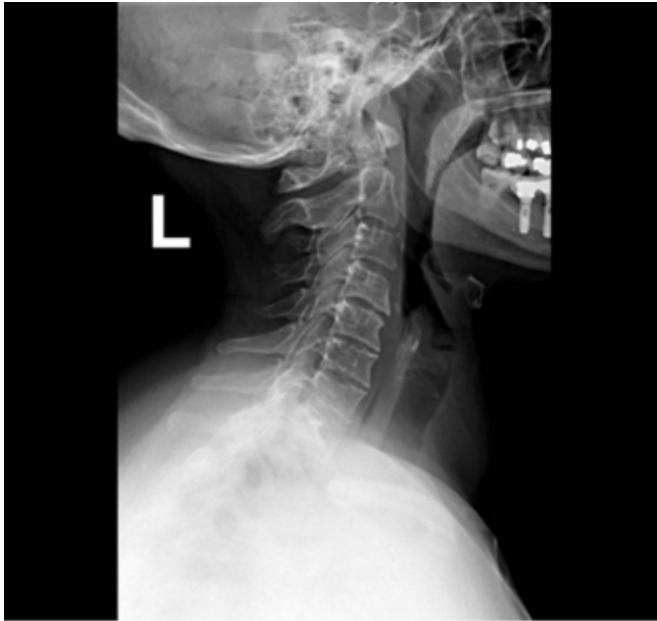
## Figure 1

Figure 1: Huge goiter



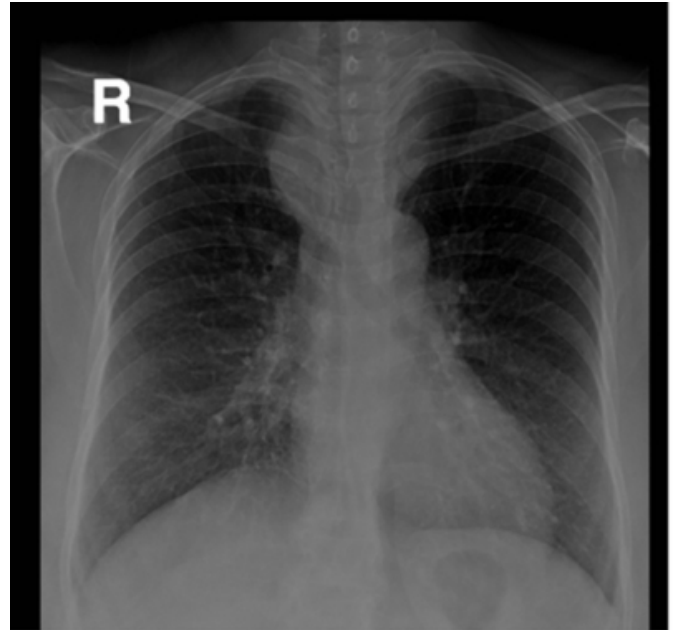
**Figure 2**

Figure 2: lateral neck x-ray shows goiter extension to paratracheal & paravertebral areas



**Figure 3**

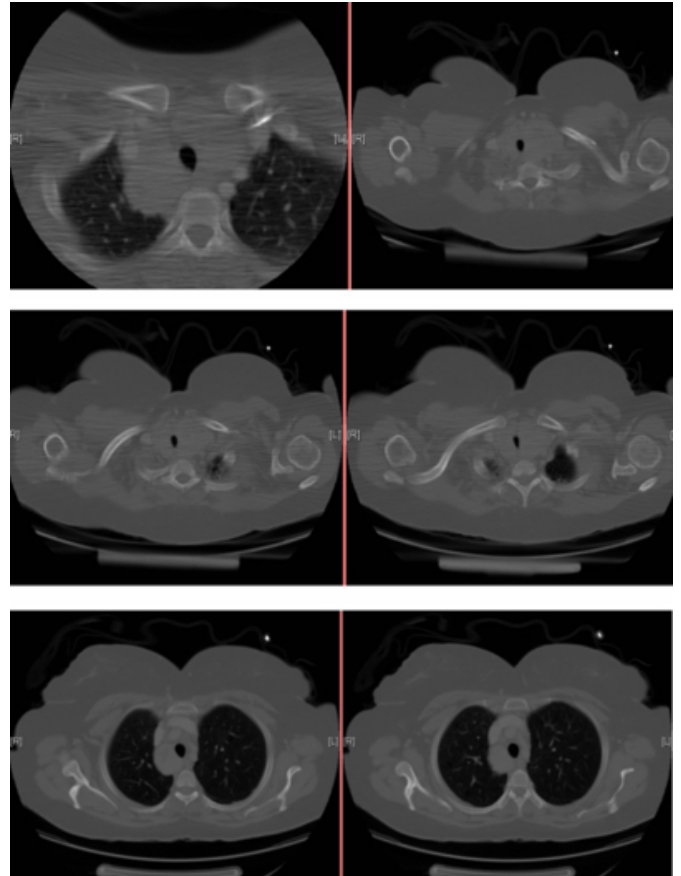
Figure 3: Chest x-ray shows huge goiter with right sided tracheal deviation.



Cardiovascular system examination revealed no added sounds or murmurs. Chest examination showed bilateral good air entry with bilateral mild expiratory wheezing and mild bilateral basal crepitation. Chest x-ray showed huge goiter with compressed and shifted trachea to the right side (Figure 3). Abdominal examination showed soft and lax abdomen with audible bowel sounds. Laboratory investigations including thyroid function tests were within normal ranges. An ultrasound was done which was suggestive of multinodular goiter with retrosternal extension. CT scan showed the thyroid gland significantly enlarged, the left lobe is enlarged measuring approx. 5.4 x 5.2 cm at the level of thoracic inlet, and it extends inferiorly almost to the level of aortic arch, the right lobe is also enlarged with intrathoracic extension (middle mediastinum) measuring approx. 4 x 3.6 cm at the level of confluence of brachiocephalic veins. Scattered areas of ground glass opacity seen in the right lung and lingual (Fig 4). There was no tracheal erosion or infiltration. Fine needle biopsy showed multinodular goiter. Indirect laryngoscopy showed normal structure and function of vocal cords. The patient was scheduled to undergo total thyroidectomy under general anaesthesia. Airway assessment revealed Mallampai IV with limited neck movement. The plan was to perform awake fiberoptic bronchoscope (FOB) to facilitate endotracheal intubation.

**Figure 4**

Figure 4: CT scan shows significant diffuse narrowing of thoracic trachea.

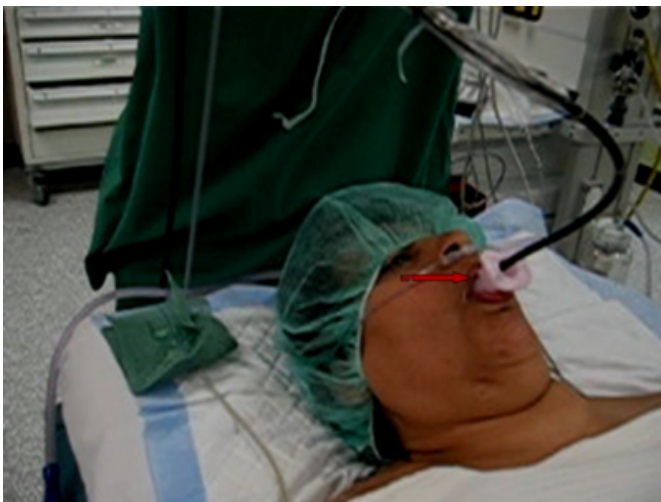

Premedication was achieved with ventoline neublizer 3 mg in 3ml normal saline, oral metoclopramide 10 mg and oral diazepam 5 mg 2 hr prior to surgery. In the operation theater, glycopyrrolate 0.2 mg i.v given, the patient was connected to routine monitoring and nasal O2 cannula (3L/min) flow established. An i.v line was established and 50µg fentanyl was given.

The pharyngeal structures were anesthetized by 5% lignocaine ointment; bilateral superior laryngeal nerves were blocked by 2 ml of 2% lignocaine for each one. The trachea could not be palpated; therefore transtracheal injection of lignocaine was impossible. Awake FOB via Williams airway was successful and the trachea was intubated with size 7.0mm reinforced armored tube size (Fig 5), followed by propofol 200 mg and 100 mcg fentanyl i.v. Increment doses of cis-atracurium were given when needed. Total thyroidectomy was uneventful, left lobe resected measuring approx. 9 x 5 cm and right lobe measuring approx 9 x 3.5 cm (Fig 6), upon completion of surgery i.v atropine/neostigmine were given i.v, then the trachea was extubated.

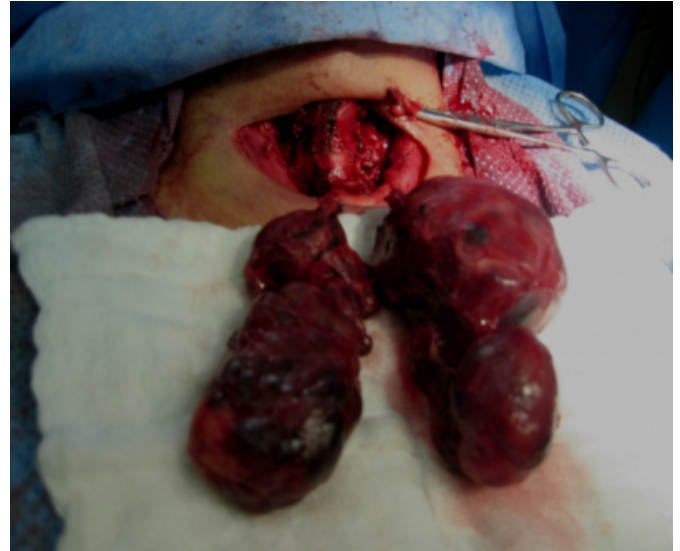**Figure 5**

Figure 5: William's airway



**Figure 6**

Figure 6: Bilobectomy resection



## DISCUSSION

Large thyroid masses with retrosternal extension present several potential difficulties for anesthetists. One of these is distortion of airway anatomy, which may precipitate complete airway obstruction during induction of general anesthesia. Upper airway obstruction is considered rare in patients with goiter and indicated by symptoms such as positional dyspnea and dysphagia (<sup>1</sup>). In order to avoid airway problems during induction of general anesthesia, the anesthetist should carefully perform preoperative evaluation and have a plan for airway management in advance.

CT scan of the airway is mandatory, since the diameter of the trachea and the site of obstruction can be measured accurately (<sup>2,3</sup>). Moreover, CT scan findings such as extension of the goiter to the level of the aortic arch or major vessel displacement can predict the need for median sternotomy (<sup>4</sup>).

Other dynamic airway function studies like maximal inspiratory and expiratory flow volume loops obtained with the patient upright and supine can quantitate the functional degree of impairment (<sup>5</sup>).

Planning for awake fiberoptic intubation as an early option for patient with retrosternal goiter represents safe and logical technique. In the present report, awake fiberoptic bronchoscopy was successful to accomplish endotracheal intubation.

As in our case, which is desirable to perform fiberoptic bronchoscopy via oral route, specific airways have been

devised to push the tongue interiorly to clear a passage for the fiberscope into the trachea. Of these airways, the most widely known are the Williams and Ovassapian airways. However, in a recent study William's airway appeared superior to the other airways in directing the fiberscope towards the glottis (6).

### **CONCLUSION**

In conclusion, awake fiberoptic intubation through William's airway represents a logical and practical technique in patients with retrosternal goiter.

### **References**

1. NJL Gittoes, MR Miller, upper airway obstruction in 153 consecutive patients presenting with thyroid enlargement. *BMJ* 1996;13: 312:484.
2. The use of computed tomography in the evaluation of large multinodular goiter. *Ann R Coll Surg Engl* 1991;11:73:32-5.
3. C.F.Melissant,S.J. Smith, Lung function ,CT-scan and X-ray in upper airway obstruction due to thyroid goiter. *Eur Respir J* 1994,7:1782-1787.
4. Joe Grainger, The surgical approach to retrosternal goiters: The role of computerized tomography. *Otolaryngology-Head and Neck surgery* 2005,10:849-851.
5. Marc Meysman, Marc Noppen, Effect of posture on the flow-volume loop in two patients with euthyroid goiter. *CHEST* 1996;110:1615-18.
6. Keith B. Greenland , Michael G. Irwin, The Williams airway intubator, the ovassapian airway and the Berman airway as upper airway conduits for fiberoptic bronchoscopy in patients with difficult airway. *Curr opin Anesthesiol* 2004,17:505-510

**Author Information**

**Ahmed Thallage**

Consultant, Department of Anesthesia, College of Medicine, King Saud University

**Tariq Al-Zahrani**

Demonstrator, Department of Anesthesia, College of Medicine, King Saud University