

Anaesthetic Management Of A Patient With Right Atrial Myxoma – A Case Report And Anaesthetic Considerations

R S, H Balachander, A Badhe, B Chandran

Citation

R S, H Balachander, A Badhe, B Chandran. *Anaesthetic Management Of A Patient With Right Atrial Myxoma – A Case Report And Anaesthetic Considerations*. The Internet Journal of Anesthesiology. 2009 Volume 26 Number 1.

Abstract

Primary tumors of the heart are uncommon with an incidence ranging between 0.0017% and 0.19%. Approximately 75% of primary cardiac tumors are benign and 25% are malignant, with myxomas accounting for 50% of the benign tumors. Myxomas originate most commonly in the left atrium (75%). The next most frequent site is the right atrium (15%–20%) followed by the right and left ventricle (5% to 10% each)¹. The clinical manifestations of cardiac myxomas may vary from having one of the three classic presentations (outflow obstruction, embolism, and constitutional symptoms) to having mild or no symptoms^{1,2,3}. Hence a high degree of suspicion is essential in their diagnosis⁴. Anesthesiologists may encounter these exceedingly rare tumors during their routine practice, as an undiagnosed entity with other surgical conditions, or during the excision of these tumors under CPB. Although these tumors may pose a formidable anaesthetic challenge, surprisingly review of literature reveals very little regarding their anesthetic management. We present a patient with right atrial myxoma who developed severe intraoperative hypotension and persistent arrhythmias. We further discuss the various anaesthetic concerns in the management of patients with right atrial myxomas. The aim of this case report is to emphasize the need to have a high index of suspicion in the diagnosis and the importance of understanding the physiological alterations caused by these tumors and their clinical implications.

CASE REPORT

The patient, a 30 year old female presented to the out patient department with myalgia, arthralgia and low back ache. She also had exertional breathlessness (New York Heart Association Class 2) which worsened occasionally while lying down. She also had occasional spells of giddiness and symptoms suggestive of presyncope but had never lost consciousness. All these symptoms were present for the past six months. She did not have any significant past medical, surgical or family history.

On examination her pulse rate (PR) was regular at 88 beats per minute, equally palpable in all the extremities and her non invasive blood pressure (NIBP) measured in the right upper arm in the sitting position was 100/70 mm Hg.

Though her general examination was normal with no dysmorphic features, the examination of her cardiovascular system presented with a confusing array of findings. Her jugular venous pulsations (JVP) were raised (13 cm) with prominent a and v waves. There were added sounds in diastole which were considered to be an opening snap or a probable third heart sound. In addition in the tricuspid area, there was a grade 3/6 pansystolic murmur. The first and the second heart sounds were heard normally with no loud or

palpable P2. Examination of the respiratory system and the abdomen revealed no significant findings. An initial diagnosis of probable tricuspid valve pathology was made.

Laboratory investigations revealed hemoglobin of 13 g% and an ESR of 68. The 12 lead ECG was normal. A transthoracic echocardiogram revealed a large right atrial mass, measuring approximately 11 x 8 cms occupying most of the right atrium and prolapsing into the right ventricle during diastole causing an outflow tract obstruction. Moderate tricuspid regurgitation was noted. Concomitant septal defects were ruled out. A diagnosis of a probable right atrial myxoma was made.

Figure 1

Figure 1: Legend: Preoperative echocardiogram of the patient. The atrial myxoma is seen, prolapsing into the right ventricle.

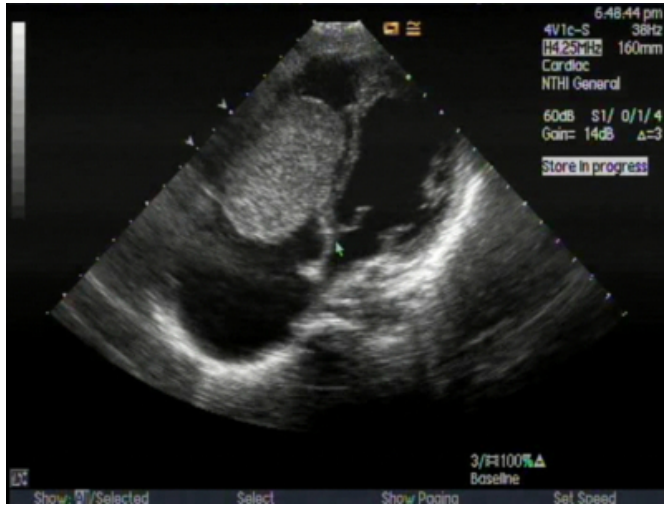
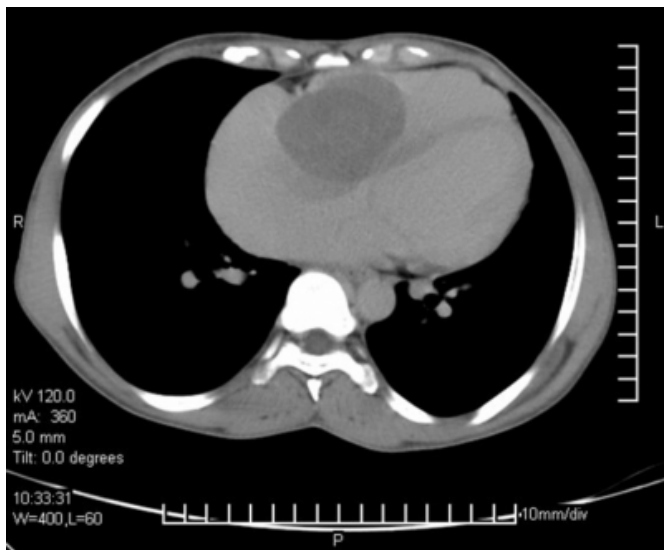


Figure 2

Figure 2: Legend: Preoperative CT thorax. A large right atrial myxoma is seen occupying nearly the entire right atrium.



The patient was scheduled for the excision of the tumour under cardiopulmonary bypass (CPB). Her height was 152cm and weight was 44kg. Preoperatively oral anti-aspiration prophylaxis (famotidine 20 mg and metoclopramide 10 mg) was given and anxiolysis was accomplished with diazepam 7.5mg (PO).

The patient did not complain of any significant discomfort with change of posture but had occasional discomfort in the supine position. Hence the patient was shifted to the

operating room (OR) with oxygen by mask, in a propped up position.

In the operating room (OR), the pulse oximeter recorded an oxygen saturation (SpO_2) of 99%. The heart rate (HR) was 90 beats per minute with a normal rhythm and a NIBP of 118/75 mm Hg was recorded. Peripheral intravenous access was secured with a 16 gauge cannula in the left forearm. Monitoring included NIBP, ECG (five lead) and SpO_2 . Intra arterial access was established using a 20 gauge angiocatheter in the right radial artery. An invasive blood pressure (IBP) of 97/68 mm of Hg was recorded. Central venous catheter (Arrow: 18G, 16G, 18G) was inserted into the right IJV. This site was chosen as it was thought to be most representative of the central venous pressure. The inherent risk posed by the presence of the myxoma in the right atrium and the risk of tumor fragmentation and embolism were taken into account and utmost care was taken during the insertion of the cannula. The distance was measured between the point of insertion and the sternal angle as 15 cms. The guide wire was inserted only upto approximately 10cms to avoid entering the right atrium. The pressure transducer was connected to the central lumen and the cannula was threaded and fixed at the point where the first CVP tracing was seen. The catheter was inserted only upto 8cm when the usual length of fixation of the cannula was 10 or 11 cms. No fall in oxygen saturation or blood pressure was noted and the patient was comfortable throughout the procedure. The mean CVP reading was 24 mm Hg. . All the intravascular accesses were established using 1%lidocaine as local anaesthetic.

A titrated general anesthetic technique was planned. Midazolam 2mg (0.05 mg/kg) intravenously was given followed by fentanyl 2mcg/kg. General anaesthesia was induced using titrated doses of thiopentone 1% (total dose 90mg) and vecuronium 4mg. There was a drop in blood pressure to 78/50mm Hg which improved with an intravenous fluid bolus of 200ml. Anaesthesia was maintained using isoflurane in a titrated manner and vecuronium was used for maintenance of muscle relaxation. Other than the temporary hypotension the induction of anaesthesia was uneventful.

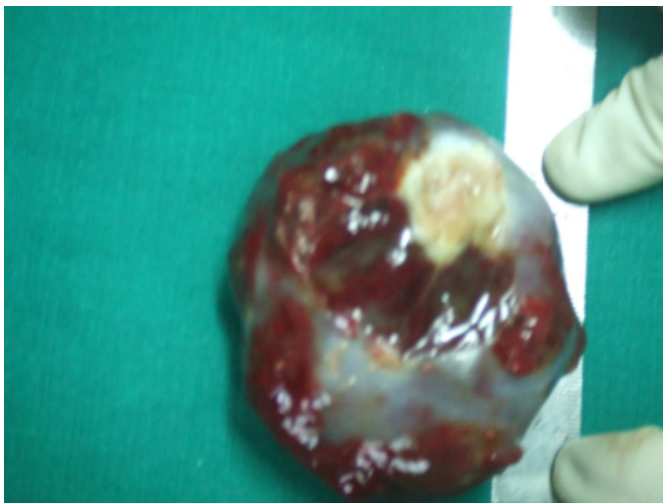
Sternotomy and pericardial dissection were uneventful. However, while purse string sutures were being taken for the insertion of the IVC cannula, there were a variety of atrial arrhythmias, which included an atrial flutter which terminated before any pharmacological treatment was given.

Soon after, a combination of arrhythmias (atrial flutter, 2:1 av block, 3:1 av block) occurred in rapid succession. These arrhythmias were accompanied by severe hypotension (average of 60/40 mm Hg) which did not respond to intravenous fluids and vasopressors. Cardiopulmonary bypass was initiated on an emergent basis.

Excision of the tumor in toto was done after opening the right atrium. The total bypass time was approximately twenty minutes (cross clamp time 10 minutes).

Figure 3

Figure 3: Legend: The excised right atrial myxoma.



Though the cardiopulmonary bypass as such was uneventful, weaning from it did entail a few problems. There were persistent atrial arrhythmias. But they were not associated with any hemodynamic instability. Hence no active intervention was undertaken. The patient was successfully weaned off CPB on minimal inotropic support (dopamine infusion 5µg/kg/min and adrenaline infusion 0.1µg/kg/min). Post weaning, the patient vital parameters were within normal limits. Though the atrial arrhythmias did persist, the patient was extubated the following day as the patient was hemodynamically stable. The atrial arrhythmias subsided over a period of three days. The postoperative echocardiogram revealed persistent tricuspid regurgitation.

DISCUSSION

Myxomas are the most common primary cardiac tumors^{1,2,5,6,7}. They are usually benign and have variable presentations¹. Jelic and associates have reported 8.6% symptomless patients in their 81 patient series³. The symptoms may depend on the position of the patient as the tumor is mobile within the atrium and assumes different positions depending

on patient posture^{8,9,10}. Common symptoms include congestive heart failure, peripheral embolization and syncopal episodes^{7,8,9,11}. However, cardiac myxomas may mimic various cardiovascular diseases, hence a high index of suspicion is important for their diagnosis^{4,7,8}. The natural history of atrial myxomas is not well established¹². In any case, surgical excision is the treatment of choice in these patients^{1,2,5,7,13,14}. Therefore once the cardiac myxoma is identified by two-dimensional echocardiography, the tumor should be removed even in patients without symptoms^{12,15}.

It is therefore important and essential to understand the clinical implications and the physiological alterations caused by the presence of an atrial myxoma, as anesthesiologists may have to anaesthetise patients with this rare tumor either for its excision or when they are present along with other surgical co morbidities.

The classic presentation of myxomas includes intracardiac obstruction with congestive heart failure (67%), signs of embolization (30-40%), and constitutional symptoms that can include fever (19%) or weight loss and fatigue (17%)¹⁶. The most common cause of acute presentation is from obstruction of blood flow in the heart. This might result in acute hypotension or in venous hypertension, hepatomegaly, ascites, and peripheral edema¹⁷. Blood pressure (BP) is the product of cardiac output (CO) and systemic vascular resistance (SVR). As the myxoma creates a fixed output status due the obstruction of the tricuspid orifice, whenever the SVR plummets, hypotension occurs. Thus during anaesthetic induction, hypotension is common. Furthermore, in our patient the more likely cause for the fall in blood pressure with induction may have been due to fall in systemic vascular resistance and venodilatation causing a decrease in right atrial filling and collapse of the atrial wall around the tumor converting a partial obstruction into a complete one.

The second episode of hypotension which was severe was due to arrhythmias resulting in circulatory collapse. Arrhythmias due to conduction defects are common in patients with atrial myxomas. Ergunes et al suggested that atrial diameter, tumor size, tumor attachment site and atrial incision may play a role in the occurrence of pre and postoperative arrhythmias¹⁵. It has also been suggested that the mechanical distension of the atrium and the relative hypoxia caused by the tumor may cause conduction defects and other arrhythmias¹⁰. Furthermore the anesthesiologist should be wary of the fact that there could be difficulty in

the insertion of the venous cannulae in the atrium due to the presence of the tumour¹⁸, and complications like hypotension, arrhythmias and embolisation are more likely during this time. Another important cause of hypotension in these patients, again due to outflow obstruction may be the posture. As the myxoma is mobile within the atrium, certain positions may cause complete obstruction of the AV outflow tract^{8,9,10}. To a certain extent this can be assessed preoperatively as patients are more symptomatic in those positions. Nevertheless a very carefully monitored positioning and titrated induction technique should always be employed, and all arrangements to go into an emergent cardiopulmonary bypass if required should be done even before anaesthetic induction to avoid catastrophic situations.

Dyspnea was noted to be the most common symptom in patients with myxomas in certain series⁷. Hypoxemia in these patients may be due to several reasons which include a low flow in the pulmonary circuit due to tumor obstruction, resulting in an increased work of breathing, a possible right to left shunt through the foramen ovale and pulmonary embolisation due to tumor fragmentation¹⁹. Patient position plays an important role in hypoxemia too as it is directly related to the pulmonary flow. Tumor embolisation should be avoided as emboli of right-sided myxomas can obstruct pulmonary arteries, cause acute pulmonary hypertension and even death from acute obstruction^{5,7,8,9,10,14,17}. Precautions should be taken during the insertion of the central venous cannula to avoid entering into the right atrium due to the risk of tumor fragmentation and embolisation¹⁹. Transesophageal echocardiography (TEE) is recommended intraoperatively to aid in recognizing and avoiding embolisation^{19,20}. Pulmonary artery catheters are relatively contraindicated in these patients for the fear of tumor fragmentation and embolisation¹⁹. Right to left shunts may coexist with these tumors^{1,5,9,10,11,18}. All intravenous tubing should be free of air to avoid paradoxical emboli¹⁹.

Regurgitant lesions may occur due to the wrecking ball effect of the tumor. A careful search for residual lesions should be done post excision to reduce postoperative morbidity. TEE helps in recognizing these residual valvular lesions if present²⁰.

To summarise, we present a patient with a right atrial myxoma who presented with hypotension on induction and severe atrial arrhythmias and hypotension requiring an emergent institution of CPB. Given below is a summary of the anesthetic considerations and precautions to be exercised

in patients with atrial myxomas.

ANAESTHETIC CONSIDERATIONS IN PATIENTS WITH RIGHT ATRIAL MYXOMAS:

1. Care should be exercised during positioning to avoid hypoxemia and hypotension
2. Hypoxemia may occur in these patients due to obstruction and decreased cardiac output, intracardiac shunting, pulmonary emboli or increased pulmonary dead space due to decreased flow. Supplemental oxygen should be provided
3. Pulmonary artery catheters are contraindicated for fear of tumour embolisation and in the presence of right to left shunts.
4. Entry into the right atrium should be avoided while inserting central venous catheters to avoid embolisation and precipitation of acute pulmonary hypertension.
5. Avoid air bubbles in the intravenous tubing to prevent paradoxical emboli, due to the probable presence of a right to left shunt in these patients.
6. Intraoperative TEE monitoring is recommended to aid in recognizing and avoiding tumour embolisation.
7. Hypotension during induction may occur due to obstruction of flow and low cardiac output, decreased systemic vascular resistance with a fixed cardiac output or due to venodilatation causing the RA to collapse and increasing the mechanical obstruction. Hence drugs causing venodilatation or fall in SVR should be used with caution.
8. Anticipate the possibility of requiring emergent CPB and make arrangements before induction of anaesthesia.

References

1. Klaus Reynen. Cardiac myxomas. The New England Journal of Medicine.1995; 333(24): 1610-1617.
2. R Rajani, N Sarangmath, B Mishra. Massive right atrial myxoma. International Journal of Cardiology; 128(1): 121-122.
3. Jelic J, Milicic D, Alfirevic I, et al. Cardiac myxoma: Diagnostic approach, surgical treatment and follow-up. A twenty years experience. J Cardiovasc Surg 1996;37:113-7
4. R F Wiley, M B Mathews, P R Walbaum. An unusual case of a large right atrial myxoma. British Heart

Journal.1980; 44:108-110.

5. Hiroomo Matayama, Shuji Tamaki, Naruyuki Kato, Narita Yuji. Right atrial myxoma associated with atrial septal defect. A case report and review of literature. *Annals of Thoracic and Cardiovascular Surgery*. 2001; 7(3):166-169.
6. Jay Silvermann, John S Olwen, John S Graeltenger. Cardiac myxomas with systemic emboli. Review of literature and report of a case. *Circulation*. 1962; 26:99-103.
7. Eugene.H.Mcloskey, Jayant B Mehta, K Krishnan, Thomas M Roy. Right atrial myxoma with extracardiac manifestations. *Chest*. Aug 2000. Vol 118; No 2:547-549.
8. D L Jardine, D L Lamont. Right atrial myxoma mistaken for recurrent thromboembolism. *Heart* 1997; 78:512-514.
9. Lawrence R Muroff, Philip M Johnson. Right atrial myxoma presenting as non resolving pulmonary embolism: A case report. *J Nucl Med* 1976; 17:890-892.
10. LD Anagnostopoulos, William R Wilson, J.L.Ehrenhaft. Myxoma of the right atrium. Report of a case and review of literature. *Arch Intern Med*. 1967; 120(3):330-336.
11. Kalgi Modi, Jessica Pullen, Pratap Reddy. Right atrial myxoma with atrial septal defect. A case report and review of literature. *The Internet Journal of Cardiology*. 2009; 6(2).
12. Feza Nurozler, Altay Tandogan, Birol Yamak. *Turkish journal of Thoracic and Cardiovascular Surgery*. Jan 2003; 11(1):52-53.
13. Anil Bhan, Ranji Mehrotra, Shiv Kumar Choudhary, Rajesh Sharma et al. Surgical experience with intracardiac myxoma: long term follow up. *Ann Thorac Surg*. 1998; 66:810-813.
14. Stefano De Carli, Leonardo Alberto Sechi, Rosanna Ciani, Giovanni Barillani. *Cardiology*. 1994; 84:368-372.
15. Kazim Erugunes, Ufuk Yetkin, Levent Yelek, Omer Tetik. Diagnosis and treatment in cardiac myxomas. *Anadolu Kardiyol Derg*. 2008; 8:379-380.
16. Mustafa Goz, Omar Cakir, Kenan Litemur, Nihal Kilinc. Right atrial myxoma in a patient presenting with syncope. *Turkish Journal of Thoracic and Cardiovascular Surgery*. 2006; 14(4):318-319.
17. Samer Kanan, Ismael Nuno. Atrial myxoma presenting as asthma in adolescent. *Internet Journal of Cardiovascular and Thoracic Surgery*. 2007; Vol 8: No 12.
18. Soma Guhalhakurta, John P Reordan. Surgical treatment of right atrial myxoma. *Texas Heart Institute Journal*. 2000; 27(1):61-63.
19. Howard A. Moritz, Said S. Azad. Right atrial myxoma: case report and anesthetic considerations. *Can J Anaesth*. 1989; 36(2):212-214.
20. Roberto Battelini, Torsten Bossert, Martin Areta, Damel Naura. Successful surgical treatment of a right atrial myxoma complicated by pulmonary embolism. *Interactive cardiovascular and thoracic anaesthesia*. 2003; 2:555-557.

Author Information

Roshni. S, M.D

Department Of Anaesthesiology And Critical Care, Jawaharlal Institute of Postgraduate Medical Education and Research (JIPMER)

Hemavathy Balachander, M.D

Department Of Anaesthesiology And Critical Care, Jawaharlal Institute of Postgraduate Medical Education and Research (JIPMER)

Ashok Shankar Badhe, M.D

Department Of Anaesthesiology And Critical Care, Jawaharlal Institute of Postgraduate Medical Education and Research (JIPMER)

B.V.Sai Chandran, Mch

Department Of Cardiothoracic And Vascular Surgery, Jawaharlal Institute of Postgraduate Medical Education and Research (JIPMER)