

Diagnostic Accuracy Of Fine Needle Aspiration Cytology In The Diagnosis Of Thyroid Lesions

S Gulia, M Chaudhury, E Sitaramam, K Reddy

Citation

S Gulia, M Chaudhury, E Sitaramam, K Reddy. *Diagnostic Accuracy Of Fine Needle Aspiration Cytology In The Diagnosis Of Thyroid Lesions*. The Internet Journal of Pathology. 2010 Volume 13 Number 1.

Abstract

Objectives :

(1) to study the cytological features in thyroid lesions (2) to correlate the cytological and histopathological observations in thyroid lesions, whenever possible (3) to assess the diagnostic accuracy of aspiration cytology as a pre-operative screening tool

Methods :

This was a retrospective study to find the utility of fine needle aspiration cytology in thyroid lesions conducted at Maharajahs Institute of Medical Sciences, Vizianagaram. Fine needle aspiration specimens from 140 patients between January 2008 and December 2010 with thyroid swelling were analysed. Smears were stained with papanicolou stain and haematoxylin and eosine stain. The smears were classified into categories like benign, suspicious/indeterminate, malignant and unsatisfactory. Cytological diagnosis was correlated with the histopathology report wherever possible.

Results

: Of the total cases the non-neoplastic category constituted the majority of the cases (82.85 %). These cases included colloid goiter, colloid goiter with haemorrhage, colloid goiter with cystic degeneration, thyroiditis, thyroglossal duct cyst and hyperthyroidism. Neoplastic lesions constituted 15.72 % of all cases and included follicular neoplasm and papillary carcinoma. 52 cases underwent surgery and biopsy report was correlated with the cytological diagnosis. The overall sensitivity of the study was calculated to be 90.0 %; specificity 100 %; positive predictive value 100 %; negative predictive value 90.5 % and diagnostic accuracy of 92.3 %.

Conclusions :

FNAC is considered as an invaluable and minimally invasive, simple, cost-effective, easily repeated procedure for pre-operative screening in the non-operative diagnosis for most of the thyroid lesions.

INTRODUCTION

The importance of thyroid cytology in the management of patients with thyroid pathology is highlighted in several guidelines^[1]. The workup of any patient requires full and appropriate clinical evaluation (biochemical, immunological, USG, radioisotope and imaging evaluation) before the decision to perform thyroid cytology is undertaken. Thyroid cytology can provide a definite diagnosis of malignancy, with tumor type, enabling appropriate therapeutic surgery in one stage. It can triage the remaining patients into those who potentially require surgical as opposed to medical/endocrinological management. Since the incidence

of thyroid malignancy is relatively low and only 1 in 20 clinically identified nodules are malignant^[2], thyroid fine needle aspiration can help reduce the rate of surgery for benign thyroid disease. Aspiration cytology of the thyroid is found to be a valuable adjunct to pre-operative screening in the diagnosis of thyroid lesions^[3]. Aspiration under ultrasound guidance is now widely used, particularly for nodules deep in the neck and when aspiration fails to yield adequate cellular material and it contributes to diagnostic accuracy^[4]. There is an ongoing debate as to appropriate evaluation and management of individuals with thyroid masses. Need to address these issues and to provide a

clinically applicable and cost effective approach to the evaluation and management of thyroid masses has prompted to take up this study.

FNA of thyroid nodules has many advantages :

1. safe, simple, cost-effective procedure with absence of major complications and can be performed on out - patients with wide patient compliance.
2. provides a more rapid and accurate diagnosis of the thyroid lesions than any other combination of clinical / laboratory tests[3,5].

Like any other diagnostic test FNA has some inherent limitations. Two issues in thyroid FNA are responsible for the majority of erroneous cytology reports :

1. inaccuracy and inadequacy of samples
2. inability to accurately subtype follicular neoplasms

MATERIALS AND METHODS

Medical records were reviewed for the patients with thyroid enlargement during the last 2 year period from Jan 2008-Dec2010 who subsequently underwent thyroid resection at Maharajahs Institute of Medical Sciences, Vizianagaram. The aspiration was done under aseptic conditions with 23 gauge needle fitted to a 5ml syringe. Several smears were prepared and promptly fixed in 95% ethyl alcohol. These were stained with papanicolaou stain and haematoxylin stain. Whenever fluid was obtained , centrifuged smears were made from the sediment and stained by the above stains. The cytology results were categorized into four categories as benign(negative), suspicious (indeterminate for malignancy), malignant and unsatisfactory / non-diagnostic. Aspirates classified as benign included colloid goiter, colloid or adenomatous nodule, hashimotos thyroiditis, sub-acute thyroiditis, thyroglossal duct cyst. Suspicious smears included follicular neoplasms, cellular adenomatoid nodules, hurthle cell proliferations and lesions suspicious for papillary carcinomas. Aspirates with insufficient cellularity or poor quality smear due to delayed or inadequate fixation were considered unsatisfactory.

An adequate sample must be taken and adequate in amount. Criteria proposed for adequacy of thyroid cytology is 5-6 groups of well preserved follicular epithelial cells with ≥ 10 cell per group , the smear should be technically well prepared , the aspirate should be properly smeared to avoid

clotting and lastly smears should be read in clinical context^[3]. Aspirations considered unsatisfactory should be repeated because cancer has been reported in 5-15 % of these cases^[4].

Whenever the excised specimen was received in the department, it was routinely processed to obtain paraffin sections which were stained by H&E stain. Results of cytological and histopathological studies were later correlated to evaluate the efficiency of FNAC. Diagnostic accuracy of FNA was calculated.

Hence thyroid aspiration is useful :

1. to detect patients with thyroid malignancy(sensitivity)
2. to exclude patients without malignancy(specificity)
3. to predict the presence/absence of cancer(positive and negative predictive value)
4. to correctly classify patients as those who should have their thyroid masses excised and those for whom excision is unnecessary(efficiency)

RESULTS

In our study the mean age of patients was 38yrs with range of 9 – 60 yrs. Most of the patients were in the age group of 31 – 50 yrs.

Most of the patients were females : 127 (90.71 %) out of the total 140 cases.

Male to female ratio was 1: 9.77.

Of the total 140 cases of FNAC , 116 cases (82.85 %) were non – neoplastic and 22 (15.72%) were neoplastic lesions(as shown below in table I and fig I).

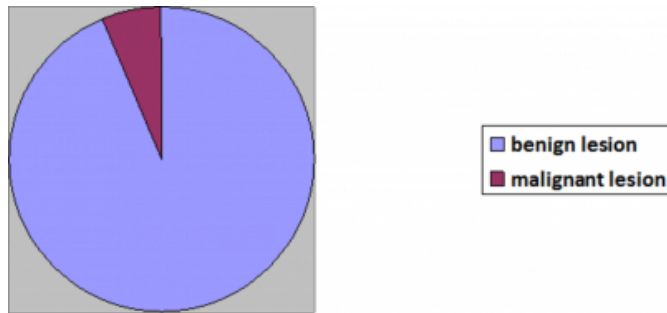
Figure 1

Table I : shows total no. of cases

Diagnosis	No of cases	%age of cases
Benign lesions	131	93.57
Malignant lesions	09	06.43
Total	140	100

Figure 2

fig 1 shows % of total cases on FNAC



Of the benign/non-neoplastic diagnosis , colloid goiter was the most common thyroid lesion diagnosed in 104 cases(74.29%) cases. The other benign lesions diagnosed were hashimotos thyroiditis in 5(3.51%) cases , de quervains thyroiditis in 2(1.43%) cases , thyroglossal duct cyst in 3(2.14%) cases , and hyperthyroidism in 2(1.43%) cases(as shown below in table II and fig II).

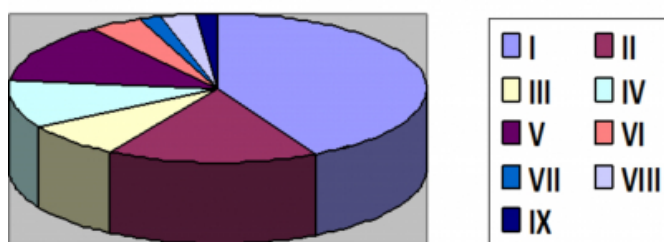
Figure 3

Table 2 : Incidence of non – neoplastic thyroid lesions according to FNAC

S. no	Non neoplastic cytological diagnosis	No of cases	Percentage of cases(%)
I	Simple colloid goiter	49	35.00
II	Nodular colloid goiter	19	13.57
III	Colloid goiter with haemorrhage	9	6.43
IV	Colloid goiter with cystic degeneration	12	8.57
V	Colloid goiter with adenomatous hyperplasia	15	10.71
VI	Hashimotos thyroiditis	5	3.57
VII	De quervains thyroiditis	2	1.43
VIII	Thyroglossal duct cyst	3	2.14
IX	Hyperthyroidism	2	1.43

Figure 4

fig- 2 showing % of non-neoplastic diagnosis on FNA of thyroid



Of the malignant lesions on cytology , follicular neoplasm constituted a total of 13 cases(9.29 %) and papillary carcinoma diagnosed in 9(6.43%) cases(as shown in table 3)

Figure 5

Table 3 : Incidence of Neoplastic thyroid lesions according to FNAC

Neoplastic diagnosis on FNAC	No of cases	%age of cases
Follicular neoplasm	13	9.29
Papillary carcinoma	09	6.43

Figure 6

Table 4 : Cytohistopathological correlation of thyroid lesions

Cytological diagnosis	Histopathologic diagnosis					
	No of cases	Nodular colloid goitre	Hashimotos thyroiditis	Follicular adenoma	Follicular carcinoma	Papillary carcinoma
Colloid goiter	35	35				
Hashimotos thyroiditis	2		2			
Follicular neoplasm	6	2		3	1	
Papillary carcinoma	9					9

Histopathological diagnosis was available (as shown in table no.4 above) in 52 cases. 6 cases of follicular neoplasms on FNA which were subsequently examined on histopathology were found to be follicular adenoma in 3 cases , colloid goiter in 2 cases and follicular carcinoma in 1 case . 2 cases of hashimotos thyroiditis were confirmed histologically. All 9 cases of malignancy reported on FNA as papillary carcinoma were confirmed as malignancy on biopsy.

Hence , after comparison of results of FNAC with histopathology , FNA showed overall diagnostic accuracy of 92.3% with specificity of 90.0% , sensitivity of 100% for malignant lesions, positive predictive value of 100% for malignancy and negative predictive value of 90.5% in our study.

DISCUSSION

All types of false negative and false positive results cause concern because the reliability of cytology is in question. However , it is difficult to calculate the true frequency of false negative results because only a small percentage of patients with benign cytological findings undergo surgery. False negative FNA cytology results were found in four of our patients which is less as compared to other studies where the values range from 1-16%^[6,7,8].False negative rate in our study was 3.85%. Apparently false negative cases are encountered when there are no recognizable diagnostic cells in the smear because of sampling or processing error. The incidence of false negative in diagnosis of thyroid aspirates may be high and is usually attributable to overlooking of malignancy in favour of follicular adenoma , cystic lesions

and hashimotos thyroiditis.

False positive result cytology are uncommon and were not found in any patient in our study. This finding is consistent with the other reports that cited rate ranging from 0 – 9%^[9]. False positive diagnosis is the result of misinterpretation of the nature of benign cell than a sampling error. False positive diagnosis are usually encountered in hashimotos thyroiditis ,follicular/parathyroid/atypical adenoma , colloid nodule.

The categorization of cytological results into benign , suspicious , malignant and unsatisfactory/inadequate is necessary to allow clinicians to use cytology results to guide the patient management with specific reference to surgery. Follicular neoplasms form a gray zone with differential diagnosis including follicular carcinoma , follicular variant of papillary carcinoma , follicular adenoma and adenomatoid nodule. Follicular adenoma and follicular carcinoma requires detailed histopathological examination for vascular and capsular invasion.

Many papers on the diagnostic sensitivities for thyroid nodules exist in the literature , showing a wide range from 43 – 100% and specificity from 47 – 100%^[6,7,10,11,12]. Factors contributing to this broad range of sensitivity and specificity are the handling of suspicious cases , adequacy of sample , sampling techniques , experience of pathologist in interpretation , length of follow up and inclusion of suspicious/indeterminate cases in the category of false negative diagnosis. In our study , the specificity for cytological diagnosis of neoplasia was 90.0% , sensitivity of 100% , positive predictive value of 100% , negative predictive value of 97.67% and diagnostic accuracy of 92.3%. The results are comparable with the other studies. Afroze et al(2002) reported in his study sensitivity of 61.9% , specificity of 99.3% , negative predictive value 94.7% , positive predictive value 92.8% and accuracy of 94.5%^[26]. Ikram et al has reported sensitivity and specificity for malignancy as 100% which is higher than our results as they do not have false positive results in their study due to small number of patients^[29]. Kessler et al , 2005 , reported 79% sensitivity , 98.5% specificity , negative predictive value 76.6% , positive predictive value 98.7% and diagnostic accuracy of 87%. Gupta et al ,2006 , reported 80% sensitivity , 86.6% specificity , 86.6% negative predictive value , positive predictive value of 80% and accuracy of 84^[22]. Mahar SA et al (2006) reported a sensitivity of 98%,specificity of 70% with positive predictive value of

91%,negative predictive value of 93% and diagnostic accuracy of 91%^[30].

Figure 7

Study	Sensitivity(%)	Specificity(%)	Diagnostic accuracy(%)
Afroze et al(2002) ^[26]	61.9	99.3	94.5
Ikram et al ^[29]	100	100	-
Kessler et al(2005)	79	98.5	87
Gupta et al(2006) ^[22]	80	86.6	84
Mahar SA et al(2006) ^[20]	98	70	91
Flanagan et al(2006) ^[21]	81.7	56.4	82
Chao et al(2007) ^[32]	86.1	59	64.6
Bukhari et al(2010) ^[31]	85	90	87
Prakash H et al(2011) ^[34]	66.66	98.4	95.71
Present study 2011	100	90	92.3

CONCLUSION

FNA is the most recommended diagnostic procedure for the diagnosis of thyroid lesions since it allows the distinction between benign and malignant lesions and helps to design the treatment plans. Technical procedure for the aspiration and smear preparation are important steps for obtaining suitable smears. Adequacy of the specimen(must be representative of the lesion) , adequate in amount and read in clinical context will reduce false positive numbers. If the cytologic report is malignant , surgery is the recommended procedure ; for suspicious lesion, respiration is required ; for benign report no further immediate diagnostic studies are required.

Ongoing histocytological correlation is an important quality control assurance measure and allows labs to calculate there false positive and false negative rates. Hence , FNA is an invaluable tool in the management of thyroid lesions with a high degree of accuracy.

References

1. British Thyroid Association RCoP . Guidelines for the management of Thyroid Cancer , 2nd edition. Report of the Thyroid Cancer Guidelines Update Group London :RCP 2007
2. Wong CKM , Wheeler MH. Thyroid Nodules : Rational Management. World J Surg 2000 ; 24 : 934 – 41
3. Jayaram G. Fine Needle Aspiration Cytologic Study of the Solitary Thyroid Nodule : Profile of 308 cases with Histologic Correlation. Acta Cytol 1985 ; 29 : 967 – 73.
4. Danese D, Sciacchitano S , Farsetti A et al. Diagnostic Accuracy of Conventional versus Sonographic Guided Fine Needle Aspiration Biopsy of Thyroid Nodules. Thyroid 1998 ; 8 : 15 – 21
5. Kaur K , Sonkhya N , Bapna A S , Mittal P A : A Comparative Study of Fine Needle Aspiration Cytology , Ultrasonography and Radionuclide Scan in the Management of Solitary Thyroid Nodule : A Prospective Analysis of fifty cases : Ind J Otolaryngol Head Neck Surg 2000 ; 54(2) : 96 – 101
6. Ghariab H . Fine Needle Aspiration of Thyroid Nodules – Advantages , Limitations and Effects. Mayo clinic proc 1994 ; 69 : 44 – 49
7. Caraway H P Sniego N , Saman . Diagnostic pitfalls in Thyroid Fine Needle Aspiration : a review of 394 cases. Diagnostic Cytopathol 1993 ; 9 : 345 – 50

8. Baloch Z W , Fleisher S , Li Volsi V A et al. Diagnosis of Follicular Neoplasm : A Gray Zone in Thyroid Fine Needle Aspiration Cytology. *Diagn Cytopathol* 2002 ; 26 : 41 – 44
9. Goldstein R E , Netterville J L , Burkey B , Johnson J E . Implications of Follicular Neoplasms , Atypia and Lesions Suspicious for Malignancy Diagnosed by Fine Needle Aspiration of Thyroid Nodules. *Ann Surg* 2002 ; 235 : 656 – 64
10. Bakhos R , Selveygi S M , Dejong S , et al. Fine Needle Aspiration of the Thyroid : Rate and Causes of Cytohistopathologic Discordance. *Diagn Cytopathol* 2000 ; 23 : 233 – 37
11. Boey J , Hsu C , Collins R J. False Negative Errors in Fine Needle Aspiration Biopsy of Dominant Thyroid Nodules. A prospective follow up study. *World J Surg* 1986 ;10 : 623 – 30
12. Hamburger J I , Husain M .Semiquantitative Criteria for Fine Needle Biopsy Diagnosis : Reduces False Negative Diagnosis. *Diagn Cytopathol* 1988 ; 4 : 14 – 17
13. Singer P A . Evaluation and Management of the Solitary Thyroid Nodule. *Otolaryngol Clin of North Am* 1996 ; 29 : 577 – 91
14. Dorairajan N , Jayashree N. Solitary Nodule of the Thyroid and the Role of Fine Needle Aspiration Cytology in Diagnosis. *J Indian Med Ass* 1996 ;94(2) : 50 – 52
15. Singh A , Kahlon S K , Chahal K S , Kaur B , Kaur J . Hashimotos thyroiditis – an Unusual Presentation as Cystic Solitary Nodule – a Diagnostic Dilemma. *Journal of Cytology* 2003 ; 20(4) : 193 – 195
16. Belfiore A , La Rosa G L . Fine Needle Aspiration Biopsy of the Thyroid. *Endocrinol Metab Clin North Am* 2001 ; 30 : 361 - 400
17. Haberal A N , Toru S , Ozen O , Arat Z , Bilezikci . Diagnostic Pitfalls in the Evaluation of Fine Needle Aspiration Cytology of the Thyroid : Correlation with Histopathology in 260 cases . *Cytopathology* 2009 ; 20 : 103 – 108
18. Baloch Z W , Sack M J , Yu J H , Livolsi V A , Gupta P K . Fine Needle Aspiration of Thyroid an Institutional Experience . *Thyroid* 1998 ; 8 : 565 - 69
19. American association of clinical endocrinologist and associazione medici endocrinology task force on thyroid nodules . Medical guidelines for clinical practice for the diagnosis and management of thyroid nodules . *Endocrine Pract* 2006 ; 12 : 65 – 93
20. Coopers D S , Doherty G M , Haugen B R et al . Management Guidelines for patients with Thyroid Nodules and Differentiated Thyroid Cancer . *Thyroid* 2006 ; 16 : 4 – 33
21. Jyothi B Lingegowda , Prakash H Muddegowda , Rajesh Kumar N , Ramkumar Kurpad R . Application of Pattern Analysis in Fine Needle Aspiration of Solitary Nodule of Thyroid . *Journal of Cytology* 2010 ; 27(1)
22. Manoj Gupta , Savita Gupta , Ved Bhushan Gupta . Correlation of Fine Needle Aspiration Cytology with Histopathology in the Dignosis of Solitary Thyroid Nodule . *Journal of Thyroid Research* 2010 ; article ID 379051 : 5pages
23. H.M.Al-Sayer , Z.H. Krukowski , V.M.M.Williams and N.A.Matheson . Fine Needle Aspiration Cytology in Isolated Thyroid Swellings : a Prospective two year Evaluation . *British Medical Journal* 1985 ;290(no.6840) : 1490 – 92
24. A. Kessler , H.Gavriel , S.Zahav et al. Accuracy and Consistency of Fine Needle Aspiration Biopsy in the Diagnosis and Management of Solitary Thyroid Nodules . *Israel Medical Association Journal* 2005 ; 7(6) : 371 – 73
25. Gardener H A , Ductman B S , Wang H H .Predictive Value of Fine Needle Aspiration of Thyroid in the Classification of Follicular Lesions . *Cancer* 1993 ; 71 : 2598 – 603
26. Afroze N , Kayani N , Haasan S H .Role of Fine Needle Aspiration Cytology in the Diagnosis of Palpable Thyroid Lesions . *Indian L Pathol Microbiol* 2002 ; 45(3) : 241 – 6
27. Safirullah , Navm Mumtaz , Akbar Khan . Role of Fine Needle Aspiration Cytology in the Diagnosis of Thyroid Swellings . *J Postgrad Med Inst.* 2004 ;18(2) : 196 – 201
28. Constantine G.A.Theoharis , Kevin M. Schofield , Lynwood Hammers , Robert Uhelsman and David C.Chhieng . The Bethesda Thyroid Fine Needle Aspiration Classification System : Year I at an Academic Institution . *Thyroid* 2009 ; vol 19 : 1215 – 1223
29. Ikram M , Hyder J , Muzaffar S , Hasan SH. Fine Needle Aspiration Cytology in the management of thyroid pathology the Aga Khan University Hospital experience. *J Pak Med Assoc* 1999 ; 49(6) : 133-5
30. Mahar SA , Husain A , Islam M. Fine Needle Aspiration Cytology of Thyroid Nodule : Diagnostic Accuracy and Pitfalls.*J Ayub Med Coll Abbottabad* 2006 oct-dec ; 18(4) : 26-9
31. Flanagan MB , Otori NP , Carty SE , Hunt JL.Repeat thyroid nodule fine needle aspiration in patients with initial benign cytologic results : *Am J Clin Pathol* 2006 ;125 : 698-702
32. Chao , Lin JD , Chao HH , Hsueh C , Chen MF.Surgical treatment of solitary thyroid nodules via fine needle aspiration biopsy and frozen section analysis.*Ann Surg Oncol* 2007 ; 14 : 712 – 718
33. Bukhari MH , Niazi S , Hanif G , Qureshi SS , Munir M,Hasan M.An updated audit of fine needle aspiration cytology of solitary thyroid nodule .*Diagn Cytopathol*2008 ; 36 : 104-112
34. Prakash HM , Jyothi BL , Shankar SH , Kishanprasad HL , Ramaswamy AS , Aravinda P.Aspiration biopsy cytology of solitary thyroid nodule.*NJBMS* 2011 ; 1(3) : 150-153

Author Information

Sandhya Panjeta Gulia, MD Pathology

Assistant Professor, Dept of Pathology, Sri Venkateshwaraa Medical College Hospital and Research Centre

Madhusudhan Chaudhury

Professor, Dept of Pathology, Sri Venkateshwaraa Medical College Hospital and Research Centre

Emani Sitaramam, MD Pathology

Associate Professor, Dept of Pathology, Maharajahs Institute of Medical Sciences

Karri Prasada Reddy, MD Pathology

Professor, Dept of Pathology, Maharajahs Institute of Medical Sciences