

# Results Of Antegrade Humeral Interlocking Nailing In Adults – A Prospective Study

S Rawa, M Farooq, S Singh, M Wani, M Bhat, A Hussain, M Mussa

## Citation

S Rawa, M Farooq, S Singh, M Wani, M Bhat, A Hussain, M Mussa. *Results Of Antegrade Humeral Interlocking Nailing In Adults – A Prospective Study*. The Internet Journal of Surgery. 2009 Volume 24 Number 2.

## Abstract

The aim of the present study was to evaluate the results of closed diaphyseal fractures of humerus treated by inter locking intramedullary nailing. Twenty five humeral shaft fractures were treated by closed intramedullary interlocking unreamed antegrade nailing between Jan. 2003 to Jan. 2005. There were 20(80%) males and 5 (20%) females with average age of 34.4 years (18 to 60 years). Fall from height was most common mode of injury (68%). Average time between injury and surgery was 6.2 days (4 to 15 days), pathological fractures were excluded. Union rate was 96%, based on clinical and functional American shoulder and elbow surgeons (ASES) Shoulder score, seventeen patients had excellent result, four had good and four had poor results. The most common postoperative complication was shoulder stiffness occurring in four patients. There was no iatrogenic radial nerve palsy. We conclude that interlocking nailing is a viable option in treating acute humeral shaft fractures, the most common adverse outcome of shoulder stiffness and impingement can be decreased by meticulous surgical technique.

## INTRODUCTION

Closed treatment of humeral shaft fractures has been recorded since ages and multiple methods advocated with reports of variable success. Among these hanging arm cast, abduction humeral shoulder spica cast, overhead traction, U-splint and velopeu dressing and functional brace are extensively used procedures [1,2]

The inherent problems of closed methods viz; inability to anatomically align fragments, distraction at the fractures site, delayed union and non-unions, prolonged immobilization and the disability thereof outweighs the benefits of these versatile closed treatment methods. It is almost inapplicable in open fractures, fractures associated with the vascular and nerve injuries, bilateral fractures, multiply injured patients, Ipsilateral forearm fractures and fractures with overlying burns. [1, 3, 4, 5]

Prior to the advent of interlocking intramedullary devices, osteosynthesis with compression plate was the so called 'gold standard' for the surgical treatment of the humeral shaft fractures. However, intramedullary nails have certain potential advantages over plates and screws. The intramedullary nail is closer to the normal mechanical axis and can act as load shearing device. They are subject to lower bending forces, making failures by fatigue less likely [5]. Intramedullary nails can be placed with out direct

fracture exposure and with much less soft tissue dissection.[5]. Additionally cortical osteopenia caused by stress shieling as seen with plates and screws is less likely.[5]

Several reports had demonstrated that with newer implants and improved techniques, locked intramedullary nailing can have a success rate as high as that of other methods [6,7].

## MATERIAL AND METHODS

Between January 2003 and January 2005 we treated twenty five patients of humeral shaft fractures in adults with modified Grose – Kempf nail.

Total of twenty five intramedullary nailings were carried out on 20 male (80%) and 5 females (20%) patients, with male female ratio of 4:1. The patients included in our study were between 18-60 years with an average age of 34.4 years. Most cases 52% were in age group  $\leq$  to 30 years. Right side was involved in 56% as compared to left side (44%), fall from height was most common cause of injury 68%, 20% had road traffic accident, 4% blast injury, 4% blunt trauma and 4% had fall of heavy object on the limb. Majority of patients had mid diaphyseal fractures (64%), 20% had proximal and 16% had distal humeral shaft fracture.

All fractures were classified according to Winquist classification [8]. 14 fractures were type I, 8 were type II, 3

were type III. 80% of the patients included in our study were those in whom closed treatment had failed. 12% those with > 50% comminution of the bone, non complaint patients to conservative treatment were 8%.

Patients with open fractures, residual deformity, bilateral fractures, poly trauma patients, pathological fractures, floating elbow injuries and patients with radial nerve palsy were excluded in our study. The minimum interval between injury and surgery was 4 days and maximum 15 days (average 6.2 days). The average duration of surgery was 82.6 minutes, (60-135minutes).

### **TECHNIQUE OF OPERATION**

We used modified Grose – Kempf nail in all of our patients. All nailing procedures were performed under GA and image intensifier. The procedures were done in supine position with head rotated to contralateral side on radiolucent table. A longitudinal skin incision 1-3cm centered over tip of greater tuberosity was given. An awl was passed just medial to tip of greater tuberosity, 0.5cm posterior to biceptal groove to make an entry point. Reaming of the proximal metaphysis of the humerus to a diameter of 8mm for approximately 4cm was done. Close reduction was achieved under C-arm guidance and guide wire was passed, the length of the nail was measured by subtracting exposed guide wire from the total length of guide wire. In 2 cases, where closed reduction failed minimum open reduction was done. While maintaining the reduction, guide wire was removed and the nail of proper length and diameter was passed till its proximal end was beneath the bone by 0.5cm to avoid subacromial impingement. Proximal and distal locking was done.

Post operatively soft bulky dressings were used and the limb was kept in shoulder arm pouch. Check X-ray were taken of the full humeral length. Patients were kept on antibiotic for 3-5 days depending upon the wound condition in most cases. Passive range of motion exercises at shoulder and elbow were started on the 3<sup>rd</sup> post operative day when pain and swelling had subsided. Regular antiseptic dressing were done and the patients were discharged from 3<sup>rd</sup> to 5<sup>th</sup> post operative day. Stitches were removed from 10th to 14th days post operatively. Thereafter active range of motion exercises were started. Patient were followed up every 4 weeks till 6 months, detailed examination and check x-rays were taken to see the progress of fracture healing.

Radiological assessment was done to assess: union, time of union (months) delayed union and non union. Union was

said to have occurred when a mature callus formation bridging across the fracture on two radiographic views. Non-union was said to have occurred when fracture had not achieved union by the end of 6 months. All radiologically united fractures were finally assessed at the end of 6 months clinically and functionally. Clinical assessment was based on severity of pain in operated limb and active range of motion of shoulder and elbow, functional assessment was done as per system of American shoulder and Elbow Surgeons (ASES) shoulder score as adopted by Mc-Cormack (2000).[9]

### **RESULTS**

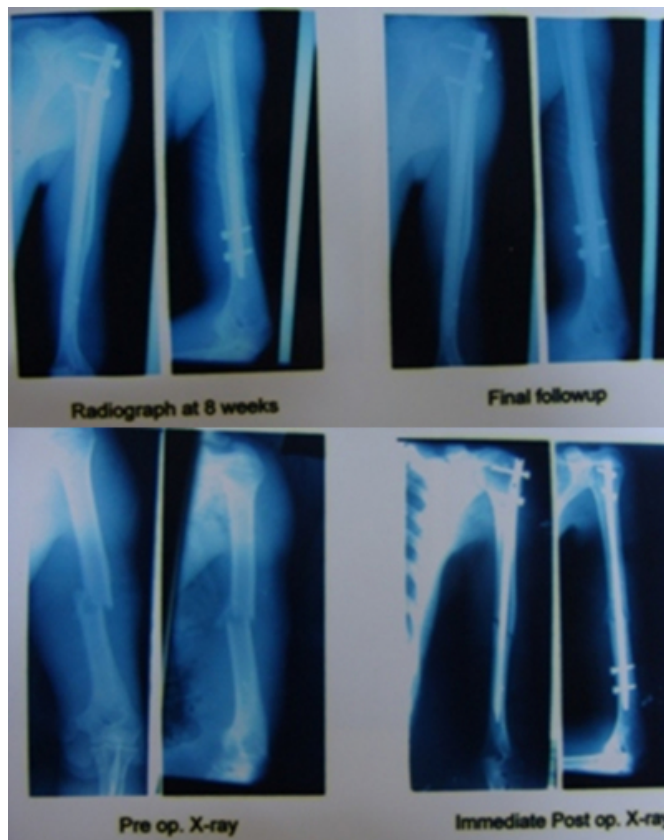
The average hospital stay was 4-8 days with range of 3 to 18 days. We had no post operative infection or radial nerve palsy. Post operative radiographs revealed that in 68% of patients nail was placed centrally in medullary canal and in 32% (8 patients) nail was placed eccentrically. The placement of intramedullary nail had no influence on fracture healing. In one patient proximal nail end was protruding from the entry site, one patient had comminution at the fracture site, while another patient had distraction at the fracture site which was attributed to improper selection of nail length and diameter. This patient with initial distraction developed non union and was treated by exchange nailing.

The average time for radiological union was 11.33 weeks (range 8 to 16 weeks) (Figure 1 and 2)). Seven (28%) patients achieved union at the end of 8 weeks, 12 (48%) patients united at 12 weeks and 5 patients united at 16 weeks. The union rate was 96%. Only one fracture did not unite which was attributed to initial distraction at the fracture site.

All radiologically united fractures were evaluated for final assessment at the end of 24 weeks. The non-union was considered poor result. Three parameters were combined for assessment, viz. pain severity, grade of ROM at shoulder and elbow, (Grade I, loss of ROM <10°, Grade II loss of ROM 10-13°, grade III loss of ROM > 30° in any direction) and functional assessment as per ASES score as adopted by Mc-Cormack (2000) [9].

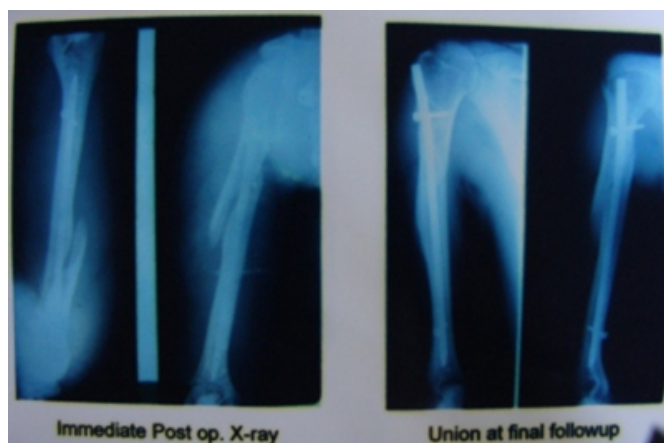**Figure 1**

Figure 1- Showing fracture of humerus till union treated by nailing



**Figure 2**

Figure 2- Immediate post op and at the time of union



Pain grading improved as the followup progressed but in patients where stiffness and impingement was a resultant complication, mild to moderate pain was recorded even at final follow up in 3 patients. Range of motion of both elbow and shoulder improved as the follow up progressed. None of our patients had elbow stiffness at the final assessment. Limitation of shoulder abduction  $<120^\circ$  was most common

limitation of reduced ROM (6 patients) followed by decreased flexion  $<120^\circ$  in 3 patients. Seventeen patients achieved grade I ROM, 4 patients grade II ROM and 4 patients grade III ROM at final follow up.

Functional assessment was significantly affected by ROM shoulder. Patient who had limited ROM shoulder had poor functional results. Seventeen of our patients achieved score  $>45$ , four patients achieved functional score between 35-45 and four patients achieved functional score  $<35$ . Our final results were excellent in 17 patients, 4 had good and 4 had achieved poor results.

The most common post operative complication was shoulder stiffness occurred in 16% patients, 4% developed shoulder impingement and non-union was recorded in one (4%) of patients. No patient developed radial nerve palsy or infections.

We encountered few problems during intramedullary interlocking procedure. One patient developed intraoperative comminution at the fracture site, though it had no effect on fracture healing and the fracture eventually healed within 8 weeks. This patient had no long term complications. In two cases wherein we failed to closely reduce the fracture, minimal open reduction was done to achieve reduction. Above elbow plaster of paris slab was applied for 6 weeks in two patients in whom distal locking could not be done. In one of our patients proximal nail end was protruding and patient continued to have pain in shoulder and limited ROM. Nail was removed at 12 weeks when fracture had united. Pain and ROM improved in this patient at final assessment i.e. 24 weeks.

### DISCUSSION

Any discussion concerning surgical treatment of humeral shaft fractures must first consider the excellent results that can be achieved with non-operative care. However, operative treatment in the selected cases may be benefited from interlocking nailing as this treatment implies earlier resolution of function and fewer complications. This is especially relevant in multiply traumatic patients who need early mobilization.

In our series out of 25 cases, 24 fractures had united by the end of 4 months with an overall union rate of 96%. This result is comparable to the union rate achieved by McCormack (89.48%)[9], Cox M.A (87.9%) [10], Crates J (94.5%).[11] Robinson et.al.[12] and Hems et.al. [13] reported non-union rate of 23% and 29% respectively after

Seidel's interlocking nailing. In our study one patient (4%) developed non-union which we attribute to distraction at the fracture site. We believe that distraction at the fracture site may be prevented during antegrade nailing by pushing or thumping at elbow after proximal locking. Once the distraction and rotations are corrected by thumping distal locking should be done.

Shoulder impingement and stiffness were the main concerns in antegrade nailing in many studies. Proximal nail protrusions were attributed to this problem using Seidel's nail [12,13,14]. Modification in nail design in subsequent years has addressed this problem. In our study using Grosse – Kempf nail only one patient had proximal nail protrusion. However, we relate this problem to improper selection of nail size.

Persistent pain after antegrade nailing has been a problem in various studies[6,12,15]. We concur with the established findings that this problem can be reduced by meticulous dissection, proper repair of rotator cuff. This was the main complication in our series. Four (16%) of our patients had persistent pain in shoulder at final follow up. However, we agree with Rommens et.al. [7] that retrograde nailing will preserve shoulder function.

Some authors [16] recommend open technique while passing distal interlocking screw from lateral aspect of humerus to avoid injury to the radial nerve and posterior coetaneous nerve of forearm. We encountered no such problem as we locked the nail with distal interlocking screw from anterior to posterior direction. Mc-Carmack et.al.[9] reported 14.2% of his patients developing radial nerve palsy, mostly neuropraxia, with full recovery in post operative period. Hems et.al. [13] reported 9.5% radial nerve palsy during manipulative reduction of distal third fractures and claimed full recovery in his patients.

Lin J [17] reported that in spiral fractures with lateral spike, the radial nerve may be entrapped in fracture site with or without radial nerve palsy. He emphasized the importance of nerve exploration in such a situation. We used unreamed nails and achieved 96% of union rate and also avoided the possible damage to radial nerve during reaming. We infer that reaming could cause severe radial nerve damage in

closed nailing that can be avoided by using unreamed nail.

### References

1. Zuckerman JD, Koval KJ: Fractures of the Shaft of the humerus. In: Rockwood CA, Green DP, Bucholz RW, Heckman JD, eds. Rockwood and Greens. Fractures in adults 4th edition Philadelphia, Pa: Lippincott-Raven; ,1996 ,1025-1053.
2. Crenshaw AH: Shaft of humerus. In: Canale ST, ed Campbell's operative Orthopaedics 9th ed. St Louis, Mo: Mosby: 1998,2296-2309.
3. Foster RJ, Dixon GL Jr, Bach AW, et al: Internal fixation of fractures and non-unions of the humeral shaft. Indications and results in a multi-center study. J Bone Joint Surg Am Jul; 1985, 67 (6) :857-64.
4. Gregory PR, Sanders RW: Compression plating versus intramedullary fixation of Humeral shaft fractures. JAM Acad Orthop. Surg, Jul1997; 5(4): 215-223.
5. Beaty JH: Hameral shaft fractures. In: Orthopaedic knowledge update: Rosemont, III: American Academy of Orthopaedic surgeons: 1999, 278-286.
6. Ingman AM, Waters DA: Locked Intramedullary nailing of humeral shaft fractures. Implant design, surgical technique, and clinical results. J. Bone Joint Surg Br. : 1994, 76(1); 23-9.
7. Rommens PM, Verbruggen J, Broos PL; Retrograde locked nailing of humeral shaft fractures. A review of 39 patients. J. Bone joint Surg Br. 1995; 77(1):84-9.
8. Winquist R, Hansen S, et.al. closed intramedullary nailing of femoral fractures. J. Bone Joint Surg. Am; 1984, 529-539.
9. Mc Cormack RG, Brien D, Buckley RE, McKee MD, Powell J. and Schemitsch EH: Fixation of fractures of the shaft of humerus by dynamic compression plate or intramedullary nail, a prospective randomized trail; J Bone J.Surg.(Br); 2000, 82-B:336-39.
10. Cox MA, Dolan M, Synnott K, et.al. closed interlocking nailing of humeral shaft fracture with Russel – Taylor nail. J. Orthop Trauma. 2000 , 14: 349 – 353.
11. Crates J, Whittle AP. Antegrade interlocking nailing of acute humeral shaft fractures. Clin. Orthop: 1998, 350: 40 – 50.
12. Robinson CM, Bell KM, Court-Brown CM. Mc Queen MM; Locked nailing of humeral shaft fractures. Experience in Edin Burgh over a two year period. J. Bone Joint surg. Br.; 1992, 74(4): 558-62.
13. Hems TE, Bhullar TP: Interlocking nailing of humeral shaft fractures: the Oxford experience 1991 to 1994. Injury; 1996, 27:485-89.
14. Riemer BL, Foglesong ME, Burke CJ 3rd. Complications of seidel intramedullary nailing of narrow diameter humeral diaphyscal fractures: Orthopaedics; 1994, 17(1) 19-29.
15. Ajmal M, O'Sullivan M et. al, Antigrade Locked Intramedullary nailing in humeral shaft fracturers: injury, 2001,32 (9): 692-4.
16. Moran MC: Distal interlocking during intramedullary nailing of the humerus: Clin Orthop. and Related Research; 1995,317,215-218.
17. Lin J, Hou SM, Hang YS, Chao EY: Treatment of humeral shaft fractures by retrograde locked nailing. Clin Orthop; 1997, (342): 147-55.

**Author Information**

**Shabir Hassan Rawa**

Government hospital for bone and joint surgery

**Munir Farooq**

Government hospital for bone and joint surgery

**Sukhjeet Singh**

Government hospital for bone and joint surgery

**Mubashir Maqbool Wani**

Government hospital for bone and joint surgery

**Mohammad Farooq Bhat**

Government hospital for bone and joint surgery

**Anwar Hussain**

Government hospital for bone and joint surgery

**Mohammad Mussa**

Government hospital for bone and joint surgery