

Transmigration of mandibular canines: A report of four unusual Cases

Y Sisman, E Ertas, T Uysal

Citation

Y Sisman, E Ertas, T Uysal. *Transmigration of mandibular canines: A report of four unusual Cases*. The Internet Journal of Dental Science. 2008 Volume 7 Number 2.

Abstract

Pre-eruptive migration of the tooth across the midline is termed "transmigration". Failure of eruption and intraosseous migration of an impacted tooth is an unusual developmental dental anomaly that dental practitioners encounter in daily practice. These are particularly significant if the impacted tooth is a canine due to an aesthetic and functional reason. This article reports rarely seen four cases of mandibular transmigrated canines which were detected incidentally on panoramic radiographs. The presence of an over-retained mandibular deciduous canine or missing permanent canine are the most common findings of an impacted or transmigrated canine and the patient should always be investigated radiographically. With careful examinations of the radiographs, according to the position in the jaws or the pathological entity related with the tooth, most reasonable treatment plan should be decided and carried out or just be kept under periodic radiographic observation.

INTRODUCTION

Pre-eruptive migration of a tooth across the midline is termed 'transmigration'.¹ Ando et al.² used the term transmigration first, then Tarsitano et al.¹ defined the expression as the phenomenon of an unerupted mandibular canine crossing the midline. Javid³ expanded the definition to include the cases in which more than half of the tooth had passed through the midline. According to Joshi⁴ the tendency of a canine to cross the barrier of the mandibular midline suture is more important than the distance it traveled in the same side where it developed.

In the literature different reports have been documented related to the prevalence, location (left or right and maxillary or mandibular), and gender differences of transmigrated canines.^{1,2,3,4,5,6,7,8,9,10,11,12,13,14,15,16} The incidence of transmigration has been reported to be 0.1 percent.⁵ Impaction of maxillary canines have been reported to occur 20 times more;⁴ but, unlike the mandibular canine, an impacted maxillary canine has never been found migrating across the midpalatal suture to the other side of the maxilla,⁵ except one transmigration reported in a recent publication.⁶

Because tooth is generally impacted in a horizontal position under the apices of the permanent teeth, adjacent to the mandibular border or a palatally impacted canine is sometimes positioned horizontally very high in the palatal vault, close to the floor of the nasal cavity.⁵ Therefore, an

impacted tooth in the maxilla or in the mandible cannot be detected with inspection or palpation in the clinical examination, and is frequently detected on a routine periapical radiography. Therefore, while examining a patient if there is a suspicious case for example when there is an over-retained mandibular deciduous canine, the patient should always be investigated radiologically. Because an intraoral radiograph is not sufficient generally, it should be supplemented with an occlusal radiograph and especially with a dental panoramic tomogram.⁴

The purpose of this article is to report rarely seen four cases of mandibular transmigrated canines which were detected incidentally on panoramic radiographs.

CASE REPORTS

CASE 1

A 16-year old boy was referred for the complaint of a new erupting tooth between his left permanent central and lateral incisors. In the clinical examination, both mandibular left and right deciduous canines were retained in their position without any mobility (Figure 1A). Radiographic examination revealed both mandibular permanent canines to be impacted. Although, the right permanent canine crossed the midline and transmigrated to the left side, the left one was started to erupt in a transposed position between the lateral and central incisors (Figure 1B). The patient was referred to the orthodontics department and is currently under fixed

appliance therapy.

Figure 1

Figure 1A: Patient's intraoral view which shows the firm right and left deciduous canines, and it is seen that the permanent left canine started to erupt in an ectopic place.

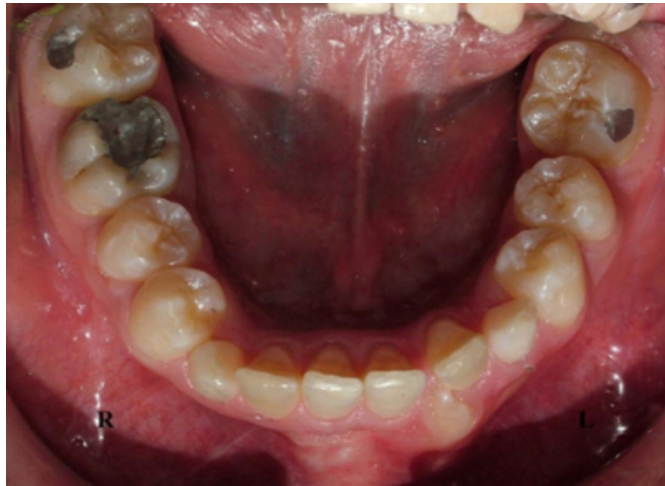
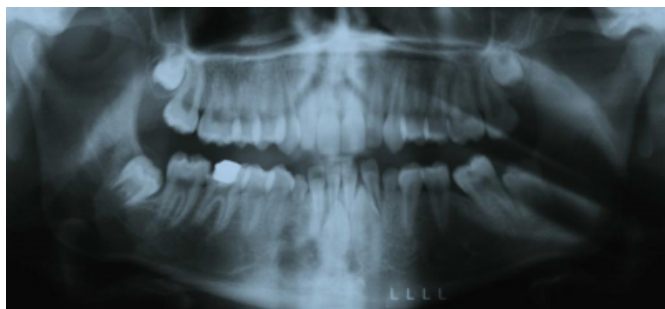
Figure 2

Figure 1B: Panoramic radiograph showing the right transmigrated canine which crossed the midline, and the transposed left canine which started to erupt.



CASE 2

A 35-year old female patient referred for evaluation of an ectopic tooth erupted between mandibular central incisors and discomfort caused by the tooth to the lip. On intraoral examination both right and left permanent canines were absent where they had to be normally in the dental arch and it was seen that the ectopic tooth was her left permanent canine which was erupted between permanent central incisors (Figure 2A). Panoramic radiograph revealed bilateral transmigrated mandibular canines (Figure 2B). The right permanent canine was impacted horizontally, below the apices of the incisors and it crossed the midline and transmigrated to the left side, and the left permanent canine was ectopically erupted between the central incisors, which could be seen clinically. The patient was referred for

extraction of her left canine, and because there is not a related pathology with the impacted right canine, it was decided that the case to be monitored with radiographic follow-up.

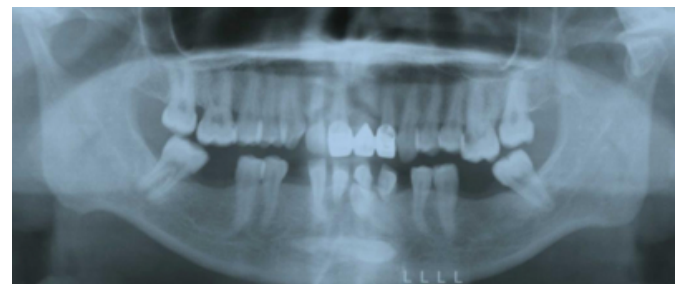
Figure 3

Figure 2A: The ectopically erupted left canine is seen from the patient's intraoral view

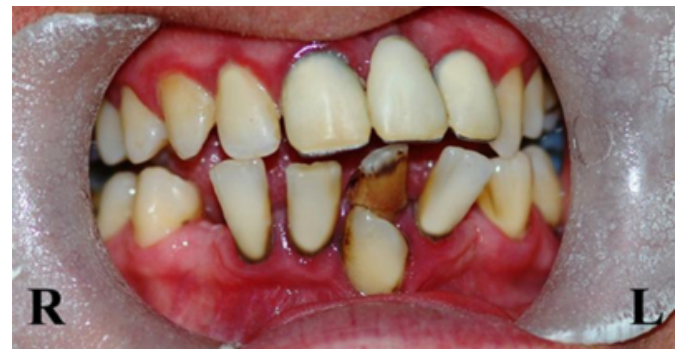

Figure 4

Figure 2B: The transmigrated right permanent canine tooth located horizontally under the apices of the anterior teeth, and the left permanent canine was erupted ectopically

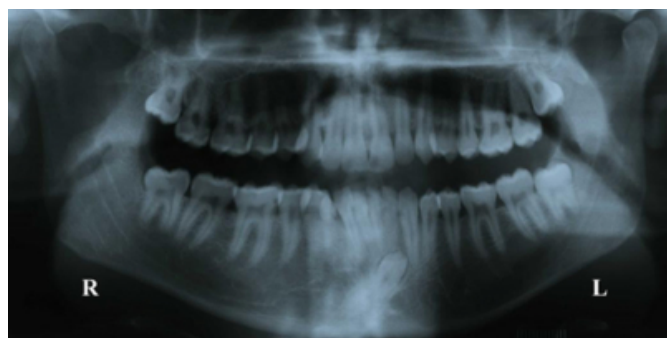


CASE 3

A 21-year old male patient was referred to our clinic for orthodontic treatment. He was complaining of misalignment of his teeth. In the clinical examination, the right deciduous canine tooth was retained. Panoramic radiography revealed that the right permanent tooth was transmigrated across the midline to the left side with its crown's direction orientated between the left lateral and canine teeth (Figure 3). First the patient was referred to an oral surgeon for extraction of impacted tooth and then he was examined in the department of orthodontics.

Figure 5

Figure 3: The right deciduous canine was over-retained and the permanent right canine tooth was transmigrated to the other side of the mandible between the apices of lateral and canine teeth.

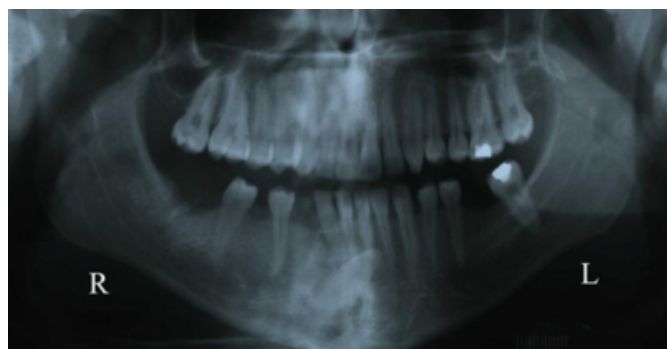


CASE 4

A 22-year old male patient was consulted to our clinic for the removal of a retained root and construction of prosthesis. Despite his young age, he had several missing teeth and in the clinical examination, we thought that the right permanent canine was one of the extracted ones. In the panoramic radiography taken before the construction of prosthesis, the right mandibular canine was seen transmigrated to the left side without any symptom to the patient and he was referred to an oral surgeon before construction of the prosthesis (Figure 4).

Figure 6

Figure 4: Right permanent canine transmigrated to the other side of the mandible



DISCUSSION

Pre-eruptive migration of a tooth across the midline is termed as transmigration.¹⁶ Although, this condition has only been reported for the mandibular canines,⁴¹² Aydin and Yilmaz⁶ reported the first case of maxillary canine transmigration in literature. In 2002, Mupparapu¹³ proposed a classification for transmigrated mandibular canines according to their migratory pattern and position in the jaw

and classified these teeth in 5 groups. This classification can be summarized as follows;

Type 1, canine is impacted mesioangularly across the midline, labial or lingual to the anterior teeth with the crown portion of the tooth crossing the midline.

Type 2, canine is horizontally impacted near the inferior border of the mandible below the apices of the incisors.

Type 3, canine has erupted either mesial or distal to the opposite canine.

Type 4, canine is horizontally impacted near the border of the mandible below the apices of either premolars or molars on the opposite side.

Type 5, canine is positioned vertically in the midline with the long axis of the tooth crossing the midline.

Type 1 is the most common type among the cases reported in the literature and type 2, type 4, type 3 and type 5 follows this, respectively.¹³ Of the 4 cases reported in the present study, patient 1 exhibited type 5 transmigration for the right permanent canine which reported as the least type in the literature. Patient 2 showed type 2 for the right and type 1 for the left canine, patient 3 exhibited type 3 and patient 4 exhibited type 1 transmigration. Besides this, patient 1 exhibited another type of anomaly for his left canine. Mandibular canine- lateral incisor transposition is another rare, inheritable dental anomaly and the simultaneous occurrence of both transmigration and transposition cases were detected in patient 1.

With the advent of the panoramic radiography, number of reports that published the prevalence of transmigrated canines are rising.⁷ Migrated canines usually remain impacted³⁸ and they are asymptomatic, or sometimes they may erupt ectopically at the midline⁹ or on the opposite side of the arch.⁴⁷ Although, most of the transmigration cases reported as unilateral, transmigration may also be bilateral.³⁴⁶¹⁰¹¹ Some authors have reported that unilateral cases occur more often and bilateral transmigration is an extremely rare event; such that in 12 articles only 18 cases of bilateral transmigration have been showed in the literature.¹³ In the present report, of the four cases, one was bilateral transmigration case.

In some recent reports, when the affected side of the jaw was compared, mandibular left canines were found to be affected more frequently compared to the right ones.¹⁴ In contrary

four out of five canines transmigrated from the right side in this report.

According to the literature, females appear to have been affected more than males.⁴ Although, there are several factors suggested for the etiology and exact mechanism of transmigration, the true reason is still not clear;⁷ and the authors could not have offered any logical reason for this fact. In the present case report although the number of cases are limited, the gender predilection mentioned above was different and three of our patients were males.

Although there is a number of factors suggested for the etiology of transmigration, the exact mechanism is still unclear; however, abnormal displacement or the rotation of the tooth bud or deviation during development are the most common explanations.³⁷ In addition to these, other local or pathologic factors were also suggested in the etiology of transmigration, such as; premature loss of primary teeth and unavoidable occupation of the space by adjacent teeth, retention of the deciduous canine, discrepancies of tooth size, unfavorable alveolar length, trauma, hereditary factors, tumors, odontomas, cysts and even a very small obstacle, such as a small root fragment, that would be sufficient to divert a tooth from its normal path of eruption.^{47,11,14} It was observed that all presented cases in this report had no associated pathologic factors.

The absence or delayed eruption of permanent mandibular canines or the over retention of a primary canine in the arch are common clinical findings of an impacted or transmigrated tooth.¹⁵ For that reason, most of the transmigrated canines are generally asymptomatic. In the presence of such findings, it should think us that there was an existence of an impacted tooth and the patient should be examined radiologically. If the misplaced mandibular canine is located near the inferior border of the mandible, generally an intraoral radiograph is not sufficient. It should be supplemented with an occlusal radiograph and especially with dental panoramic tomogram.⁴¹⁴ The mandibular canine that migrated across the mandible should be removed, if any associated pathology was exist. Otherwise, if the patient is asymptomatic, the transmigrated canine should be kept under radiographic observation and radiographs should be taken periodically to observe the movement of this teeth.¹⁴

Surgical removal, transplantation, radiographic follow-up and surgical exposure with orthodontic treatment are suggested treatment options for transmigrated mandibular

canines.⁷ If the decision is extraction, it should be kept in mind that, although the teeth have transmigrated to the other side of the midline, they still maintain their nerve supply from the originating side. That's why, it is extremely important to anesthetize the nerve on the originating side.¹⁵ Transplantation is another option if the mandibular incisors are in normal position and there is enough space for the transmigrated canine.⁷ If the impacted transmigrated canine lies labially, surgical exposure with orthodontic treatment can also be done. But there are some limitations in orthodontic treatments where it is impossible to bring the tooth back to its place that it should be, so in such cases extraction is the preferred treatment option.⁴¹⁶

References

1. Tarsitano JJ, Wooten JW, Burditt JT. Transmigration of nonerupted mandibular canines: report of cases. *J Am Dent Assoc.* 1971;82:1395-7.
2. Ando S, Aizawa K, Nakashima T, Sanka Y, Shimbo K, Kiyokawa K. Transmigration process of the impacted mandibular cuspid. *J Nihon Univ Sch Dent.* 1964;6:66-71.
3. Javid B. Transmigration of impacted mandibular cuspids. *Int J Oral Surg.* 1985;14:547-9.
4. Joshi MR. Transmigrant mandibular canines: a record of 28 cases and a retrospective review of the literature. *Angle Orthod* 2001;71:12-22.
5. Shapira Y, Kuftinec MM. Unusual intraosseous transmigration of a palatally impacted canine. *Am J Orthod Dentofacial Orthop* 2005;127:360-3.
6. Aydin U, Yilmaz HH. Transmigration of impacted canines. *Dentomaxillofac Radiol* 2003;32:198-200.
7. Camilleri S, Scerri E. Transmigration of mandibular canines-a review of the literature and a report of five cases. *Angle Orthod* 2003;73:753-62.
8. Shapira Y, Kuftinec MM. Intraosseous transmigration of mandibular canines-review of the literature and treatment options. *Compend Contin Educ Dent* 1995;16:1014-8.
9. Brezniak N, Ben-Yehuda A, Shapira Y. Unusual mandibular canine transposition: a case report. *Am J Orthod Dentofacial Orthop* 1993;104:91-4.
10. Kuftinec MM, Shapira Y, Nahlieli O. A case report: bilateral transmigration of impacted mandibular canines. *J Am Dent Assoc* 1995;126:1022-4.
11. Alaejos-Algara C, Berini-Aytes L, Gay-Escoda C. Transmigration of mandibular canines: report of six cases and review of literature. *Quintessence Int* 1998;29:395-8.
12. Shanmugasantharam P, Boon LC. Transmigration of permanent mandibular canines. Case report. *Aust Dent J* 1991;36:209-13.
13. Mupparapu M. Patterns of intra-osseous transmigration and ectopic eruption of mandibular canines: review of literature and report of nine additional cases. *Dentomaxillofac Radiol* 2002;31:355-60.
14. Buyukkurt MC, Aras MH, Caglaroglu M, Gungormus M. Transmigrant mandibular canines. *J Oral Maxillofac Surg* 2007;65:2025-9.
15. Auluck A, Nagpal A, Setty S, Pai KM, Sunny J. Transmigration of impacted mandibular canines-report of 4 cases. *J Can Dent Assoc* 2006;72:249-52.
16. Wertz RA. Treatment of transmigrated mandibular canines. *Am J Orthod Dentofacial Orthop* 1994;106:419-27.

Author Information

Yildiray Sisman, DDS, PhD

Assistant Professor and Chair, Department of Oral Diagnosis and Radiology, Faculty of Dentistry, Erciyes University

Elif Tarim Ertas, DDS

Research Assistant, Department of Oral Diagnosis and Radiology, Faculty of Dentistry, Erciyes University

Tancan Uysal, DDS, PhD

Associate Professor and Chair, Department of Orthodontics, Faculty of Dentistry, Erciyes University