

An Unusual Presentation for 6th Nerve Palsy: Isolated Chronic Sphenoid Sinusitis and Bilateral Abducens Palsy

K Ceylan, Z Kizilkaya, H Emir, E Samim

Citation

K Ceylan, Z Kizilkaya, H Emir, E Samim. *An Unusual Presentation for 6th Nerve Palsy: Isolated Chronic Sphenoid Sinusitis and Bilateral Abducens Palsy*. The Internet Journal of Otorhinolaryngology. 2006 Volume 6 Number 1.

Abstract

Isolated inflammatory involvement of the sphenoid sinus is a relatively uncommon entity. Chronic sphenoid infections may present a problem of differential diagnosis. It may be difficult to differentiate between benign and malignant lesions. The sphenoid sinus is the paranasal sinus most commonly implicated when cranial neuropathies are present. In this paper, we report a case of isolated sphenoid sinusitis in a 14-year-old boy who was presented with bilateral VIth nerve palsy. He was initially treated with parenteral antibiotherapy and systemic steroid treatment. As the abducens palsy and the sphenoiditis persisted he underwent an endoscopic sphenoidotomy. Medical treatment consisting of oral antibiotics and systemic steroids had been continued for six weeks period as the eye movements gradually recovered. Given the high prevalence of noninflammatory lesions within the sphenoid sinus, thorough preoperative evaluation is imperative.

Presented as poster in 24th ISIAN International Symposium on Infection and Allergy of the Nose, April 20-23, 2005, Sao Paulo- Brazil

INTRODUCTION

The sphenoid sinus has often been referred to as the neglected sinus because of its isolated position and difficult accessibility. Disease restricted to the sphenoid sinus is rare and often manifests with nonspecific or subtle signs and symptoms. The early and accurate diagnosis of isolated sphenoid sinus disease may thus be difficult₍₁₎.

The early occurrence of complications is explained by the anatomical location of the sinus and its proximity to the intracranial and orbital contents, to which infection may quickly spread. Due to the lack of nasal symptoms the disorder may not be seen in Ear, Nose and Throat department until an advanced stage has been reached_(2,3).

Chronic sphenoid sinusitis is usually caused by incomplete resolution of acute sinusitis, which may occur following inadequate medical management of the latter condition. The symptoms of chronic sinusitis may be more subtle and vague than for acute sinusitis. Sometimes, mild daily headaches are the only sign of disease. In other cases, asymptomatic disease progression is possible₍₁₎.

The most encountered presentation of isolated sphenoid

sinusitis is with headache and orbital symptoms. The next most frequent symptom is visual compromise, which included blurred vision and loss of visual acuity ranging from mild loss to partial blindness. Diplopia caused by involvement of the abducens nerve is the most common of cranial palsies, occurring in 6% of inflammatory cases and in 50% of neoplastic disease₍₄₎.

In this paper, we report an unusual case of isolated chronic sphenoiditis (ICS) in a 14-year-old boy who presented with bilateral VIth nerve palsy. Since the only positive diagnostic finding was isolated chronic sinusitis with computed tomographic scan (CT) and magnetic resonance imaging (MRI), a thorough evaluation of the possible causes of bilateral VIth nerve palsy was presented and differential diagnosis was reported with the literature review.

CASE REPORT

A 14-year-old boy was initially admitted to ophthalmology department with a-month history of diplopia. He was referred to our hospital as a tertiary care centre from a hospital of a neighbouring city. He had been treated with systemic antibiotics before admitting to our hospital. After detecting opacification in both sphenoid sinuses, the ophthalmology department referred the patient to our clinic. Chronic headache in the vertex area and gradual onset of diplopia and bilateral strabismus since one month were the only symptoms. On examination limitation of the lateral

deviation of both eyes were the only positive signs. For a detailed investigation, a cranial MRI and CT scan were obtained. The only positive finding was isolated sphenoid sinusitis which was confirmed by coronal CT scan.

He was initially treated with parenteral antibiotherapy and systemic steroid treatment. The medical treatment consisted of 100 mg prednisolon tapered 20 mg in every three days, intra-venous ceftriaxone 2 g per day, metronidasole 500 mg per day and xylometasoline 0.1 % spray three times a day. After a week-long medical treatment a follow-up paranasal CT scan was obtained which demonstrated that ICS was lasting. As the abducens palsy and the sphenoiditis persisted he underwent an endoscopic sphenoidotomy. Medical treatment consisting of oral antibiotics and systemic steroids had been continued for six weeks period as the eye movements gradually recovered. There was no signs of recurrence in 2 years of follow-up.

Figure 1

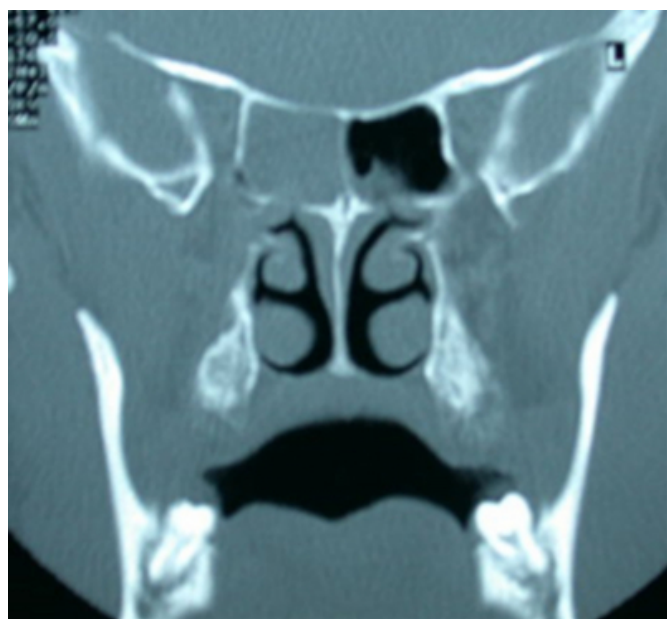

Figure 2

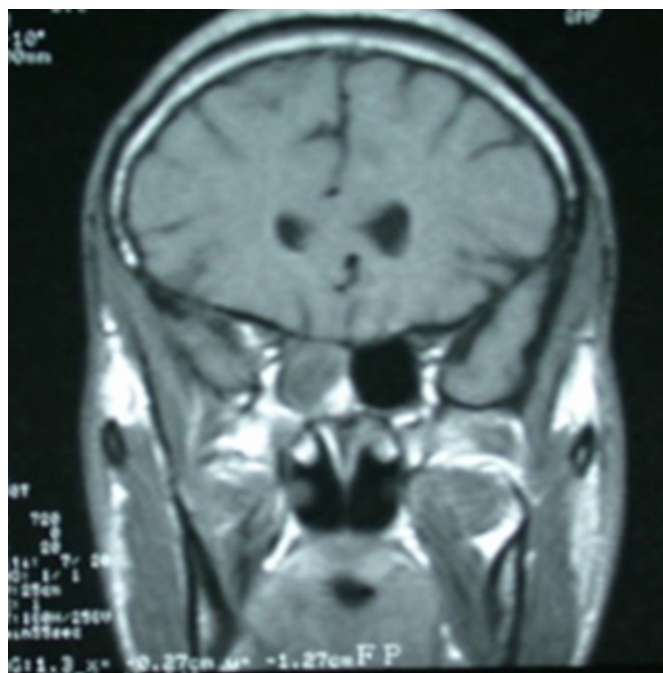
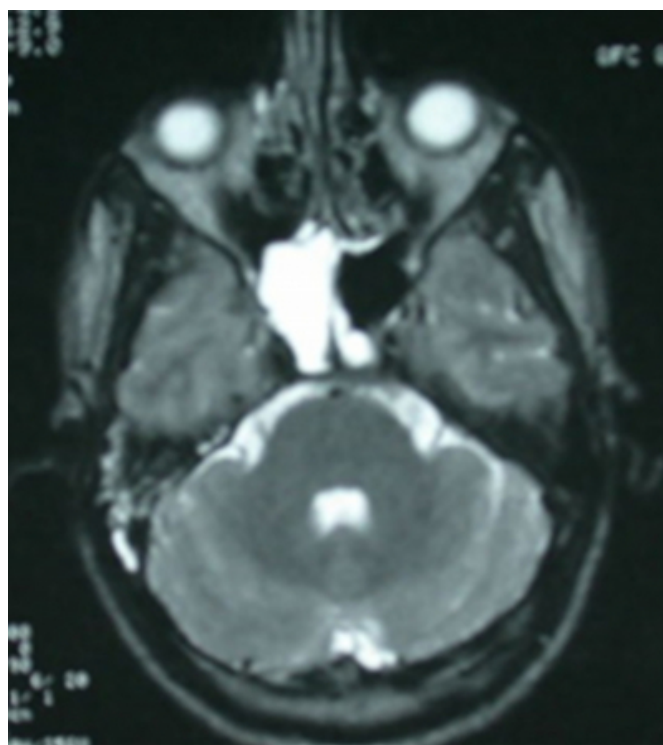


Figure 3



DISCUSSION

The incidence of sphenoid involvement in sinus disease has been shown to have decreased from up to 33% in preantibiotic era to 8% in a more recent series. The complications arising from sphenoid infections are

accounted for the proximity of the sinus to important anatomical structures. The duramater, the pituitary gland, the sphenopalatine artery and ganglion and the pterygoid canal and its nerve are closely related. The cavernous sinus is an immediate lateral relation and conveys the internal carotid artery and cranial nerves III, IV, Va, Vb, and VI. In an anterolateral direction are the superior orbital fissure and the optic nerve⁽³⁾.

The intra-cranial structures, orbital contents, or both may be affected by complications. Meningitis is the most frequently encountered complication. Cranial nerves III-VI may be affected by the disease, whereas sixth nerve is the most frequently affected cranial nerve probably due to its medial location in the cavernous sinus^(5,6).

In 1979, Fuji et al. investigated that, in 78% of the cadavers, which he examined, a bony wall between the optic nerve and sphenoid sinus was found to be thinner than 0.5 mm and also in 8% of cadavers there were no bony structure between the sphenoid sinus and internal carotid artery⁽⁷⁾. He concluded that anatomic relation of the sphenoid sinus with the vital structures and variability of the thickness of the bony wall might result in the intracranial spread of the infection, which might cause serious problems⁽⁸⁾.

Involvement of the sixth cranial nerve in isolation is attributed to progressive thrombophlebitis affecting the inferior petrosal sinus. The VIth nerve is closely related to this structure even to the extent of penetrating it, and damage may occur as it passes anteriorly in the region of petrous apex⁽³⁾.

Acute sphenoid sinusitis is often characterized by recent onset of severe pain, aching or dull in quality, in the retro-orbital area, the occiput, or the vertex. There may be associated nasal congestion and heavy feeling localized to the centre of the head. Purulent material can be secreted and swallowed through the nasopharynx and can lead to complaints of foul taste. Loss of appetite and decreased sense of smell can also occur. Chronic sphenoid sinusitis is usually caused by incomplete resolution of acute sinusitis, which may occur following inadequate medical management of the latter condition. The symptoms of chronic sinusitis may be more subtle and vague than for acute sinusitis. Sometimes, mild daily headaches are the only sign of disease. In other cases, asymptomatic disease progression is possible. Incidental finding of opacification of the sphenoid sinus on CT imaging may be the first indication of chronic

sphenoid sinusitis⁽¹⁾. Our patient admitted to ophthalmology department with diplopia and difficulty in eye movements. There were no other sinus related complaints. The ICS was diagnosed only when a plain CT scan was obtained. ICS is very rare when compared with its acute form and this is the first case reported in literature with the simultaneous occurrence of bilateral VIth nerve palsy.

Predisposing factors are stated to include infected water entry into the sinus during swimming, cocaine abuse, steroid ingestion, immunosuppressive therapy, craniofacial radiotherapy, fractures, diabetes mellitus, obstruction of the sinus ostium and maxillofacial trauma. However none of these factors could be found in our patient's history^(3,6,9).

The transnasal surgical approaches to isolated sphenoid lesions are endoscopic transnasal, endoscopic transtethmoid, transseptal and endoscopic pterygoid fossa approaches⁽¹⁰⁾. We preferred an endoscopic transnasal sphenoidotomy as the surgical intervention. In our case, as the exposure was not optimal we performed sphenoidotomy with partial middle turbinectomy. Stankiewicz mentioned that isolated sphenoiditis can be effectively treated by partial removal of the inferior part of the middle turbinate and direct entrance into the sphenoid sinus through the anterior sinus wall⁽¹¹⁾. Kieff and Busaba supported this technique which could provide shorter surgical times, faster healing, and fewer complications; and they argued that osteomeatal complex surgery or ethmoidectomy is not necessary for the patients with isolated sphenoid inflammatory or infectious disease⁽¹²⁾.

The diagnosis of ICS is based on history, physical examination, including nasal endoscopy, and radiological studies. This case emphasizes the diagnostic challenge of sphenoid sinusitis, the high index of suspicion, unusual course of the disease with bilateral abducens palsy and subsequent need for early and aggressive medical and surgical therapy.

CORRESPONDENCE TO

Kursat Ceylan 4. Sok. 22/27 Sogutozu 06520 Ankara
TURKEY e-mail: ceylankursat@ttnet.net.tr GSM:
+905323354797

References

1. Grillone GA, Kasznica P. Isolated sphenoid sinus disease. *Otolaryngol Clin N Am* 2004; 37: 435-51.
2. Dale BAB, Mackenzie IJ. The complications of sphenoid sinusitis. *J Laryngol Otol* 1983; 97: 661-70.

3. Deans JAJ, Welch AR. Acute isolated sphenoid sinusitis: a disease with complications. *J Laryngol Otol* 1991; 105: 1072-74.
4. Lawson W, Reino A. Isolated sphenoid sinus disease: an analysis of 132 cases. *Laryngoscope* 1997; 107(12): 1590-5.
5. Sethi DS. Isolated sphenoid lesions: diagnosis and management. *Otolaryngol Head Neck Surg* 1999; 120: 730-36.
6. Ada M, Kaytaz A, Tuksan K, Guvenc MG, Selcuk H. Isolated sphenoid sinusitis presenting with unilateral VIth nerve palsy. *Int J Pediatr Otorhinolaryngol* 2004; 68: 507-10.
7. Fuji K, Chambers SM, Rhoton AF. Neurovascular relationships of the sphenoid sinus: a microsurgical study. *J Neurosurg* 1979; 50:31-9.
8. Unlu HH, Aslan A, Goktan C, Egrilmez M. The intracranial complication of acute isolated sphenoid sinusitis. *Auris Nasus Larynx* 2002; 29: 69-71.
9. Oruckaptan HH, Akdemir P, Ozgen T. Isolated sphenoid sinus abscess: clinical and radiological failure in preoperative diagnosis. Case report and review of the literature. *Surg Neurol* 2000; 53: 174-7.
10. Martin TJ, Smith TL, Smith MM, Loehrl TA. Evaluation and surgical management of isolated sphenoid sinus disease. *Arch Otolaryngol Head Neck Surg* 2002; 128: 1413-19.
11. Stankiewicz JA. Sphenoid sinus mucocele. *Arch Otolaryngol Head Neck Surg* 1989; 115: 735-40.
12. Kieff DA, Busaba N. Treatment of isolated sphenoid sinus inflammatory disease by endoscopic sphenoidotomy without ethmoidectomy. *Laryngoscope* 2002; 112: 2186-8.

Author Information

Kursat Ceylan, M.D.

E.N.T. Department, Ministry of Health Ankara Training and Research Hospital

Zeynep Kizilkaya, M.D.

E.N.T. Department, Ministry of Health Ankara Training and Research Hospital

Hatice Emir, M.D.

E.N.T. Department, Ministry of Health Ankara Training and Research Hospital

Erdal Samim, M.D.

E.N.T. Department, Ministry of Health Ankara Training and Research Hospital