

Unilateral Poliosis And Vitiligo: A Case Report

H Foyaca-Sibat, L Ibañez-Valdés

Citation

H Foyaca-Sibat, L Ibañez-Valdés. *Unilateral Poliosis And Vitiligo: A Case Report*. The Internet Journal of Neurology. 2003 Volume 3 Number 1.

Abstract

We report a 34-year old patient presenting with unilateral poliosis, vitiligo, epilepsy, and pseudoseizures without other characteristic signs of Vogt-Koyanagi-Harada syndrome or Alezzandrini syndrome. Similar combinations have not been reported to medical literature.

INTRODUCTION

In clinical practice, patients presenting with decolouration of the skin, eyebrow, eyelashes, alopecia, chronic uveitis, and meningoencephalitis are diagnosed as Vogt-Koyanagi-Harada (VKHS) syndrome.¹ In 1959, Arturo Alberto Alezzandrini, (Argentine ophthalmologist) reported a patient presenting with vitiligo, poliosis, unilateral pigmentary retinitis and hearing disturbances.² Another two patients were studied two years after their first report,³ and five years later another 3 patients with unilateral vitiligo, poliosis and ipsilateral retinal degeneration plus hypoacusia were described.⁴ Later, several patients presenting similar clinical features have been described.^{5 6} Since then this combination of clinical features is known as Alezzandrini Syndrome (AS) and a small number of patients have been reported.^{7 8} Most of the patients diagnosed as VKHS reported in the medical literature showed bilateral poliosis, chronic uveitis, vitiligo and neurological manifestations, however unilateral manifestations of skin and hair decolouration plus retinal disease are named as AS preferably. We report a patient with unilateral poliosis and alopecia without ophthalmological or hearing problems, refractory epileptic seizures and pseudo seizures.

CASE REPORT

A 34-year-old lady was referred to Neurology Clinic of the Nelson Mandela Academic Hospital, Umtata, South Africa because her uncontrolled seizures. She began to present fits in 1984 and those events were described as palpitations followed by blurred vision and jerking movements of the right arm for a few seconds followed by generalized tonic movements all over the body and loss of consciousness as well as urinary incontinence lasting 10 minutes

approximately. It occurred at least once a day and after the seizure she experienced a generalized headache. She was on Carbamazepine 200 mg orally three times a day with very good respond in spite of defaulting treatment several times due to different reasons including unavailability of medications at the rural clinic. Typical pseudoseizures (PS) characterized by pedalling movements of the lower limb, stereotype position of the upper limbs, with normal pupils superficial reflexes, these PS never happened when the patient remained alone and associated injuries such as biting of the tongue or post-ictal manifestations were not found. Three week prior to these seizures she noticed whitish discolouration of eyebrows, eyelashes and regimentation of the skin in her face. A traditional healer treated her unsuccessfully near her villages. On general examination, apart from whitening of the eyebrow and eyelashes on the right side, patchy loss of colour on the skin in the right frontal region and some areas of hyper pigmentation in the same region identified as veiling were seen (Figure 1 and 2)

Figure 1

Figure 1: Shows integumentary changes such as poliosis, alopecia and vitiligo (Informed consent is obtained)

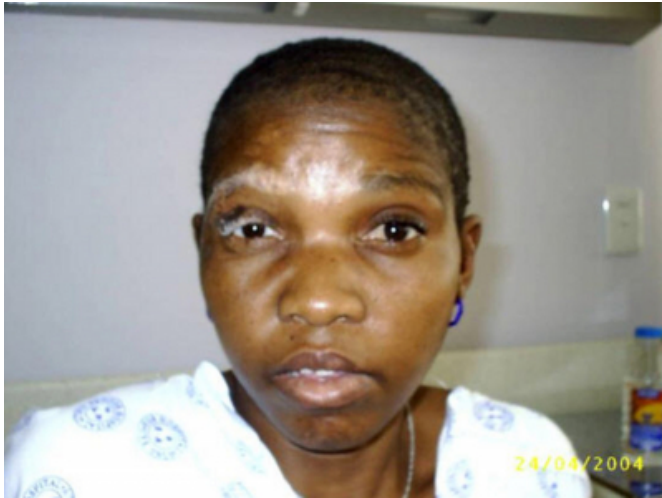
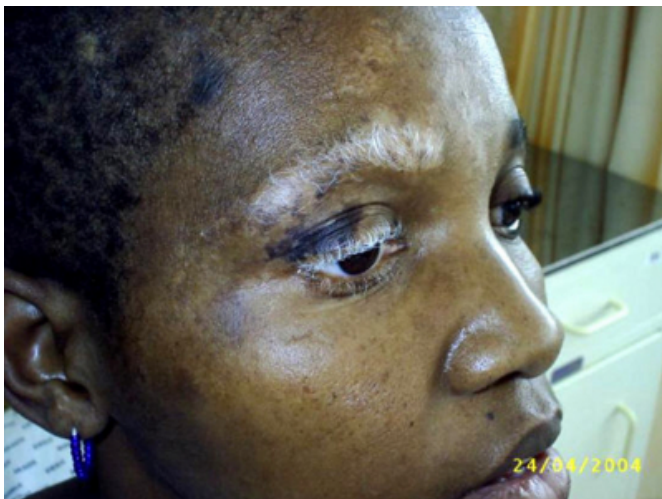

Figure 2

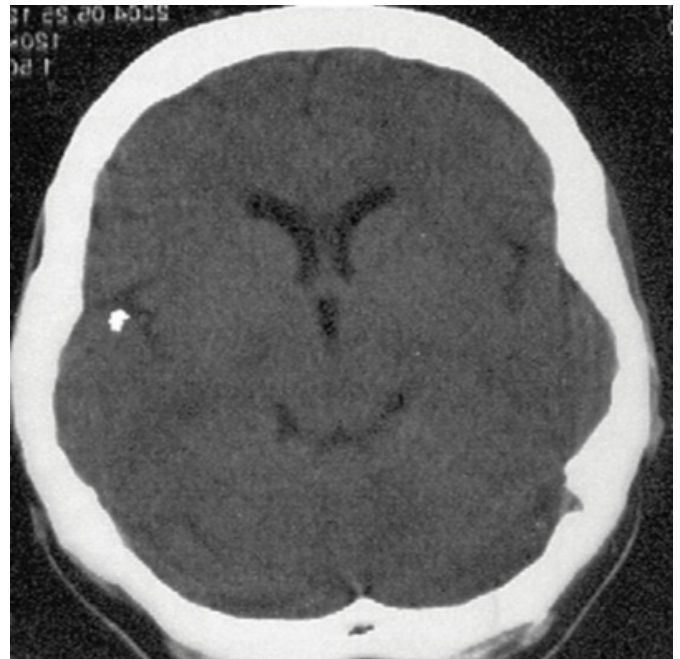
Figure 2: Close up of the same patient for a better view of poliosis and facial vitiligo (Informed consent is obtained)



No other abnormal signs were observed; ophthalmologic and audiometric investigations showed no abnormalities. All laboratory investigations were normal and CT Scan of the brain showed mild generalized brain oedema and small irregular calcification on the left temporal lobe that resemble a calcified tuberculoma (Figure 3)

Figure 3

Figure 3: CT Scan of the brain showing a 7mm calcified tuberculoma on the right cerebral hemisphere. IV contrast did not show other abnormalities.



COMMENTS

VKHS is a cell-mediated autoimmune disease directed against melanocytes characterized by multistemic dysfunction associated to several human leukocyte antigen (HLA) more commonly seen in black population worldwide without history of ocular trauma and an associated iridocyclitis, posterior uveitis and retinal detachment, hearing problems, meningeal signs, other neurologic problems, and pleocytosis of the cerebrovascular fluid, its pathogenesis is not well known but clinical manifestation kept its personality. Inflammatory process and loss of melanocytes arising from the neural crest can cause typical manifestation of the skin,

inner ear, retina, and uvea as seen in VKHS. As mentioned before, AS syndrome is characterized by unilateral tapetoretinal (retinal pigmented epithelia) degeneration with the ipsilateral appearance of facial vitiligo and poliosis but in our patient retinal abnormalities were not confirmed and the only neurological disorder was epilepsy and PS.

As we reported before: PS are sudden changes in behaviour that resemble an epileptic attack but lack organic cause and are also known as conversion seizures, dissociative seizures, hysterical seizures, psychogenic seizures, and nonepileptic seizures. PS are often misdiagnosed and represent the opposite end of the spectrum from seizures that mimic

psychiatric disorders without organic cause and an expected EEG change. Accurately distinguishing PS from EP and other illnesses is difficult because of the breadth and overlap of symptoms seen in each condition and because of the frequent co-occurrence of PS and epilepsy. Patients presenting with PS frequently report a history of physical and sexual abuse, and traumatic experience is considered part of the mechanism for producing dissociation and may be a manifestation of dissociative disorders, especially when a history of sexual or physical abuse is documented. The above-mentioned mechanism was also valid for our patient. We considered this as a coincidental event not necessarily related with AS. This combination of unilateral poliosis, vitiligo, epilepsy and PS has not been previously reported in the medical literature. At the present moment, we could not predict if our patient will develop retinal disturbance and to be classified as a classic AS but if this will happen we will communicate it accordingly.

References

1. Arnold HL, Odom RB, James WD. *Andrew's Diseases of the Skin*. 8th ed. Philadelphia: Saunders Co, 1990.
2. Casala AM, Alezzandrini AA: Vitiligo, poliosis unilateral con retinitis pigmentaria y hypoacusia. *Arch Argent Dermatol* 1959; 9: 449-455
3. Cremona AC, Alezzandrini AA, Casala AM. Vitiligo degeneration macular unilateral. *Arch Ophthal B Aires* 1961;36:102-106.
4. Alezzandrini AA. Manifestations unilaterales de dégénérence tapéto-retinienne, de vitiligo, de poliose de cheveux blancs et d'hypoacusie. *Ophthalmologica* 1964;174:409-419
5. Mark D, Hoffman MD, Dudley C (MD Chicago, Illinois). Suspected Alezzandrini's syndrome in a diabetic patient with unilateral retinal detachment. *Am Acad Dermatol* 1992;26:496-7.
6. Ortonne JP, Mosher DB, Fitzpatrick TB. Miscellaneous hypomelanosis. In: Ortonne JP, et al (eds): *Vitiligo and Other Hypomelanosis of Hair and Skin*. New York: Plenum Medical Book Co, 1983.
7. Hoffman MD, Dudley C: Suspected Alezzandrini syndrome in a diabetic patient with unilateral retinal detachment and ipsilateral vitiligo and poliosis. *J Am Acad Dermatol* 1992 Mar; 26(3 Pt 2): 496-497
8. Shamsadini S, Meshkat MR, Mozzafarinia K: Bilateral retinal detachment in Alezzandrini's syndrome. *Int J Dermatol* 1994 Dec; 33(12): 885-886
9. Foyaca-Sibat H., Ibañez-Valdés LdeF: Pseudoseizures and epilepsy in neurocysticercosis. *Electron J Biomed* 2003;1(2):79-87 Available online at: <http://biomed.uninet.edu/2003/n2/foyaca.html>

Author Information

H. Foyaca-Sibat

Nelson Mandela Academic Hospital, University of Transkei

LdeF Ibañez-Valdés

Nelson Mandela Academic Hospital, University of Transkei