

Neglected Retrosternal Goitre

Z Matar, M Al Awami, A Mohamed, M Abukhater

Citation

Z Matar, M Al Awami, A Mohamed, M Abukhater. *Neglected Retrosternal Goitre*. The Internet Journal of Surgery. 2007 Volume 16 Number 1.

Abstract

Retrosternal goiters may remain silent or present with symptoms of obstruction to the airways and/or difficulty in swallowing. Surgical treatment can result in complete cure. Partial sternotomy is needed for accessing the retrosternal gland. We report a case of retrosternal goiter, which was missed during initial thyroidectomy and had grown to a huge size causing airway obstructive symptoms and treated by surgical intervention.

INTRODUCTION

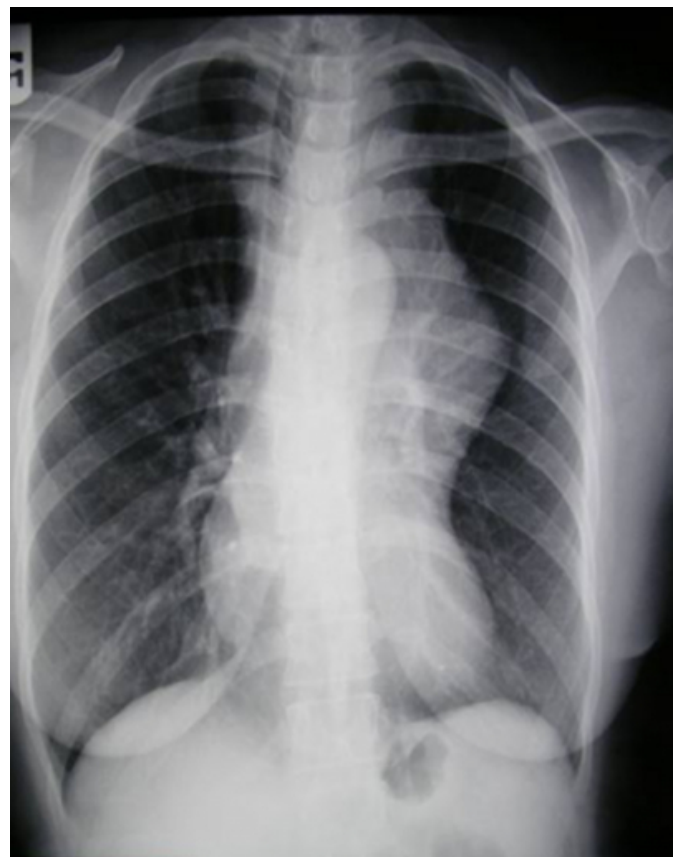
Retrosternal goiter is common with incidence of 3 to 20 per cent in thyroidectomy patients. Patients develop symptoms due to increase in size of the gland producing pressure symptoms. Malignancy may occur rarely. Preoperative diagnosis is easy and straightforward. Surgical excision is indicated in all cases.

CASE REPORT

A 45-year-old woman presented with history of recurrent cough and wheezing diagnosed as bronchial asthma for which she was put on bronchodilators. She gave history of thyroid surgery 8 years earlier for benign multinodular goiter. She had no esophageal obstructive symptoms. The chest X-ray showed a left anterior mediastinal mass with marked shifting of the trachea to the right side (Figure 1).

Figure 1

Figure 1: Plain chest X- ray showing large left lobe mass in the mediastinum



The CT scan confirmed the chest X-ray findings and showed the relation of the mass to the great vessels (Figure 2).

Figure 2: CT of the chest showing the relation of the mass to mediastinal structures

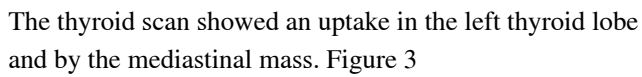
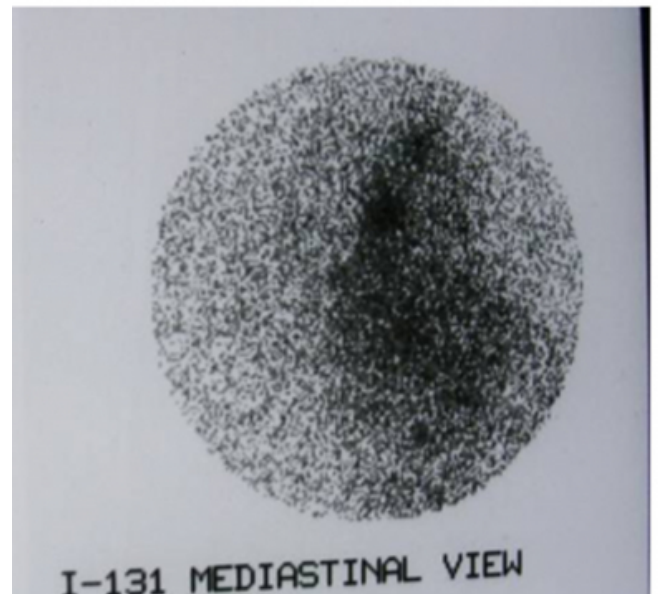


Figure 3

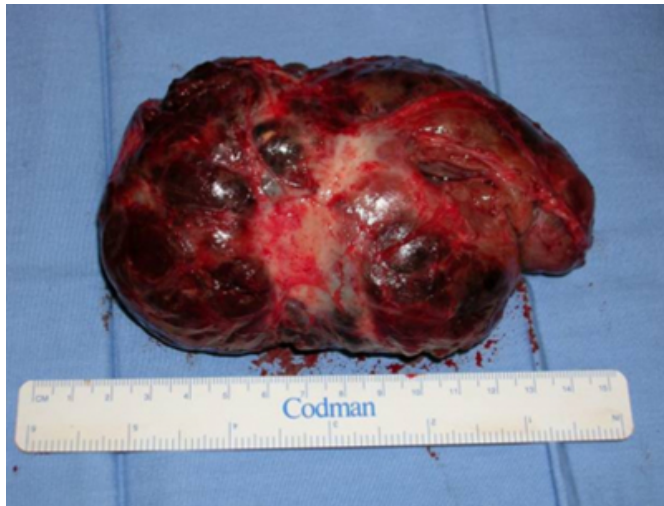

In view of the above symptoms and investigations, the patient was taken for surgery that was started with a neck collar incision. It was obvious that the patient had had right lobectomy and excision of the isthmus at the first surgery. The left lobe and the retrosternal extension on both sides were left intact. Because of severe adhesions between the left lobe and the infrahyoid muscles, and the huge size of the

goiter, we proceeded with upper partial median sternotomy. The goiter was difficult to dissect but was removed in toto (Figure 4).

Figure 4

Figure 4: Posterior surface of the retrosternal component, showing the tracheal indentation



We were able to identify the left upper parathyroid gland which was preserved.

The patient did well in the post-operative period apart from a transient hypocalcaemia. Her bronchial asthma symptoms disappeared on follow-up. The histopathology confirmed the diagnosis of retrosternal goiter with no malignant changes.

DISCUSSION

Retrosternal goiter is defined as any goiter in which at least 50 per cent of the thyroid resides below the level of the thoracic inlet¹. The incidence of retrosternal goiter varies from 3 to 20 per cent with respect to thyroidectomy patients.

During past decades, a considerable and debated speculation about the classification of intrathoracic goiter was more and more developing. One of the most reliable classifications is the one considering the degree of the intrathoracic extension of the thyroid gland: i) largely intrathoracic (more than 80%), ii) partially intrathoracic (more

than 50%, but less than 80%), and iii) sub-sternal goiter (more than 50% remaining in the neck². Substernal goiter may exist in the absence of symptoms or signs³. The most frequent symptoms are respiratory compromise, thyrotoxicosis, dysphagia, or malignancy which can develop in long-standing goiters⁴. Unrecognized mediastinal goiters can produce asthma-like symptoms, which may lead to late diagnosis or misdiagnosis and deficient treatment⁵.

Diagnosis is easily done by physical examination, chest X-ray and thyroid scintigraphy. Computed tomography may be of help⁶. The presence of a substernal goiter should be considered an indication for resection for the risk of acute respiratory distress, the risk of malignancy, and low surgical morbidity⁷. General anesthesia with endotracheal intubation is preferred when operating for intrathoracic goiter. Tracheal intubation with small caliber tubes is nearly always possible in patients with tracheal compression⁸.

In our patient, the operation was started with a cervical collar incision. The patient was prepared for a sternal split. Lateral thoracotomy may be necessary only when the mass is situated in the posterior mediastinum. Surgical treatment⁹: Primary intrathoracic goiter should be approached via thoracotomy because of the independent vascular supply. As secondary intrathoracic goiters are supplied by vascular pedicles arising from the inferior thyroid artery, a cervical collar incision is preferable to start with. In the event of significant mediastinal bleeding, which is difficult to control from a cervical incision, a T-shaped incision with partial or full median sternotomy or even thoracotomy can be performed¹⁰. Median sternotomy does not increase morbidity or mortality. Specific indications for more liberal use of sternotomy extension of a collar incision are proposed for the management of substernal and intrathoracic goiters¹¹.

The operative morbidity in patients operated for substernal goiter varies from one series to another. Goudet and his colleagues found that there is no significant difference in surgical morbidity between thyroidectomies for substernal goiter and cervical goiters when patients are operated in specialized centers¹².

Parathyroid devascularization is more common with resection of a substernal goiter and autotransplantation can prevent permanent hypoparathyroidism¹³.

Our patient had smooth recovery apart from transient hypocalcaemia.

CONCLUSION

There are patients who present with retrosternal goiter which should be suspected in all cases of large cervical goiter. Diagnosis can be established by careful clinical examination supplemented by plain chest X-ray. All retrosternal goiters should be excised based on risk of acute respiratory distress, risk of malignancy, and low surgical morbidity. Sternotomy is seldom required.

CORRESPONDENCE TO

Dr. ZAFER SAID MATAR FACHARZT, ARAB BOARD,
FACS DEPARTMENT OF SURGICAL SPECIALTIES
KING FAHAD MEDICAL CITY –RIYADH KINGDOM
OF SAUDI ARABIA e-mail: zafer_s_m@hotmail.com

References

1. Moron JC, Singer JA, Sardi A. Retrosternal goiter: a six-year institutional review. *Am Surg.* 1998;64:889-93.
2. Hili JL, Mayer G, Carini L, Cantelli G, Modigliani U. Cervico-mediastinal goitre. Analysis of preoperative clinical symptoms. *Minerva Chir.* 1993;48:533-7.
3. Katlic MR, Grillo HC, Wang CA. Substernal goiter. Analysis of 80 patients from Massachusetts General Hospital. *Am J Surg.* 1985;149:283-7.
4. Siragusa G, Gelarda E, Geraci G, Albanese L, Di Pace G. Cervico-mediastinal goiter. Our experience. *Minerva Chir.* 1999;54:225-9.
5. Vadasz P, Kotsis L. Surgical aspects of 175 mediastinal goiters. *Eur J Cardiothorac Surg.* 1998;14:393-7.
6. Daou R. Substernal goiter. *Chirurgie.* 1991;117:43-7; discussion 48.
7. Shai SE, Chen CY, Hsu CP, Hsia JY, Yang SS, Chuang CY, Wang PY. Surgical management of substernal goiter. *J Formos Med Assoc.* 2000;99:827-32.
8. Maruotti RA, Zannini P, Viani MP, Voci C, Pezzuoli G. Surgical treatment of substernal goiters. *Int Surg.* 1991;76:12-7.
9. Lamke LO, Bergdahl L, Lamke B. Intrathoracic goitre: a review of 29 cases. *Acta Chir Scand.* 1979;145:83-6.
10. Kaya S, Tastepe I, Kaptanoglu M, Yuksel M, Topcu S, Cetin G. Management of intrathoracic goitre. *Scand J Thorac Cardiovasc Surg.* 1994;28:85-9.
11. Sand ME, Laws HL, McElvein RB. Substernal and intrathoracic goiter. Reconsideration of surgical approach. *Am Surg.* 1983;49:196-202.
12. Goudet P, Ragois P, Guergah M, Cougard P. Specific morbidity of substernal goiters. A comparative study with a matched series of cervical goiters. *Ann Chir.* 1996;50:913-7.
13. Hedayati N, McHenry CR. The clinical presentation and operative management of nodular and diffuse substernal thyroid disease. *Am Surg.* 2002;68:245-51; discussion 251-2.

Author Information

Zafer Said Matar, FACHART, ARAB BOARD, FACS

Department Of Surgical Specialties, King Fahad Medical City

Majed S.M. Al Awami, MD, FACS

Department Of Surgical Specialties, King Fahad Medical City

Abbas AR Mohamed, MBBS, FRCSI, FICS, FICS

Department Of Surgical Specialties, King Fahad Medical City

Muhammad Abukhater, MBBS, FRCSI

Department Of Surgical Specialties, King Fahad Medical City