

Periadrenal Bronchogenic Cyst with Intracystic Milk of Calcium

S Park, S Hwang

Citation

S Park, S Hwang. *Periadrenal Bronchogenic Cyst with Intracystic Milk of Calcium*. The Internet Journal of Radiology. 2008 Volume 10 Number 2.

Abstract

Retroperitoneal bronchogenic cyst containing intracystic milk of calcium is extremely rare and only one case of retroperitoneal bronchogenic cyst with a small amount of milk of calcium has ever been reported. We report a case of periadrenal retroperitoneal bronchogenic cyst with intracystic milk of calcium and its serial change into the nodular cyst wall calcifications over the course of two year. The patient was treated with laparoscopic resection of retroperitoneal bronchogenic cyst.

INTRODUCTION

Bronchogenic cysts are foregut-derived, developmental anomalies most commonly discovered in the mediastinum and rarely in the retroperitoneum¹. The presence of calcification in the wall of a retroperitoneal cyst is not uncommon, but the presence of milk of calcium within the cyst is extremely rare²³. Although there have been reports describing milk of calcium within mediastinal bronchogenic cysts¹⁴⁵⁶, there has only been one case reported of a retroperitoneal bronchogenic cyst containing a minimal amount of milk of calcium². We report a case of periadrenal retroperitoneal bronchogenic cyst with intracystic milk of calcium and its serial change into the nodular cyst wall calcifications over the course of two year. The patient was treated with laparoscopic resection of retroperitoneal bronchogenic cyst and left adrenal gland.

CASE REPORT

A 62-year-old woman underwent a routine ultrasound examination during which a hypoechoic, retroperitoneal mass was detected above the left kidney. For further evaluation of the left retroperitoneal mass, the patient was referred to our hospital. She had previously been healthy and had no specific history of illness. The physical examination and routine laboratory exams were within normal limits. Unenhanced computed tomography (CT) images revealed an ovoid, hypoattenuating, 10 x 9 x 6-cm mass located in the suprarenal retroperitoneum adjacent to the left adrenal gland. There was density difference between the dependant and non-dependant portions of the cystic lesion. The measured attenuation value of the higher density fluid was

approximately 180 HU, thus suggesting intracystic hemorrhage or milk of calcium. On the initial CT, no calcifications were found in the cyst wall. After contrast enhancement, CT demonstrated a thin-walled cyst with no contrast-enhanced nodule or intracystic septations (Figure 1). The retroperitoneal cyst displaced the left adrenal gland anteroinferiorly. As the patient did not complain of any specific symptoms related to the retroperitoneal cyst, clinical observation and a follow-up imaging study recommended.

Two years later, follow-up CT of the abdomen showed little interval change in size or shape of the pre-existing retroperitoneal cyst (Figure 2). However, high-density fluid within the cystic lesion had become denser, and fine, nodular calcifications were found in the cyst wall. Laparoscopic resection of the left retroperitoneal cyst and the left adrenal gland was performed. On the gross specimen, yellow to greenish intracystic fluid and calcifications were found in the cyst wall. There were no areas of dentigerous material, bone, hair or sebaceous material. Histologic findings confirmed bronchogenic cyst lined with pseudostratified, respiratory epithelium (Figure 3). The patient's postoperative course was uneventful, and she was discharged eight days after surgery.

DISCUSSION

Bronchogenic cysts are rarely occurring congenital cystic lesions which are thought to arise from abnormal budding of the ventral foregut which subsequently differentiates into a cystic lesion filled with protein-rich fluid⁷⁸. Yang et al. described an embryologic explanation for the occurrence of

abdominal bronchogenic cyst₉. Early in embryonic life, the abdominal and thoracic cavities are connected by the pericardioperitoneal canal. The pleuroperitoneal membranes which form the future diaphragm can close and aberrant lung buds from the primitive foregut can develop between the 26 [[th]] and 40 [[th]] days of gestation. These aberrant lung buds can be pinched off and entrapped, and subsequently migrated into the abdomen before fusion of the diaphragm components. On this embryologic basis, although most bronchogenic cysts are found most frequently in the posterior mediastinum adjacent to the tracheal bifurcation, they can occasionally occur in the subdiaphragmatic area. Menike et al. reviewed 38 cases of subdiaphragmatic bronchogenic cysts and reported that 82% and 63 % of them were located in left side of the body and retroperitoneal lesions, respectively₁₀. Because of the rarity of retroperitoneal bronchogenic cysts, their imaging features have seldom been described₁₁.

Bronchogenic cysts may be spherical elliptical, or lobulated and are usually unilocular₉. The fluid within them is usually a mixture of water and proteinaceous mucus₁, however, previously descriptions of this intracystic fluid range from a thin, watery liquid to hemorrhagic fluid to a very viscous, mucoid material. Therefore, the variable nature of the intracystic fluid of bronchogenic cysts has been responsible for the variable attenuation on CT and the signal intensity characteristics of cyst on MR images, as seen in various studies₇₁₁. Histologically, bronchogenic cysts are lined by ciliated, mucous-secreting, respiratory columnar epithelium, and protein-rich mucus fluid may cause intracystic fluid with CT attenuation values above 20 HU₁₂. For this reason, a bronchogenic cyst may be misinterpreted as a solid mass on CT₁₂₁₃. The presence of mucus material within a bronchogenic cyst having soft tissue attenuation on CT, can be differentiated from calcification on the basis of MR findings of the high signal intensity of intracystic fluid similar with that of cerebrospinal fluid on T2-weighted images and the isointense intracystic fluid comparing to skeletal muscles on T1-weighted images₁₁₄. Several investigators have analyzed the intracystic fluid of bronchogenic cysts and have suggested the calcium oxalate component of the cyst fluid as a major factor contributing to the higher attenuation of intracystic fluid on CT₁₅₁₆.

McAdams et al. reported that cyst wall calcification and milk of calcium were seen, retrospectively, in six (10%) and two (3%) of 62 cases of supradiaphragmatic bronchogenic cysts₁. The calcification was located peripherally in the cyst wall

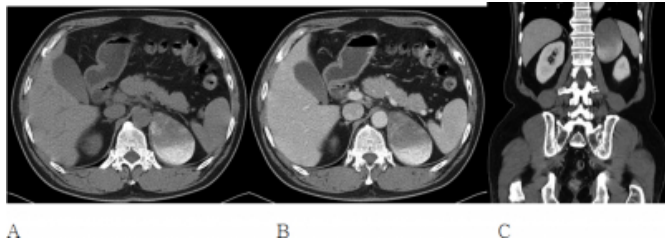
and was punctate and discontinuous in nature. Although several reports have described the presence of milk of calcium within bronchogenic cysts₁₅₆₁₇, there has been only one report of a retroperitoneal bronchogenic cyst containing milk of calcium₂. In our case, the retroperitoneal bronchogenic cyst was initially presumed to be a hemorrhagic cyst or a cyst containing milk of calcium because of the e lower density fluid-higher density fluid level of the intracystic fluid on the initial CT. Interestingly, the milk of calcium within the retroperitoneal bronchogenic cyst in our patient appeared to be condensed in the dependant portion of the cyst and precipitated in the cyst wall. Finally, nodular cyst wall calcifications developed during the one-year follow-up period, thereby suggesting that the previously reported, nodular, discontinuous cyst wall calcifications may be originated from milk of calcium fluid within the bronchogenic cyst.

Most bronchogenic cysts are less than 5cm in diameter and are detected incidentally with no specific patient's symptom. Possible complications related to bronchogenic cysts include extrinsic mass effect to the adjacent organ and perforation or secondary infection₃₁₁. The treatment of asymptomatic bronchogenic cysts remains a controversial topic. As most bronchogenic cysts are benign and remain asymptomatic, the argument has therefore been made that intervention is not warranted as long as the cyst is not causing problems₁₈, although carcinomas and fibrosarcomas reported to arise from benign-appearing bronchogenic cysts₁₉. In our patient, there were no symptoms related to the presence of the retroperitoneal bronchogenic cyst. As our patient decided to undergo laparoscopic resection of the retroperitoneal bronchogenic cyst, this was performed without any complications.

In conclusion, a thin-walled, retroperitoneal cystic lesion containing characteristic milk of calcium and/or nodular cyst wall calcifications, raises the possibility of its being a retroperitoneal bronchogenic cyst despite its rare occurrence. Over time, the milk of calcium fluid within a bronchogenic cyst can be condensed and precipitated to the cyst wall, thereby developing discrete, nodular cyst wall calcifications.

Figure 1

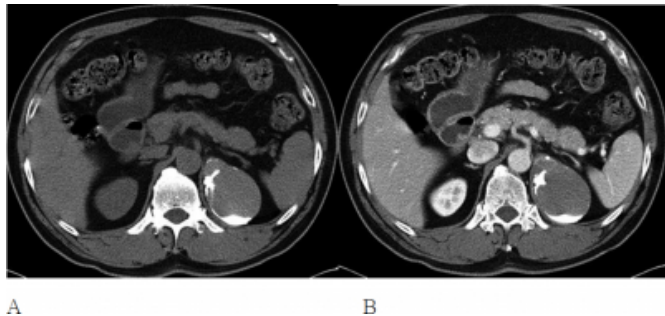
Figure 1. A 62-year-old woman with a retroperitoneal bronchogenic cyst



A-C. Unenhanced axial and coronal CT images demonstrate a 10x9x6-cm dimension, well defined, multichambered, heterogeneous density, cystic mass in the left suprarenal fossa (A and C). The different density of the intracystic fluid-fluid level was noted. Soft tissue attenuation areas were also seen in the upper portion of the mass. The left adrenal gland was displaced anteromedially by this mass. Contrast-enhanced CT showed no abnormal contrast enhancement within the lesion (B).

Figure 2

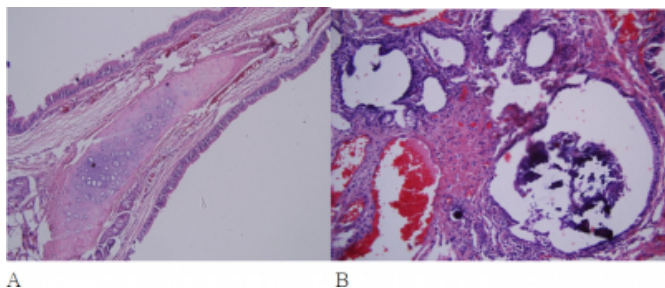
Figure 2. 62-year-old woman with a retroperitoneal bronchogenic cyst



A-B. Follow-up CT revealed that as the amount of the intracystic milk of calcium had decreased and appeared denser, and thereby several nodular calcifications in the cyst wall developed during one-year of follow-up period.

Figure 3

Figure 3. 62-year-old woman with a retroperitoneal bronchogenic cyst



A. Histologic specimen demonstrated dilated bronchioles with a thin layer of connective tissue just beneath the epithelium overlying the elastica and smooth muscle investiture.

B. Histologic specimen demonstrated multiple foci of calcification in the lumen of the dilated bronchioles

References

1. McAdams HP, Kirejczyk WM, Rosado-de-Christenson ML, Matsumoto S. Bronchogenic cyst: imaging features with clinical and histopathologic correlation. *Radiology* 2000;217:441-446
2. Hisatomi E, Miyajima K, Yasumori K, et al. Retroperitoneal bronchogenic cyst: a rare case showing the characteristic imaging feature of milk of calcium. *Abdom Imaging* 2003;28:716-720
3. Sohn KM, Kim KJ, E.S. M. Retroperitoneal Bronchogenic Cyst: A Case Report *J Korean Radiol Soci* 2007;57:451-453
4. Cornell SH. Calcium in the fluid of mediastinal bronchogenic cyst: a new roentgenographic finding. *Radiology* 1965;85:825-828
5. Cubillo E, Rockoff SD. Milk of calcium fluid in an intrapulmonary bronchogenic cyst. *Chest* 1971;60:608-610
6. Aydingoz U, Ariyurek M, Selcuk ZT, Demirkazik FB, Baris YI. Calcium within a bronchogenic cyst with a fluid level. *Br J Radiol* 1997;70:761-763
7. Glazer HS, Siegel MJ, Sagel SS. Low-attenuation mediastinal masses on CT. *Am J Roentgenol* 1989;152:1173-1177
8. Naidich DP, Rumancik WM, Ettenger NA, et al. Congenital anomalies of the lungs in adults: MR diagnosis. *AJR Am J Roentgenol* 1988;151:13-19
9. Yang SW, Linton JA, Ryu SJ, Shin DH, Park CS. Retroperitoneal multilocular bronchogenic cyst adjacent to adrenal gland. *Yonsei Med J* 1999;40:523-526
10. Menke H, Roher HD, Gabbert H, Schweden F. Bronchogenic cyst: a rare cause of a retroperitoneal mass. *Eur J Surg* 1997;163:311-314
11. Murakami R, Machida M, Kobayashi Y, Ogura J, Ichikawa T, Kumazaki T. Retroperitoneal bronchogenic cyst: CT and MR imaging. *Abdom Imaging* 2000;25:444-447
12. Mendelson DS, Rose JS, Efremidis SC, Kirschner PA, Cohen BA. Bronchogenic cysts with high CT numbers. *Am J Roentgenol* 1983;140:463-465
13. Marvasti MA, Mitchell GE, Burke WA, Meyer JA. Misleading density of mediastinal cysts on computerized tomography. *Ann Thorac Surg* 1981;31:167-170
14. Marin ML, Romney BM, Franco K, Grimes MM, Smith C. Bronchogenic cyst: a case report emphasizing the role of magnetic resonance imaging. *J Thorac Imaging* 1991;6:43-46
15. Yernault JC, Kuhn G, Dumortier P, Rocmans P, Ketelbant P, De Vuyst P. "Solid" mediastinal bronchogenic cyst: mineralogic analysis. *AJR Am J Roentgenol* 1986;146:73-74
16. Nakata H, Sato Y, Nakayama T, Yoshimatsu H, Kobayashi T. Bronchogenic cyst with high CT number: analysis of contents. *J Comput Assist Tomogr* 1986;10:360
17. Altinok T, Topcu S, Kurul IC, Yazici U. Bronchogenic cyst with milk of calcium. *Eur J Cardiothorac Surg* 2002;22:311
18. Ingu A, Watanabe A, Ichimiya Y, Saito T, Abe T. Retroperitoneal bronchogenic cyst: a case report. *Chest*.

2002;121:1357-1359

19. Coselli MP, de Ipolyi P, Bloss RS, Diaz RF, Fitzgerald

JB. Bronchogenic cysts above and below the diaphragm: report of eight cases. Ann Thorac Surg. 1987;44:491-494

Author Information

Soo Youn Park, M.D.

Department of Radiology, St. St. Vincent's Hospital, College of Medicine, The Catholic University of Korea

Seong Su Hwang, MD

Department of Radiology, St. St. Vincent's Hospital, College of Medicine, The Catholic University of Korea