

Emergency Tracheotomy – A Six Year Experience Of A Rural Tertiary Hospital.

V Babu. S, A Mohiyuddin, I Narasimhan, N G.K, V .U, P Nair

Citation

V Babu. S, A Mohiyuddin, I Narasimhan, N G.K, V .U, P Nair. *Emergency Tracheotomy – A Six Year Experience Of A Rural Tertiary Hospital.* The Internet Journal of Otorhinolaryngology. 2009 Volume 12 Number 1.

Abstract

Introduction: Emergency Tracheotomy is a life saving procedure for patients with “Can’t ventilate, can’t intubate” situation. The commonest indication of tracheotomy has changed from inflammatory causes in the past to the present day prolonged intubation. **Objective:** To review the indications and early complications of emergency tracheotomy. **Methods:** A retrospective study of patients who underwent emergency tracheotomy from 2005 to 2010. The study was conducted at R.L.Jalappa hospital and research centre attached to Sri Devaraj Urs Medical College, Kolar. Data was obtained from Inpatient records and operative notes. **Results:** Our study includes 105 patients 31 female and 74 males, age ranging from 1 yr to 80yrs. with mean age of 41 yrs. The majority of patients were in third decade (Fig 1). The commonest symptom of presentation was stridor, followed by severe oro-nasal bleeding secondary to faciomaxillary trauma and cut throat injuries. Most common indication was tumours of neck region followed by deep neck space infections. Complications include haemorrhage and surgical emphysema which were handled efficiently there were no deaths due to the procedure. **Conclusion:** Open surgical tracheotomy is a safe and reliable method of restoring airway. There should not be any hesitation to do tracheotomy as its safety is well established. The need for the tracheotomy should be decided by what the situation demands.

INTRODUCTION

Emergency Tracheotomy is a life saving procedure for patients with acute airway obstruction and impending airway obstruction in “can’t ventilate, can’t intubate” situation. Although cricothyroidotomy and percutaneous tracheotomy are available alternatives, open method of tracheotomy provides more rapid and safe method to secure airway¹. The commonest indication of tracheotomy has changed from inflammatory causes in the past to the present day prolonged intubation.²

OBJECTIVE

To review the indications and early complications of emergency tracheotomy

METHODS

It is a retrospective study of patients who underwent emergency tracheotomy from 2005 to 2010 at R.L.Jalappa hospital and research centre attached to Sri Devaraj Urs Medical College situated at Kolar district of Karnataka state in south India. Data was obtained from Inpatient records and operative notes.

Ninety five patients underwent awake tracheotomy under

local anaesthesia using 2% Xylocaine with 1:200000 Adrenaline. In four paediatric patients inj. Midazolam was used as a sedative and in six patients general anaesthesia was used. General anaesthesia was used in five cut throat injuries where existing opening was used to induce the patient and in one child to remove the foreign body via tracheotomy.

The patients were positioned with the neck extended with the head up 15-30 degrees to the horizontal. 2% Xylocaine with 1:200000 Adrenaline was infiltrated into the skin at a two finger breadth above sternal notch, a transverse skin crease incision was made, and the strap muscles were separated in the midline. The thyroid isthmus was dissected away from the field, if it lay below the second tracheal ring. An inverted ‘U’ shaped incision was performed at the level of the second or third tracheal ring and Bjork flap was created. A tracheal dilator was used to facilitate insertion of the tracheotomy tube. A cuffed tracheotomy tube was used initially in all cases except in four paediatric patients where uncuffed tube was used. The tracheotomy tube was held in place by suturing to the skin and retained by tapes passed around the neck. All tracheotomies were performed by ENT surgeons of senior resident and above cadre.

Percutaneous transtracheal ventilation was planned to be the alternative method of ventilation during the procedure. This procedure involves a caudally directed puncture of the cricothyroid membrane with a 14-gauge intravenous catheter. After the catheter has been placed into the trachea, the needle is removed and oxygen is provided via a jet injector. However it was not used in any of the cases.

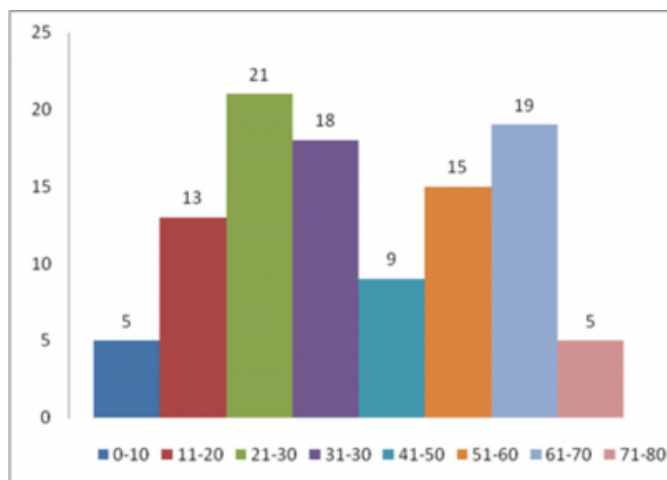
All the tracheotomy tubes were cleaned and replaced first on 4th postoperative day and regularly thereafter. All patients received constant humidification of their inspired air and regular tracheobronchial suction using a fine sterile catheter during the early postoperative period. This care was performed by ward nursing staff trained in tracheotomy care. Patients were managed in the intensive care unit postoperatively if ventilatory support was necessary or as determined by the patient's general condition.

RESULTS

Our study includes 105 patients 31 female and 74 males, age ranging from 1 yr to 80yrs.with mean age of 41 yrs. The majority of patients were in third decade (Fig 1).

Figure 1

Fig.1 Age Distribution



The commonest symptom of presentation was stridor in 95 (90.47%) patients, followed by severe oro-nasal bleeding secondary to faciomaxillary trauma in 5 (4.76%) and cut throat injuries in 5 (4.76%). The commonest indication was stridor secondary to tumours of neck region in 31 (29.52%) followed by Deep neck space infections in 22 (20.95%) (Table.1).

Figure 2

Table.1 Indications of Tracheotomy

Sl.No.	Indication	No. Of Patients n (%)
1	Tumours of neck	31 (29.52%)
2	Deep neck space abscess	22 (20.95%)
3	Trauma of head and neck	19(18.09%)
4	Hanging	12(11.42%)
5	Corrosive poisoning	6(5.71%)
6	Cut throat injury	5(4.76%)
7	Burns	3(2.85%)
8	Epiglottitis	2(1.90%)
9	Idiopathic bilateral abductor palsy with laryngeal oedema	1(0.95%)
10	Diphtheria	1(0.95%)
11	Foreign body	1(0.95%)
12	Idiopathic tongue edema	1(0.95%)
13	Accidental self extubation with stridor	1(0.95%)

Among the tumours supraglottis tumours account for 12 patients (38%) (Fig.2) and Ludwig's angina leads the chart with 16 patients (72.72%) (Fig.3) in the deep neck space abscess group.

Figure 3

Fig. 2

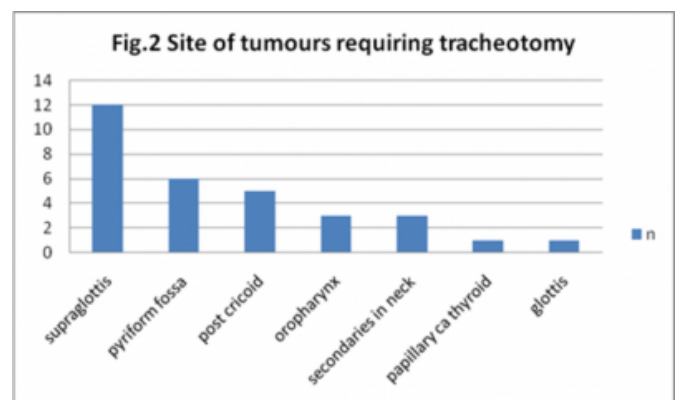
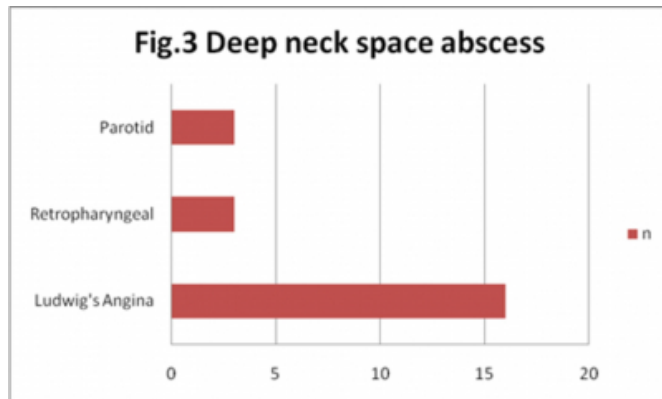


Figure 4

Fig.3



The common indications of tracheotomy in the age group of 61-70 yrs. were tumours and deep neck space infections 18 (94.73%). There were 21 Patients in the age group of 21-30 yrs., trauma 8 (38.09%) and deep neck space infections 6 (28.57%) were the common indications for tracheotomy. Among 13 patients in the age group of 11-20yrs. Hanging and suicidal corrosive poisoning accounts to 9 (69.7%). The average duration for inserting the tracheotomy tube was 8 minutes. Surgical access to the airways was successful in all the patients. Ten (9.52%) of our patients experienced complications including peri-operative haemorrhage in 5, early post operative surgical emphysema in 4 and pneumothorax in 1. There were no deaths due to the procedure.

DISCUSSION

It was only after Chevalier Jackson established the standard technique and safety of tracheotomy the indications for the procedure expanded rapidly¹. Due to improved non surgical airway management techniques the number of patients requiring emergency tracheotomy is reduced. In recent years the majority of the tracheotomies are performed electively in intubated patients in intensive care units³. However, one of the most important indications for tracheotomy is acute upper airway obstruction. The establishment of an emergency surgical airway for acute upper airway obstruction becomes critical when establishment of the airway by other means fails or is not possible. Three main methods of airway management are available in this setting: cricothyroidotomy, Percutaneous tracheotomy and open tracheotomy.

Cricothyroidotomy is well established as a fast and simple procedure for emergency surgical airway access in adult trauma patients^{4,5}. The procedure is carried out by a

transverse incision through the skin and the cricothyroid membrane and then spreading the incision vertically to allow placement of the tube. We prefer to do open method of tracheotomy because the cricothyroid membrane is bounded by two rigid structures (thyroid cartilage and cricoid cartilage) that are not easily dilated, the height of this membrane limits the size of the tube that can be placed. The principal long-term morbidity of cricothyroidotomy is the development of subglottic stenosis. As such, cricothyroidotomy is replaced with a standard tracheotomy within 24-48 hours⁶.

Percutaneous dilatational tracheotomy is also advocated in emergency situation including trauma^{7,8}. We believe open method provides better exposure to handle the situations like enlarged thyroid, short neck and establish airway early. Since there is no Bjork flap created it becomes difficult for the nursing staff to reinsert the tube in case the need arises. One major disadvantage of percutaneous tracheotomy is that only a narrow, dilated tract, rather than a formal stoma, is created during the procedure. This results in an increased rate of tube displacement and difficult tube reinsertion with percutaneous tracheotomy as compared with a standard tracheotomy⁹. An increased rate of postoperative death owing to tube dislodgment has been described with the percutaneous technique¹⁰. An additional disadvantage of percutaneous tracheostomy is the risk of tracheal or subglottic stenosis. Because of the progressive dilations performed during percutaneous tracheostomies, the tracheal cartilages are at high risk for crush injury during the procedure. Damaged cartilage poses a risk of scar tissue formation and subsequent tracheal or subglottic stenosis¹¹.

For the patients with laryngopharyngeal and laryngeal tumours a high tracheotomy was done. We are aware of the increased incidence of the stomal recurrence in these cases,¹² but the creation of tracheotomy was inevitable in these cases who presented to us with stridor.

Though some authors support fibre-optic intubation for patients with deep neck space abscess we prefer to do open method of tracheotomy as a first choice^{13,14}. The trial intubation can cause rupture of pus into the oral cavity with subsequent aspiration, airway oedema and laryngospasm further worsening the airway obstruction¹⁵.

Fourteen of nineteen tracheotomies done for trauma patients were for ongoing airway obstruction or impending airway obstruction. Rest of the tracheotomies were done in cases of heavy oro-nasal bleeding, to avoid aspiration of blood and to

establish airway for the general anaesthesia to do post nasal packing and to ligate the external carotid artery.

Patients requiring tracheotomy due to hanging were given a trial of endotracheal intubation. In cases of corrosive poisoning, tracheotomy was the preferred method of establishing airway. No manipulation of airway was tried for the fear of further traumatising the airway and worsening the symptoms.

All cut throat injuries were above the level of cricoid cartilage exposing laryngeal and hypopharyngeal lumen. Airway was initially secured by the existing opening into the larynx, later converted to the open tracheotomy. The neck wound was later closed in layers. No patients had any long term complications. Three of the cut throat injuries were homicidal injuries and rest were suicidal.

One year old female child underwent emergency bronchoscopy. The aspirated foreign body had enlarged and could not be negotiated through the glottis. Emergency tracheotomy was done and the foreign body was removed via tracheotomy.

Idiopathic tongue oedema with stridor was encountered in a one year old child. Child had to undergo tracheotomy because of lack of space to negotiate laryngoscope and the endotracheal tube. The swelling reduced within two days following anti oedema measures.

An elderly lady underwent major head and neck surgery for buccal mucosa tumour with PMMC flap reconstruction. She accidentally pulled out the endotracheal tube in intensive care unit and developed stridor. We performed emergency tracheotomy with the intention of not disturbing the PMMC flap. Though flexible bronchoscope guided nasal intubation was an alternative method, we preferred open tracheotomy because of possible oedema of the tongue obstructing bronchoscope to enter into laryngeal inlet.

In addition to tumours and abscess, other indications like hanging, corrosive poisoning and cut throat injuries were not frequently encountered by other researchers.

In the few above mentioned instances the situations could have been managed in different ways. We performed tracheotomies because it was most appropriate and safe method to follow with the available resources.

Ten (9.52%) of our patients experienced complications which is comparable to other studies.^{1,16,17} Haemorrhage due

to thyroid isthmus was encountered in 3 and due to anterior jugular vein in 2 patients. Both these cases were managed efficiently by achieving complete haemostasis. Early post operative surgical emphysema was found in 4 patients and regressed spontaneously. Pneumothorax in 1 case was successfully handled by putting intercostal drainage.

CONCLUSION

Tumours of head and neck region and deep neck space abscess form the common indications for tracheotomy. Open surgical tracheotomy is a safe and reliable method of restoring airway. There should not be any hesitation to do tracheotomy as its safety is well established. The need for the tracheotomy should be decided by what the situation demands.

References

1. Heng-Wai Yuen, Andrew Heng-Chian Loy, Shirish Johari: Urgent awake tracheotomy for impending airway obstruction. *Otolaryngology-Head and Neck Surgery*; 2007;136(5):838-842.
2. Parilla C, Scarano E, Guidi ML, Galli J, Paludetti G: Current trends in pediatric tracheostomies. *Int J Pediatr Otorhinolaryngol*; 2007; 71(10):1563-7.
3. Goldenberg D, Golz A, Netzer A, et al: Tracheotomy: changing indications and a review of 1,130 cases. *J Otolaryngol*; 2002;31:211-5.
4. Bair AE, Panacek EA, Wisner DH, et al: Cricothyrotomy: a 5-year experience at one institution. *J Emerg Med*; 2003;24:151- 6.
5. Delaurier G, Hawkins ML, Treat RC, et al: Acute airway management: role of cricothyroidotomy. *Am Surg*; 1990;56:12-5.
6. Esses BA, Jafek BW: Cricothyroidotomy: a decade of experience in Denver. *Ann Otol Rhinol Laryngol*; 1987;96:519 -24.
7. Ault MJ, Ault B, Ng PK: Percutaneous dilatational tracheostomy for emergent airway access. *J Intensive Care Med*; 2003;18:222-6.
8. Alon Ben-Nun, Edward Altman, Lael-Anson E Best: Emergency Percutaneous Tracheostomy in trauma patients: An early experience. *Ann Thorac Surg*; 2004;77:1045-7.
9. Graham JS, Mullory RH, Sutherland FR, Rose S: Percutaneous versus open tracheostomy: a retrospective cohort outcome study. *J Trauma*; 1996;42:245-50.
10. Dulguerov P, Gysin C, Perneger TV, Chevrolet JC: Percutaneous or surgical tracheostomy: a metaanalysis. *Crit Care Med*; 1999;27:1617-25.
11. Joseph C Snizek, Brian B Burkey: Airway Control and Laryngotracheal Stenosis in Adults. In, James B Snow Jr, John Jacob Ballenger (eds). *Ballenger's Otorhinolaryngology Head and Neck Surgery*, 16th Edition. Ontario, BC Decker Inc, 2003;1151-67.
12. Bignardi L, Garioli C, Staffieri A: Tracheostomal recurrence after laryngectomy. *Arch Otolaryngol*; 1983;238:107-13.
13. Kulkarni AH, Pai SD, Bhattarai B, Rao ST, Ambareesha M: Ludwig's angina and airway considerations: a case report. *Cases Journal*; 2008 jun;1(1):19.
14. Wolfe MM, Davis JW, Parks SN: Is surgical airway necessary for airway management in deep neck infections

and Ludwig angina?. J Crit Care; 2010 May:[Epub ahead of print]

15. Spitalnic SJ, Sucov A: Ludwig's angina: case report and review. J Emerg Med; 1995; 13: 499-503.

16. Altman KW, Waltonen JD, Kern RC: Urgent surgical

airway intervention: a 3 year county hospital experience.

Laryngoscope; 2005 Dec; 115(12): 2101-4.

17. Waldron J, Padgham ND, Hurley SE: Complications of emergency and elective tracheostomy: a retrospective study of 150 consecutive cases. Ann R Coll Surg Engl; 1990; 72: 218-20.

Author Information

Vinaya Babu. S, M.S

Asst. Professor, Dept. of Otolaryngology, head and neck surgery, Sri Devaraj Urs Medical College

Azeem Mohiyuddin, M.S

Professor, Dept. of Otolaryngology, head and neck surgery, Sri Devaraj Urs Medical College

Indira Narasimhan, M.S

Professor and former HOD, Dept. of Otolaryngology, head and neck surgery, Sri Devaraj Urs Medical College

Narayana. G.K, M.S

Professor and head, Dept. Of Otorhinolaryngology And Head And Neck Surgery, Sri Devaraj Urs Medical College

Venkatesh .U, M.S

Associate Professor, Dept. Of Otorhinolaryngology And Head And Neck Surgery, Sri Devaraj Urs Medical College

Parvathi.G. Nair, M.B.B.S

Junior Resident, Dept. Of Otorhinolaryngology And Head And Neck Surgery, Sri Devaraj Urs Medical College