

Giant Submucous Lipoma Of The Colon

A Saklani, D Banerjee, R Hargest

Citation

A Saklani, D Banerjee, R Hargest. *Giant Submucous Lipoma Of The Colon*. The Internet Journal of Surgery. 2002 Volume 4 Number 1.

Abstract

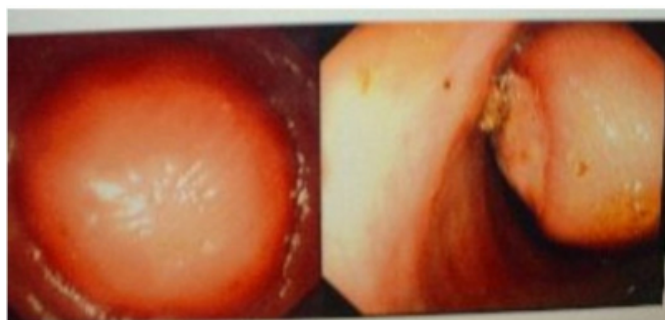
Lipomas of the colon, although the second most common benign tumor of the colon, are relatively rare. Symptomatic patients may present with obstruction, intussusception, bleeding. Their size, broad base and difficulty in establishing pre-operative diagnosis makes surgical resection imperative.

CASE REPORT

A 56 year old female presented with six month history of lower abdominal pain, blood and mucus in stools and a feeling of incomplete evacuation after stools. She gave no history of weight loss, diarrhoea or familial colon cancer. Clinical examination and routine blood investigations including inflammatory markers were normal. A colonoscopy examination revealed a smooth submucous swelling 5-cm in diameter about 38 cm from anal verge (Figure 1).

Figure 1

Figure 1: Endoscopic photograph of lipoma of colon



The lesion was broad based with overlying normal mucosa except a point of focal ulceration. A biopsy taken from this site was normal and a pre-emptive diagnosis of stromal tumour was made. A CT scan performed revealed proximal dilated colon with thickening of colon wall below this. There were no signs of serosal breach or nodal or liver metastasis. Exploratory laparotomy revealed a localised tumour of the left colon, for which a left hemicolectomy was performed. Final pathology revealed mature fat cells in the submucosa, suggestive of lipoma. There was a focal area of mucosal infiltration by leucocytes. The postoperative period

was uneventful.

DISCUSSION

Lipomas of the colon are relatively uncommon in clinical practise. Although lipomas constitute 4% of benign neoplasms of the gastrointestinal tract, they are second commonest benign tumor of the large bowel¹. The majority (90%) of these lipomas are submucosal. Only lipomas more than 2cm in size are symptomatic^{2,3}. Large submucosal tumours are known to cause obstruction, intussusception and even spontaneous sloughing^{4,5,6,7}. This may be the reason, they present in the fifth or sixth decade. However this is also the age group for epithelial and stromal neoplasms. Lipomas of the colon are predominantly right sided with a slight preponderance in females^{8,9}. Recurrence or neoplastic changes in these lesions has not been documented.¹⁰

Tests on barium enema (squeeze sign- mass changes size on peristalsis and pressure) and colonoscopy (pillow or cushion sign- tumor becomes indented with closed biopsy forceps and springs back to normal shape when released) may be suggestive². However these tests are operator dependent.

The differential diagnosis for such large broad based submucosal swelling includes submucosal lipomas, stromal tumours or extrinsic compression¹¹. A CT scan ruled out an extrinsic compression but revealed no information on the nature of the swelling. We did not believe that further diagnostic investigations would be of therapeutic use. Had the tumor been smaller, a preoperative EUS may have revealed submucosal location and fatty consistency of the tumor. This would have helped in attempting endoscopic resection. However endoscopic resection in such patients is not without complications¹². The possibility of cutting a

pedicle based on intussuscepting serosa increases chances of perforation. Also lipomatous tissue (containing a lower water content) conducts electrosurgical current less efficiently. This patient's age, good preoperative condition and impending obstruction made her an ideal candidate for surgery.

LEARNING POINTS:

- Lipomas of large bowel are not uncommon
- In elderly unfit patients, preoperative EUS and endoscopic resection to avoid surgical intervention is suggested.

CORRESPONDENCE TO

Mr Saklani AP, 11, Penycraig, Rhwbina. Cardiff. United Kingdom CF14 6ST Email: asaklani@hotmail.com

References

1. Mayo CW, Pagtalunan RJG, Brown DJ. Lipoma of the alimentary tract. *Am J Clin Path* 1955; 25:272-281
2. Haller JD, Roberts TW. Lipomas of the colon: a clinicopathological study twenty cases. *Surgery* 1964; 55:773-81
3. Ryan J, Martin JE, Pollock DJ. Fatty tumors of the large intestine: a clinicopathological review of 13 cases. *BJS* 1989; 76(8):793-796
4. Alponat A, Kok KY, Goh PM, Ngoi SS. Intermittent subacute obstruction due to giant lipoma of colon: a case report. *Am Surg* 1996;62(11):918-21
5. Siddiqui MN, Garnham JR. Submucosal lipoma of the colon with intussusception. *Postgraduate medical journal*. 1993; 69(812):497
6. Rogy MA, Mirza D, et al. Submucosal large-bowel lipomas - presentation and management. An 18 year study. *Eur J Surg*. 1991; 157(1):51-5
7. Radhi JM. Lipomas of the colon: self amputation. *Am J Gastroenterol*. 1993;88(11): 1981-2.
8. Castro EB, Stearns MW. Lipoma of the large intestine: a review of 45 cases. *Dis Col & rectum* 1972; 15:441-4.
9. Creasy TS, Baker AR, Tabot IC, Veitch PS. Symptomatic submucosal lipomas of the large bowel. *Br J Surg*. 1987;74(11):984-6.
10. Hancock BJ, Vajener A. Lipomas of the colon: A clinicopathological review. *Can J Surg*. 1988;31: 178-81
11. Symptomatic colonic lipomas: differential diagnosis of large bowel tumors. *Int J Colorectal Dis*. 1998; 13(1):1-2.
12. Pfell SA, Weaver MG, Abdul-Karim FW, et al. Colonic lipomas: outcome of endoscopic removal. *Gastroint Endosc*. 1990; 36: 435-8

Author Information

AP Saklani, FRCS
Nevill Hall Hospital

D Banerjee, FRCS
Nevill Hall Hospital

R Hargest, FRCS, MD
Nevill Hall Hospital