

Histological Studies Of The Effects Of Oral Administration Of Artesunate On The Stomach Of Adult Wistar Rats

A Eweka, J Adjene

Citation

A Eweka, J Adjene. *Histological Studies Of The Effects Of Oral Administration Of Artesunate On The Stomach Of Adult Wistar Rats*. The Internet Journal of Health. 2007 Volume 7 Number 1.

Abstract

The histological effect of oral administration of artesunate commonly used for the treatment of Malaria on the stomach of adult Wistar rat was carefully studied. The rats of both sexes (n=24), average weight of 210g were randomly assigned into three treatment (n=18) and control (n=6) groups. The rats in the treatment group 'A' received 4mg/kg body weight of artesunate base dissolved in distilled water daily for 3 days, through orogastric tube. The animals in groups 'B' and 'C' received 4mg/kg body weight of artesunate base dissolved in distilled water for the first day and thereafter received 2mg/kg body weight daily for six and thirteen days through the same route respectively, while that of the control group D, received equal volume of distilled water daily during the period of the experiment. The rats were fed with growers' mash obtained from Edo Feeds and Flour Mill Ltd, Ewu, Edo State, Nigeria and were given water liberally. The rats were sacrificed on day four, eight and fifteen of the experiment. The stomach was carefully dissected out and quickly fixed in 10% formal saline for histological studies. The histological findings after H&E method indicated that the treated section of the stomach showed some degenerative and necrotic changes, cellular hypertrophy, and increase intercellular vacuolations appearing in the stroma of the stomach of adult Wistar rats.

Varying dosage and long administration of artesunate may have some deleterious effects on the gastric cells and stomach mucosa, and this may probably have some adverse effects like gastritis or worse still gastric ulcer in adult Wistar rats. It is therefore recommended that further studies aimed at corroborating these observations be carried out.

INTRODUCTION

Malaria remains one of the world's most significant health problems despite increasing research and control efforts₁. Over two billion people are at risk of infection, over a quarter of a billion cases are thought to occur annually, and at least a million people die every year as a result of the disease, alone or in combination with other conditions. The disease is estimated to be responsible for an annual loss of around 0.5 to 1% of gross domestic product in countries where it is endemic₂. The occurrence of malaria during pregnancy exposes the mother and infants to serious risks. It is therefore imperative that pregnant women be protected against malaria; and that pregnant women with malaria receive treatment as soon as possible₃.

Artesunate is one of the numerous drugs for malaria intervention in Nigeria. It is a semi synthetic derivative of artemisinin, the active compound of the Chinese herb *Artemisia annua* which consist of the sodium succinyl salt of dehydroartemisinin₃. Artemisinin-type compounds reduce malaria parasitemia more rapidly than any other known

antimalarial drugs and are effective against multi drug resistant malaria parasites_{4,5}. Artesunate is highly effective against multi-drug resistant strains of plasmodium falciparum hence its increasingly wide usage for the treatment and management of malaria₆. Artesunate is well tolerated at therapeutic doses; therefore a lot of people, pregnant women inclusive take the drug.

Several studies have shown that high doses of artesunate can produce neurotoxicity such as selective damage to brainstem centres in mice and rats_{7,8,9}. Artesunate have been reported to cause gait disturbances, loss of spinal cord and pain response mechanisms in animals_{10,11}.

The stomach, a distensible organ located in the abdominal cavity, functions in the degradation and digestion of food materials in the body. It also prevents gastric ulceration due to the presence of numerous mucous secreting glands₁₂.

The effects of artesunate on the stomach may not have been documented, but there have been reports that it may be implicated in varied symptoms of nausea, vomiting, diarrhea

and abdominal pain. This present study was to elucidate the histological effects of artesunate on the stomach of adult Wistar rats.

MATERIALS AND METHODS

The present study was registered and given due approval for the methodology therein by the ethical review committee of the University of Benin, Benin City as stipulated by the Nigerian Health Research Ethics Committee.

Animals: Twenty-four (24) adult Wistar rats of both sexes with average weight of 210g were randomly assigned into four groups A, B, C and D of (n=6) in each group. Groups A, B, and C of (n=18) serves as treatments groups while group D (n=6) is the control. The rats were obtained and maintained in the Animal holdings of the Department of Anatomy, School of Basic Medical Sciences, University of Benin, Benin city, Nigeria. They were fed with growers' mash obtained from Edo feed and flour mill limited, Ewu, Edo state, and were given water liberally. The rats were allowed to gain maximum acclimatization before the actual commencement of the experiment. The Artesunate tablets were obtained from the University of Benin Teaching Hospital Pharmacy, Benin City, Edo state, Nigeria.

Artesunate Administration: The rats in the treatment groups (A, B, & C) received 4mg/kg body weight of Artesunate base dissolved in distilled water for the first day. Animals in the treatment group 'A' continued with this dosage for the next two days, while animals in groups B & C received 2mg/kg once daily for six and thirteen days respectively. The control group D received equal volume of distilled water through orogastric tube. The treated rats in groups A, B, and C were sacrificed by cervical dislocation on the 4th, 8th and 15th day of the experiment respectively, while that of the control group D was sacrificed at the end of the experiment. The abdominal region was opened to expose the abdominal visceral. The stomach was quickly dissected out and fixed in 10% formal saline for routine histological techniques.

Histological Study: The tissue was dehydrated in an ascending grade of alcohol (ethanol), cleared in xylene and embedded in paraffin wax. Serial sections of 7 microns thick were obtained using a rotatory microtome. Some of the deparaffinized sections were stained routinely with haematoxyline and eosin (H&E) method₁₃. The digital photomicrographs of the desired sections were made in the Department of Anatomy research laboratory, University of Benin, Nigeria for further observations.

RESULTS

The sections of stomach from the controls showed normal histological features with distinct highly packed glandular secretory mucosa of the stomach and presence of vacuolations in the sections (Figure 1).

The sections of the stomach from the treatment (A, B, & C) groups showed some varying degree of degenerative and necrotic changes, and cellular hypertrophy. There were marked intercellular vacuolations appearing in the stroma and distortions in the epithelia and glandular cells of the stomach (Figure 2, 3 &4).

Figure 1

Figure 1 (GROUP D): Control section of the stomach (Mag. x400).




Figure 2

Figure 2 (GROUP A): Treatment section of the stomach (group A) that received 4mg/kg of artesunate for 3 days, (Mag. x400)

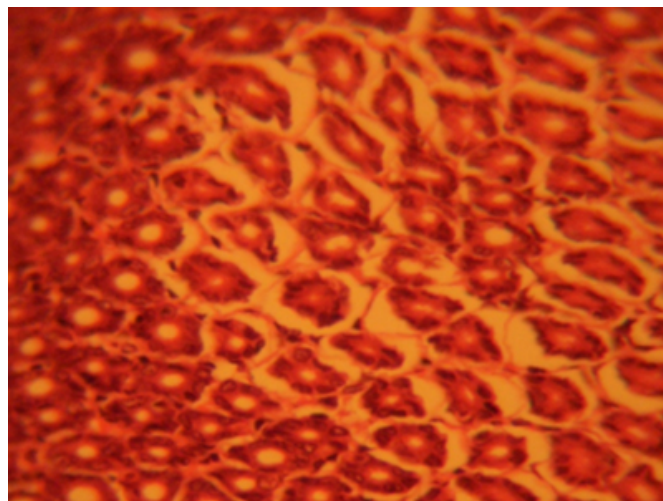


Figure 3

Figure 3 (GROUP B): Treatment section of the stomach (group B) that received 4mg/kg 1st day and thereafter 2mg/kg for 6 days of artesunate. (Mag.x400)

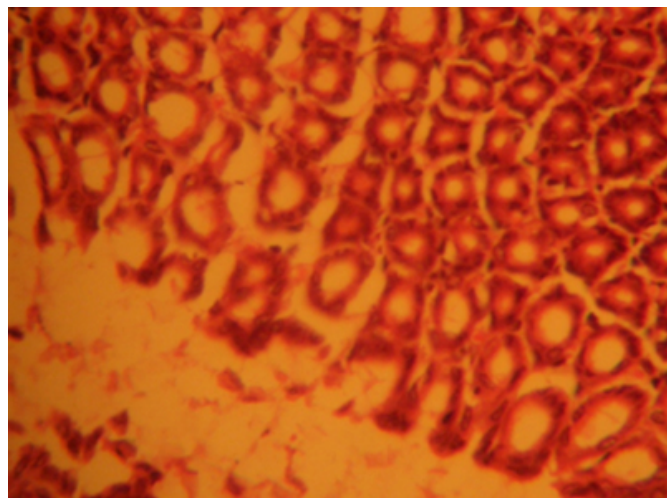
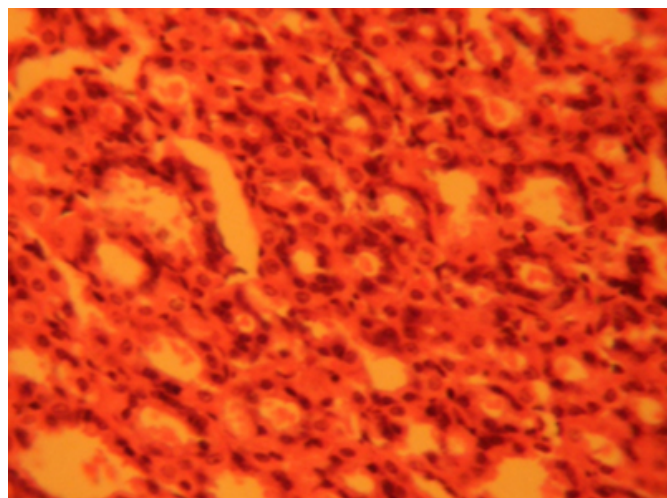


Figure 4

Figure 4 (GROUP C): Treatment section of the stomach (group C), that received 4mg/kg 1st day and thereafter 2mg/kg for 13 days of artesunate. (Mag. x400)



DISCUSSION

The results (H & E) revealed that administration of artesunate showed some degenerative and necrotic changes, cellular hypertrophy, and increase intercellular vacuolations which appeared in the stroma of the treatment groups compared to the control section of the stomach. Degenerative changes have been reported to result in cell death, which is of two types, namely apoptotic and necrotic cell death. These two types differ morphologically and biochemically¹⁴. Pathological or accidental cell death is regarded as necrotic and could result from extrinsic insults to

the cell such as osmotic, thermal, toxic and traumatic effects¹⁵.

The process of cellular necrosis involves disruption of the membranes structural and functional integrity. Cellular necrosis is not induced by stimuli intrinsic to the cells as in programmed cell death (PCD), but by an abrupt environmental perturbation and departure from the normal physiological conditions¹⁶. There is the need to further investigate the actual mechanism by which artesunate induced cellular degeneration in the stomach of adult Wistar rat in this study.

In this study artesunate may have acted as toxin to the cells of the stomach, affecting their cellular integrity and causing defect in membrane permeability and cell volume homeostasis. In cellular necrosis, the rate of progression depends on the severity of the environmental insults. The greater the severity of the insults the more rapid the progression of neuronal injury¹⁷. The principle holds true for toxicological insult to the brain and other organs¹⁶. It is inferred from this results that prolonged and high dose of artesunate resulted in increased toxic effects on the stomach.

The vacuolations observed in the stroma of the stomach in this experiment may be due to artesunate interference. The cellular hypertrophy observed in this experiment may be due to the adverse effects of artesunate on the stomach. This study may underlie the possible gastrointestinal symptoms such as nausea, vomiting and abdominal pains.

CONCLUSION

Our study revealed that high doses and long term administration of artesunate causes degenerative and necrotic changes, cellular hypertrophy, and increase intercellular vacuolations in the stomach of adult Wistar rats. These results may probably affect the functions of the stomach and may lead to gastric ulceration in adult Wistar rats.

CORRESPONDING AUTHOR

Andrew.O.Eweka Department Of Anatomy, School Of Basic Medical Sciences, College Of Medical Sciences, University Of Benin, Benin City, Edo State, Nigeria. Email: andreweweka@yahoo.com Tel: +2348023390890, +2348038665346, +2348055216031.

References

1. Curtis CF. Workshop on bed net at the international congress of Tropical Medicine; JPM Saint Zool. 1993

- 2:63-68.
2. Malaney P, Spielman A, Sachs J. The malaria gap. American Journal of Tropical Medicine and Hygiene, 2004, 71 (2 Suppl): 141-146.
3. WHO. Reproductive Risk Assessment of Antimalaria therapy with Artemisinin compounds- report of an informal consultation convened by WHO Geneva. 2002 May 29-30.
4. Ittarat WR, Udomsangpeth KT, Chotivanich, Looareesuwan S. The effects Of quinine and Artesunate treatment on plasma tumor necrosis factor Levels in malaria infected patients. Southeast Asian J. Trop. Med. Public Health. 1999 pp30:7-10.
5. Meshnick SR, Taylor TE, Kanchonwongpaisan P. Artemisinin and the Antemalaria endoperoxidase: From herbal remedy to targeted Chemotherapy; Microbiol. Res. 1996 60: 301-315
6. Olliaro PL, Haynes RK, Meunier B, Yuthavong Y. Possible modes of action of the artemisinin-type compounds. Trends Parasitol 2001,17 122-126.
7. Van Agtmed MA, Eggette TA, Van Boxtel CJ. Artemisinin drugs in the treatment of malaria: From medicinal herb to registered medication. Trends Pharmacol Sci. 1999 20: pp 199-205
8. Nontprasert A, Pukrittayakamee S, Nosten-Bertrand M, Vanijanonta S. Assessment of neurotoxicity of parenteral artemisinin derivatives in mice. Am. J. Trop. Med. Hyg. 1998 59 (4) 519-522
9. Genovese RF, Newman DB, Brewer TG. Behavioral and neural toxicity of the artemisinin antimalaria arteether, but not artesunate and artelinate in rats. Pharmacol Biochem Behav. 2000 67(1) : 37-44
10. Nontprasert A, Pukrittayakamee S, Dondorp AM, Clemens R, Looareesuwan S, White NJ. Neuropathologic toxicity of artemisinin derivatives in a mouse model Am. J. Trop. Med. Hyg 2002 67: 423-429.
11. Genovese RF, Petras JM, Brewer TG. Arteether neurotoxicity in the absence of deficits in behavioral performance in rats. Ann. Trop. Med. Parasitol 1995 89 (4): 447-449
12. Dayan AD. Neurotoxicity and artemisinin compounds: Do the observations in animals justify limitations in clinical use? Paper presented at a conference convened by the international Larveran Association. Annecy, France April 1998 19-22
13. Young B, Heath JW. Wheater's Functional Histology- A text and colour atlas, Fourth Edition. Churchill Livingstone. 2000. pp. 254-260.
14. Drury RAB, Wallington EA, Cameron R. Carleton's Histological Techniques: 4th ed., Oxford University Press NY. U.S.A. 1967 279-280.
15. Wyllie AH. Glucocorticoid-induced thymocyte apoptosis in associated and endogenous endonuclease activation. Nature: London 1980 284:555-556.
16. Farber JL, Chein KR, Mitnacht S. The pathogenesis of Irreversible cell injury in ischemia; American Journal of Pathology 1981; 102:271-281
17. Martins LJ, Al-Abdulla NA, Kirsh JR, Sieber FE, Portera-Cailliau C. Neurodegeneration in excitotoxicity, global cerebral ischaemia and target Deprivation: A perspective on the contributions of apoptosis and necrosis. Brain Res. Bull. 1978 46(4) : 281-309.
18. Ito U, Sparts M, Walker JR, Warzo I. Experimental Cerebral Ischemia in Magolian Gerbils(1). Light microscope observations. Acta Neuropathology. USA. 32:209-223.

Author Information

Andrew O. Eweka

Department Of Anatomy, School Of Basic Medical Sciences, College Of Medical Sciences, University Of Benin

Josiah O. Adjene

Department Of Anatomy, School Of Basic Medical Sciences, College Of Medical Sciences, University Of Benin