

A Rare Case Of Metastatic Tonsillar Malignant Melanoma

H Em?r, Z K?z?lkaya Kaptan, A Tuzuner, S Akged?k

Citation

H Em?r, Z K?z?lkaya Kaptan, A Tuzuner, S Akged?k. *A Rare Case Of Metastatic Tonsillar Malignant Melanoma*. The Internet Journal of Otorhinolaryngology. 2007 Volume 7 Number 2.

Abstract

Nearly 15-30% of all primary malignant melanomas are localised in the head and neck region but mucosal metastases to the oral cavity from melanoma arising in distant sites especially from cutaneous melanomas can be seen in a very rare fashion. There are less than 30 cases of metastatic tonsillar malignant melanoma which were presented in literature. In this paper we present a rare case of metastatic tonsillar malignant melanoma in a 51-year-old female patient in the light of literature.

INTRODUCTION

Primary mucosal malignant melanoma (MM) of the head and neck is an uncommon lesion and comprise approximately 8% of all melanoma cases that occur in this region.[1,2,3] The prognosis of mucosal MM of head and neck region especially in the oral cavity, is poor.[4] The incidence of metastases to the oral cavity is less than that of primary oral melanomas. In the oral cavity, metastases to the palatine tonsils is very rare as tonsils do not have afferent lymphatics and any metastases to the tonsil suggests haematogenous dissemination.[5] In literature less than 30 cases of metastatic palatine tonsil MMs were presented up to 2001 and our case is the first case which is presented after that time.[5,6]

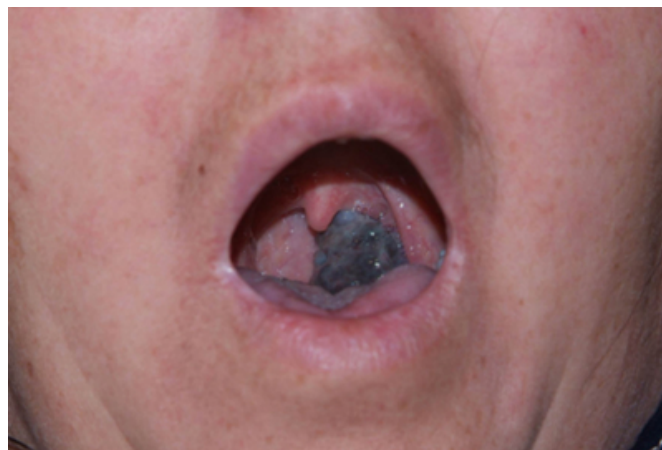CASE REPORT

A 51 year-old female patient appealed to our clinic in January 2007 with the complaint of difficulty in swallowing and pain in the left tonsillar region. She had a medical history of an inguinal mass at the left side and total excision was performed in another clinic, in December 2005. The histopathological finding of this lesion was metastatic malignant melanoma. As the primary site of the lesion or any other metastases were not found when she was evaluated in detail at that time, she was told to visit for controls every 3 months.

In our clinic the patient was examined in detail. In her otorhinolaryngological examination, we realised that her left palatine tonsil was blackish-purple in color, fragile and enlarged within the limits of anterior and posterior plicae and progress to the midline in the oropharynx (Figure 1).

Figure 1

Figure 1 : Left tonsillar melanoma



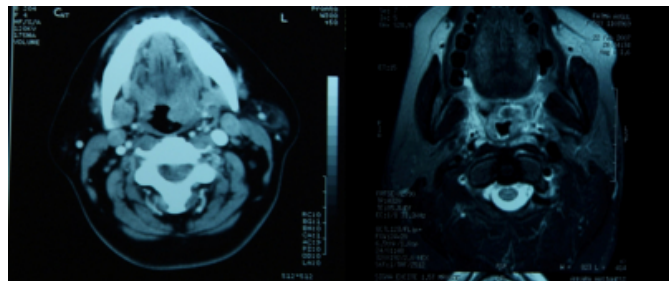
Also in otoscopic examination, there was a pathological finding of increase in vascularization of the left tympanic membrane and air-liquid level in middle ear space. Tympanogram shows C type curve. There was not any palpable lymph nodes in the neck. There were no other pathological findings in otorhinolaryngological examinations.

In the neck ultrasonography, there were few lymph nodes in bilateral servical chain with the size of 8x6 mm of the biggest one. Nasopharynx and neck computerized tomography (CT) and magnetic resonance imaging (MRI) showed us that, there is a significant opaque mass formation which constrict the oropharyngeal air column at the left side, infiltrate the palatum molle, eustachian orifice, torus tubarius at the level of left palatin tonsil, and also infiltrate left medial pterygoid muscle and lateral pharyngeal recess with the formation of heterogeneity in medial pterygoid plate

(Figure 2)

Figure 2

Figure 2 : Computerized tomographic (on the left) and magnetic resonance imaging (on the right) of metastatic tonsillar malignant melanoma



In the neighborhood of left jugular vein and left submandibular gland few lymph nodes with the size of 7 mm of the biggest one were monitored in CT. We did not find any other metastatic mass in thorax and brain with CT scans. The whole body positron emission tomography (PET), indicated positive pathological F-18 FDG restrain of a soft tissue that show protrusion to the left side of oropharynx, bilateral lymph nodes at the cervical chain and a lymph node with the size of 5x4.5 cm at the left inguinal region.

Tonsillectomy and ventilation tube insertion to the left tympanic membrane was performed under general anaesthesia without complication. The histopathological finding was metastatic MM with hematoxylin-eosine and melan-A staining. (Figure 3a, b, c).

Figure 3

Figure 3a: Malignant melanoma, tumour cells that show significant pleomorphism and consist melanin pigments in some of them. (HE, x400)

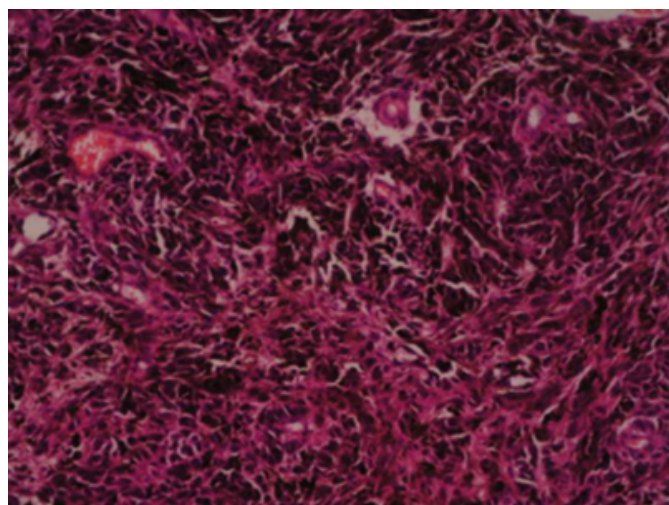


Figure 4

Figure 3b: At the surface under the squamous epithelium of tonsil, extensive tumoural infiltration. (HE, x200)

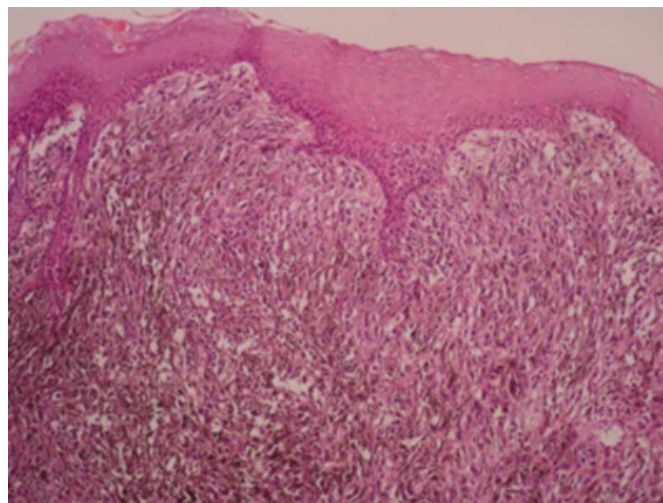
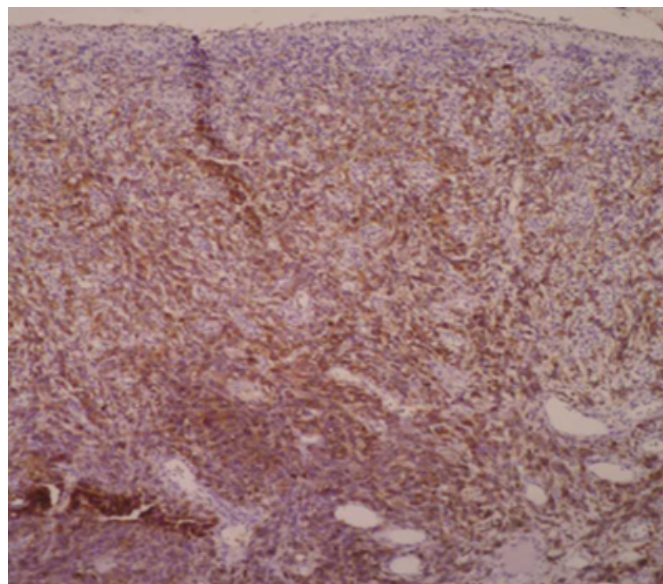


Figure 5

Figure 3c: Immunohistochemical studies of tumoural cells with S 100, intense positive staining. (S 100, x200)



Chemotherapy was arranged at another medical oncology clinic after operation. At the last control, nine months after the operation our patient is still alive without recurrence.

DISCUSSION

Primary mucosal MM of the oral cavity is 0.5-2% of all head and neck region melanomas.^[5,7] Metastases to the oral cavity is very rare ^[5,7,8] and MM metastasizes by lymphatic and vascular channels. Although regional lymph nodes are expected to be involved first, intricate anastomotic pathways among the lymphatic channels may result in the involvement

of distant nodes.[⁸] Henderson et al. previously evaluated 8823 patients who had mucosal MM and presented that 54 of them had metastatic MM frequently to the nasal cavity, tonsils, tongue, nasopharynx, larynx and lips respectively independent of the primary tumour location.[⁹] Metastases to the mucosa of the upper aerodigestive tract indicates widespread dissemination of cutaneous melanoma and the prognosis is poor.[^{5,10}] As palatin tonsils do not have afferent lymphatics, metastases to this region is said to be hematogenous.[¹¹] In 24 months, nearly 60% of all cutaneous melanomas display mucosal metastases [^{6,9}] and Wakasugi [⁵] reported that time for metastases to the palatin tonsil ranged from 4 to 84 months after resection of primary lesion. In our case, palatin tonsil was the second place that mucosal melanoma metastases had occurred and diagnosed 12 months after the inguinal mass was resected.

To differentiate the primary and metastatic MM, detailed histopathological examination is required. The most important histopathological finding of primary melanoma is the presence of an intraepithelial neoplastic component (junctional activity) in the overlying or adjacent lateral mucosa [^{7,9}] however in metastatic melanoma the mucosa is intact.[^{9,12,13}] In our case, the medical history of the patient and the histopathological findings of intact overlying mucosa in all surgical specimen cross sections, we evaluated the lesion as metastatic malignant melanoma.

The prognosis of tonsillar and mucosal MM metastasis is different than the cutaneous melanomas. So it is important to perform detailed examination in tonsillar masses especially the ones with the previous melanoma history and you have to treat tonsillar melanomas aggressively in order to afford disease control.

CORRESPONDENCE TO

Hatice EMIR Turan Gunes Blv. 43. Sok. Tuna Canturk Sitesi 2. Blok No: 15 Oran, Ankara TURKEY. Email: emir.hatice@gmail.com GSM: +90 533 361 91 34 Fax number: +90 312 428 69 01

References

1. Gussack GS, Reintgen D, Cox E, Fisher SR, Cole TB, Seigler HF. (1983) Cutaneous melanoma of the head and neck: A review of 399 cases. *Arch Otolaryngol.* 109: 803-8.
2. Blatchford SJ, Koopmann CF, Coulthard SW. (1986) Mucosal melanoma of the head and neck. *Laryngoscope.* 96: 929-34.
3. Hoyt DJ, Jordan T, Fisher SR. (1989) Mucosal melanoma of the head and neck. *Arch Otolaryngol Head Neck Surg.* 115: 1096-9.
4. Patel SG, Prasad ME, Escrig M, Singh B, Shaha AR, Kraus DH, et al. (2002) Primary Mucosal Malignant Melanoma Of The Head And Neck. *Head Neck.* 24: 247-57.
5. Wakasugi S, Kageshita T, Ono T. (2001) Metastatic melanoma to the palatine tonsil with a favourable prognosis. *British Journal of Dermatology.* 145: 327-9.
6. Aydogan BL, Myers JN, Myers EN, Kirkwood J. (1996) Malignant melanoma metastatic to the tonsil. *Laryngoscope.* 106: 313-6.
7. Ramamurthy L, Nassar WY, Hasletom PS. (1995) Metastatic melanoma of the tonsil and the nasopharynx. *J Laryngol Otol.* 109: 236-7.
8. Andersen LJ, Berthelsen A, Hansen HS. (1992) Malignant melanoma of the upper respiratory tract and oral cavity. *J Otolaryngol.* 21:180-5.
9. Henderson LT, Robbins KT, Weitzner S. (1986) Upper aerodigestive tract metastases in disseminated malignant melanoma. *Arch Otolaryngol Head Neck Surg.* 112: 659-63.
10. Cauchois R, Laccourreye O, Carnot F, Brasnu D, Monteil JP. (1993) Metastatic tonsil melanoma. *Ann Otol Rhinol Laryngol.* 102: 731-4.
11. Peny M, Whyte A. (1981) Immunology of the tonsils. *Immunol Today.* 9: 414-21.
12. Nicolaides A, Fisher C, Evans PHR. (1989) Metastatic melanoma of the tonsil. *J Laryngol Otol.* 103: 890-2.
13. Lin D, Franc BL, Kashani-Sabet M, Singer MI. (2006) Lymphatic drainage patterns of head and neck cutaneous melanoma observed on lymphoscintigraphy and sentinel lymph node biopsy. *Head Neck.* 28: 249-55.

Author Information

Hatice Em?r

Ministry of Health, Ankara Training and Research Hospital 1. ENT Clinic

Zeynep K?z?lkaya Kaptan

Ministry of Health, Ankara Training and Research Hospital 1. ENT Clinic

Arzu Tuzuner

Ministry of Health, Ankara Training and Research Hospital 1. ENT Clinic

Sukran Akged?k

Ministry of Health, Ankara Training and Research Hospital Pathology Clinic