

Another Case of Liver Carcinosarcoma

A Mohamed, F Al Saif, H Fatani, F Emran, A Mohamed

Citation

A Mohamed, F Al Saif, H Fatani, F Emran, A Mohamed. *Another Case of Liver Carcinosarcoma*. The Internet Journal of Surgery. 2009 Volume 24 Number 2.

Abstract

Primary hepatic carcinosarcoma is rare, with only few adequately documented cases reported in the literature. We report a case of this rare tumor.

INTRODUCTION

Primary hepatic carcinosarcoma is a rare malignant hepatic tumor containing both carcinomatous and sarcomatous elements. We report a case of this rare tumour in an 82-year-old man who presented with recurrent attacks of right hypochondrial pain and loss of weight. We also review the literature for the features of these rare tumours.

CASE PRESENTATION

An 82-year-old man was referred to the hepatobiliary Surgery department at KFMC Riyadh, because of recurrent right hypochondrium pain associated with significant loss of weight (8kg in 3 month) and generalized fatigue. He was investigated at the referring hospital where he had an ultrasound, CT scan and MRI of the abdomen which showed a mass in the right lobe of the liver (figure 1, 2, 3 & 4).

Figure 1

Figure 1: Hepatic ultrasound showing a heterogeneous hypoechoic solid mass in the right lobe of the liver

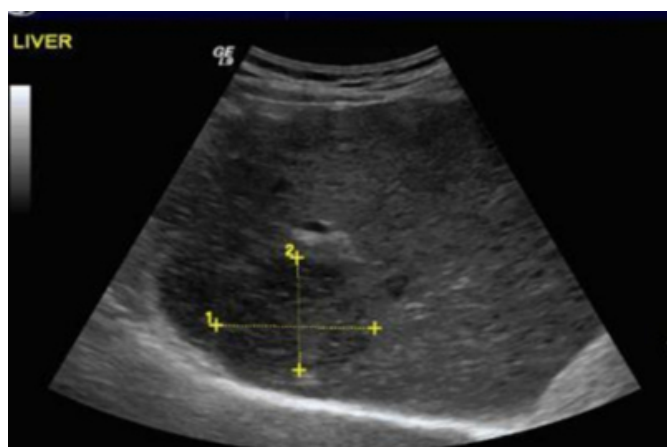

Figure 2

Figure 2: CT scan of the abdomen showing a heterogeneous hypodense lesion in the right lobe of the liver segments VII-VIII

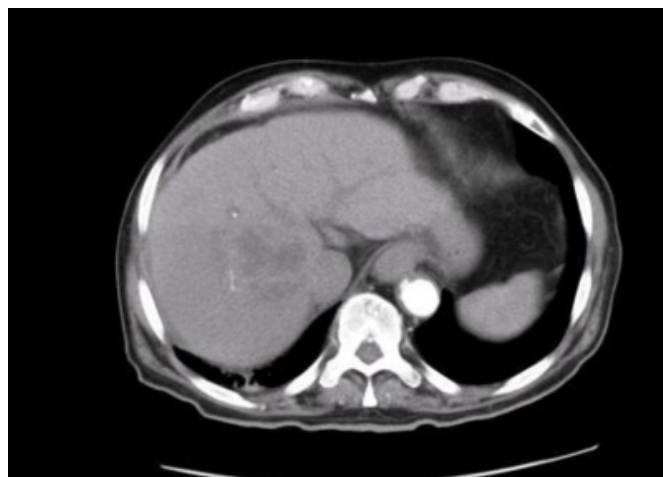

Figure 3

Figure 3: MRI-T2 showing a well defined hyperintense lesion in the right liver lobe in the segments VII-VIII

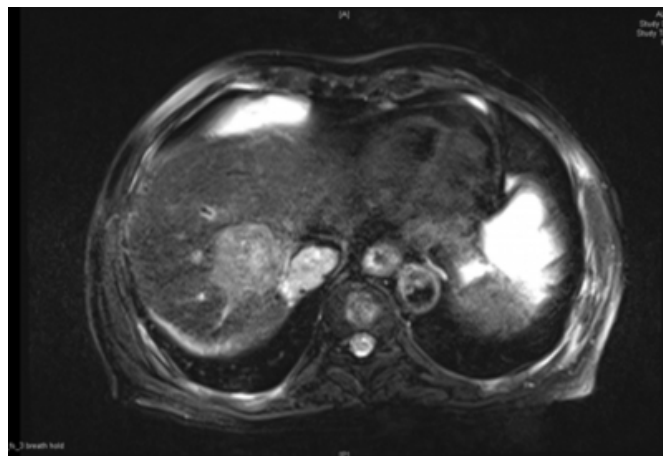
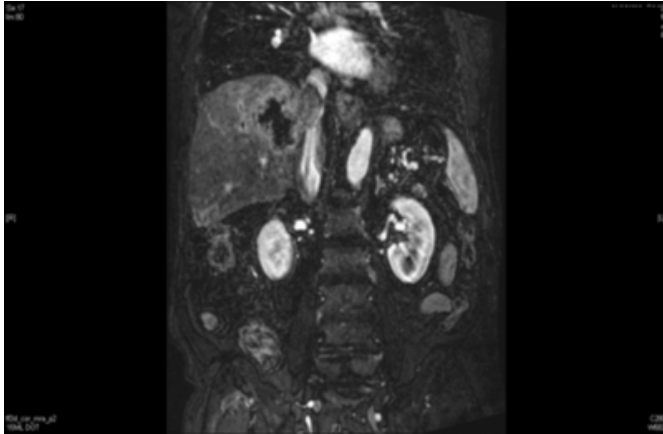


Figure 4

Figure 4: MRI (post-contrast T1 fat-suppressed delayed sequence) showing a peripherally enhanced lesion with necrotic core in the same segments of the right liver lobe with enhanced IVC tumor thrombus

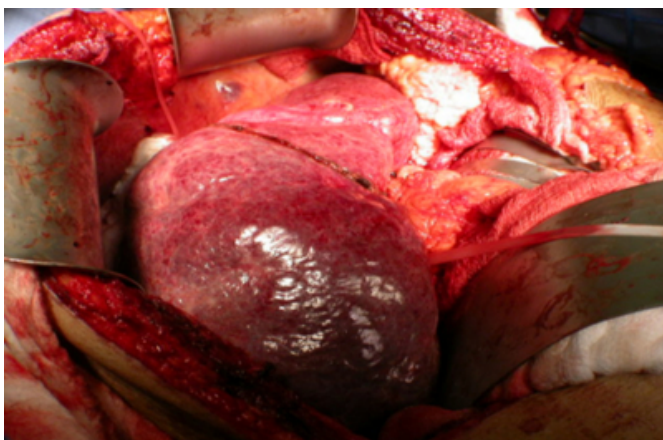

Ultrasound-guided biopsy was reported as liver sarcoma, most probably leiomyosarcoma. The patient was known to be a diabetic on oral hypoglycemics. On admission, he was not jaundiced or anaemic, with normal vital signs. Abdominal examination was normal apart from an enlarged liver (3-5 cm below the costal margin).

Laboratory investigation showed a hemoglobin of 13.4 g/dl, WBC of 6.67×10^3 , normal liver function test apart from low albumin (28 g%), and urea and electrolytes were normal. Alpha-fetoprotein was slightly elevated. After extensive pre-operative work-up the patient was taken for right trisegmentectomy. Intra-operatively the liver was enlarged and there was a small amount of ascitic fluid (figure 5).

Figure 5

Figure 5: An intra-operative photograph showing the gross appearance of the liver and the tumor in the right lobe



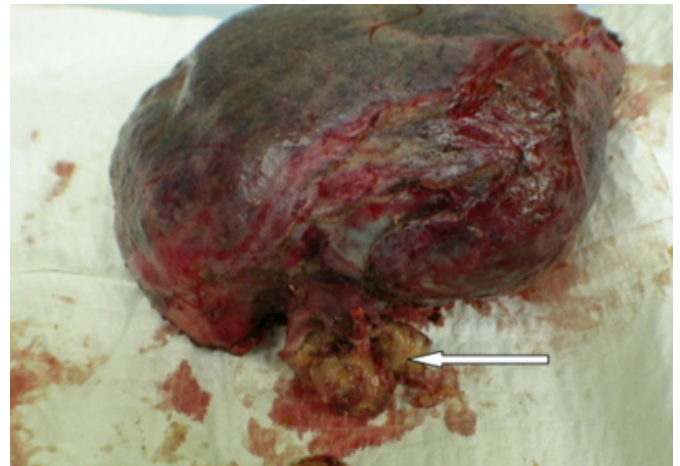
Intra-operative liver ultrasound showed no involvement of the left lobe of the liver and no diffuse liver metastasis.

Right trisegmentectomy was done together with excision of the inferior vena cava tumor extension with primary repair of the inferior vena cava.

The resected lobe of the liver measured about 18x15x5cm (figure 6).

Figure 6

Figure 6: The resected right lobe of the liver (the arrow points to the part of the tumor that was extending in the inferior vena cava)



Right trisegmentectomy specimen measuring 18 x 15 x 5cm the cut section showed an encapsulated white mass with central necrosis measuring 5 x 3.7 x 3.5cm. the mass showed two different components: a carcinomatous component (figure 7) which was positive for immuno stain epithelial markers CK and CK20 (figure 8) and negative for desmin, SMA, CK7 and vimentin, and a leiomyosarcoma component (figures 9 & 10) which was positive for immuno stain stromal markers SMA (figure 11), desmin (figure 12) and vimentin (figure 13), and negative for CK, CK20, CK7 and CD34.

The histological and the immunochemistry staining features of our cases satisfy the WHO definition of carcinosarcoma.

Figure 7

Figure 7: The carcinomatous component of the mass showing a poorly differentiated adenocarcinoma

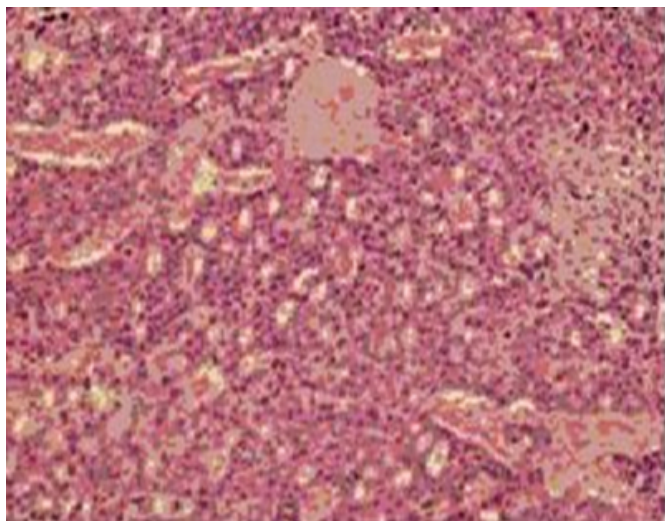


Figure 8

Figure 8: The carcinomatous part of the tumor positively stained with cytokeratin epithelial marker

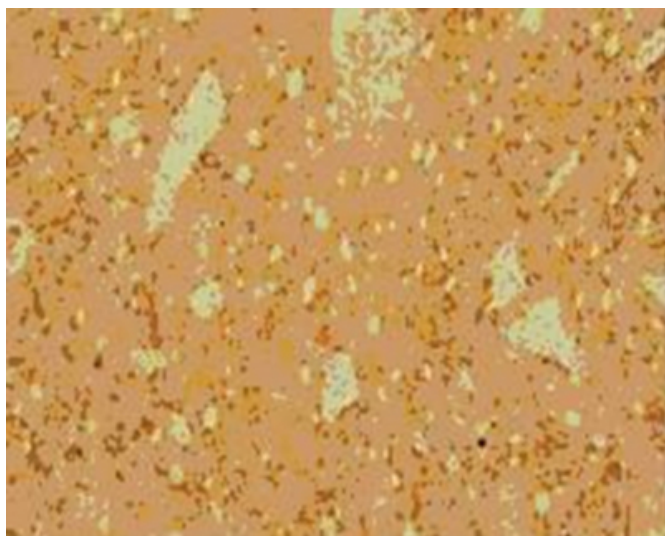


Figure 9

Figure 9: Spindle cells demonstrating the sarcomatous part of the tumor

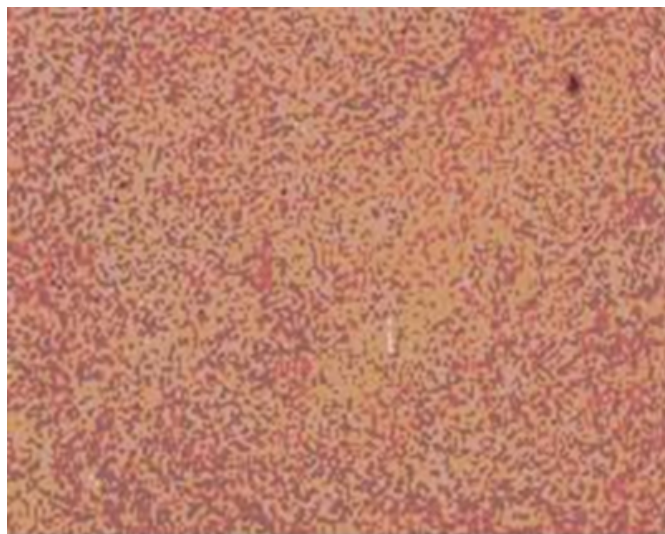


Figure 10

Figure 10: Showing the same finding as figure 9

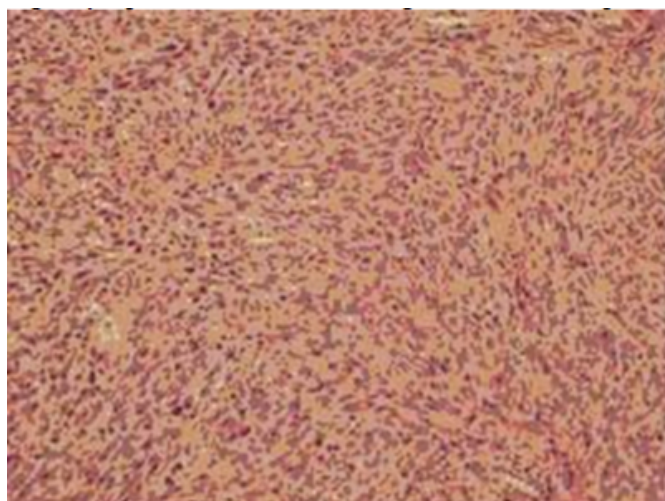


Figure 11

Figure 11: The sarcomatous part of the tumor positively stained with EMA

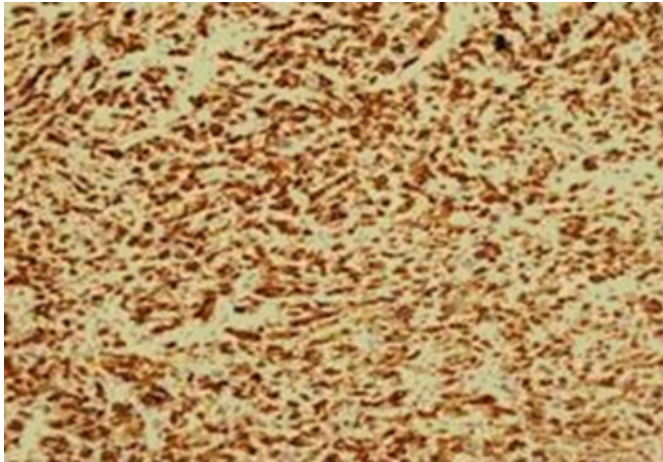


Figure 12

Figure 12: The sarcomatous part of the tumor positively stained with desmin




Figure 13

Figure 13: The sarcomatous part of the tumor positively stained with vimentin



DISCUSSION

The World Health Organization defined liver carcinosarcomas in 1974 as tumors containing both carcinomatous (either hepatocellular or cholangiocellular) and sarcomatous elements, including malignant mixed tumors (1).

Carcinosarcoma has numerous synonyms including: spindle cell carcinoma, pseudosarcoma, polypoid carcinoma, sarcomatoid carcinoma, and spindle cell variants of other usual carcinomas. The confusing terminology used to describe carcinosarcoma of the liver has caused uncertainty regarding the characteristics of these tumors (2).

Carcinosarcoma usually occurs in the ovaries, uterus, and urinary bladder (3, 4 and 5).

Primary hepatic carcinosarcoma is rare, with less than 20 adequately documented cases reported (2).

There is ongoing controversy regarding the pathogenesis of liver carcinosarcoma. Several authors argue that the tumor arises from a single totipotent stem cell which may differentiate into both carcinomatous and sarcomatous neoplasms (6). Other authors favor the stance that there is transformation of HCC into sarcoma (7).

In recent years, increasing evidence has supported the theory that carcinosarcoma is monoclonal in origin. The carcinomatous element is the driving force; the sarcomatous component is derived from the carcinoma or from a stem cell that undergoes divergent differentiation (8).

Liver carcinosarcoma usually occurs in old men with liver cirrhosis or fibrosis, and has a predilection for the right lobe of the liver (9, 10).

Most reports on primary liver carcinosarcoma are case reports lacking systematic report on clinical features and imaging findings of the tumor.

The clinical characteristics of these tumors include abdominal pain, fever, and jaundice. These symptoms can be followed by liver cirrhosis with negative or low serum alpha-fetoprotein levels (11).

On CT scan, most cases of liver carcinosarcoma show a single mass, round or oval in shape, without capsule, with a predilection for the right lobe. Plain CT scans show a hypodense to isodense or solid component with cystic change. Contrast CT scans show a mass with mixed density and variable enhancement (12).

Histologically, hepatic carcinosarcoma contains both carcinomatous (either hepatocellular or cholangiocellular) and sarcomatous elements, including malignant mixed tumors (13). The sarcomatous areas with malignant epithelial components were composed of variable malignant mesenchymal components, such as chondrosarcoma or osteosarcoma.

Immunohistochemically, cells from the carcinomatous elements express cytokeratin but not vimentin, whereas cells from the sarcomatous elements show the opposite staining pattern (14).

The outcome of patients with primary hepatic sarcoma depends primarily on tumor histology and the ability to achieve complete tumor resection. The prognosis for patients with primary hepatic carcinosarcoma is worse than for the majority of patients with hepatic sarcoma (2); however, the histological features, stage, and outcome of the reported cases indicate that this neoplasm generally pursues a highly aggressive and malignant biological course with rapid growth and wide local infiltration, leading to a poor prognosis. Radical surgery with adjuvant chemotherapy and close follow-up are necessary for the management of this disease (15).

SUMMARY

Liver carcinosarcomas are tumors containing both carcinomatous (either hepatocellular or cholangiocellular) and sarcomatous elements, including malignant mixed tumors. Primary hepatic carcinosarcoma is rare, with less than 20 adequately documented cases reported. It usually occurs in old men with liver cirrhosis or fibrosis, and has a predilection for the right lobe of the liver. Histology and immunochemistry play a major role in diagnosis. The disease is usually aggressive with rapid growth and wide local infiltration. The prognosis of patients with primary hepatic sarcoma depends primarily on tumor histology and the ability to achieve complete tumor resection.

DECLARATION

The authors declare no conflict of interest.

CORRESPONDENCE TO

Abbas AR Mohamed MBBS, FRCSI, FICS
Consultant General and Laparoscopic Surgeon
Department of Surgical Specialties King Fahad Medical city,
Riyadh, KSA Email: abbas_ar@hotmail.com

References

1. WANG Xi-wen, LIANG Ping, LI Hong-yan: Primary hepatic carcinosarcoma: a case report. *Chinese Medical Journal*; 2004; 117(10): 1586-1587.
2. Kwon JH, Kang YN, Kang KJ: Carcinosarcoma of the liver: a case report. *Korean J Radiol*; 2007; 8(4): 343-7.
3. Harris MA, Delap LM, Sengupta PS: Carcinosarcoma of the ovary. *Br J Cancer*; 2003; 88: 654-657.
4. Bodner-Adler B, Bodner K, Obermair A, et al.: Prognostic parameters in carcinosarcomas of the uterus: a clinico-pathologic study. *Anticancer Res*; 2001; 21: 3069-3074.
5. Baschinsky DY, Chen JH, Vadmal MS, et al.: Carcinosarcoma of the urinary bladder - an aggressive tumor with diverse histogenesis. A clinicopathologic study of 4 cases and review of the literature. *Arch Pathol Lab Med*; 2000; 124: 1172-1178.
6. Fayyazi A, Nolte W, Oestmann JW, et al.: Carcinosarcoma of the liver. *Histopathology*; 1998; 32: 385-387.
7. Kubosawa H, Ishige H, Kondo A, et al.: Hepatocellular carcinoma with rhabdomyoblastic differentiation. *Cancer*; 1988; 62: 781-786.
8. McCluggage WG: Malignant biphasic uterine tumours: carcinosarcomas or metaplastic carcinomas? *J Clin Pathol*; 2002; 55: 321-325.
9. Morise Z, Sugioka a, Mizoguchi Y, et al.: Carcinosarcoma of the liver: a case report with interesting histologic and immunohistochemical features. *J Gastroenterol Hepatol*; 2004; 19(8): 948-950.
10. She R, Szakacs J: Carcinosarcoma of the liver: a case report and review of the literature. *Arch Pathol Lab Med*; 2005; 129(6): 790-793.
11. Garcez-Silva MH, Gonzalez AM, Moura RAM, Linhares MM, Lanzoni VP, Trivino T: Carcinosarcoma of the liver: A case report. *Transplantation Proceedings*, 38, 1918-1919 (2006)
12. Shu RY, Ye M, Yu WY: A case of primary liver carcinosarcoma: CT findings. *Chin J Cancer*; 2010; 29(3): 346-8.
13. Nomura K, Aizawa S, Ushigome S: Carcinosarcoma of the liver. *Arch Pathol Lab Med*; 2000; 124: 888-890.
14. Jung Hyeok Kwon, Yu Na Kang, Koo Jeong Kang: Carcinosarcoma of the Liver: A Case Report. *Korean J Radiol*; 2007; 8: 343-347.
15. Sumiyoshi S, Kikuyama M, Matsubayashi Y, Kageyama F, Ide Y, Kobayashi Y, Nakamura H: Carcinosarcoma of the liver with mesenchymal differentiation. *World J Gastroenterol*; 2007; 13(5): 809-812.

Author Information

Abbas AR Mohamed, MBBS, FRCSI, FICS

Consultant General and Laparoscopic Surgery, Department of Surgical Specialties, King Fahad Medical City Riyadh, KSA.

Faisal Al Saif, MBBS, FRCSC

Consultant Hepatobiliary Surgeon, King Fahad Medical City, Riyadh, KSA

Hanadi A Fatani, MBBS

Assistant Consultant Histopathology, Department of Pathology, King Fahad Medical City, Riyadh, KSA

Fawaz Emran, MBBS, Arab Board

Assistant Consultant Hepatobiliary Surgery, Department of Surgical Specialty, King Fahad Medical City, Riyadh, KSA.

Asim A.E. Mohamed, MBBS

Swedish Board Histopathology & Cytology, Consultant Histopathology, Department of Pathology, King Fahad Medical City, Riyadh, KS A