

Feminizing Adrenal Adenoma Presenting As Isosexual Precocious Puberty

V Kaushal, K Rattan, V Kaushik, S Magu, S Kaushik

Citation

V Kaushal, K Rattan, V Kaushik, S Magu, S Kaushik. *Feminizing Adrenal Adenoma Presenting As Isosexual Precocious Puberty*. The Internet Journal of Pediatrics and Neonatology. 2006 Volume 7 Number 1.

Abstract

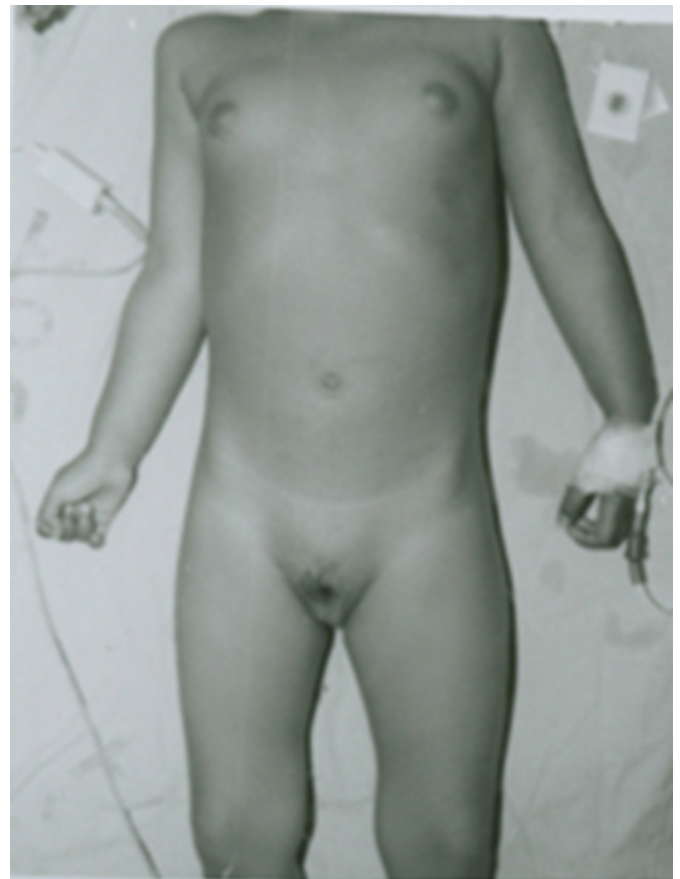Precocious puberty is appearance of secondary sexual characteristics, in Indian children, before the age of 8 years in girls and 9 years in boys.¹ In all forms of sexual precocity, the increased gonadal steroid secretion increases height velocity, somatic development, and the rate of sexual maturation.² If the precocious puberty is not related to hypothalamus or pituitary abnormality (i.e. central), it is called peripheral precocious puberty.^{1,2} Feminizing adrenal tumors causing precocious puberty in female children, are extremely rare and invariably malignant.^{3,4,5} We report a rare case of feminizing peripheral precocious puberty in a 3 year old female child due to a benign adrenal adenoma.

CASE REPORT

A three-year old female child presented with a 2 month history of bilateral breast development, bleeding per vaginum and pubic hair which had appeared 1 month previously. There were no complaints of deepening of voice, acne, or hirsutism. On physical examination, there was bilateral breast development and appearance of pubic hair, without clitoral enlargement or thickening of vaginal mucosa (Fig 1).

Figure 1

Figure 1: The patient at presentation showing gynaecomastia and pubic hair.

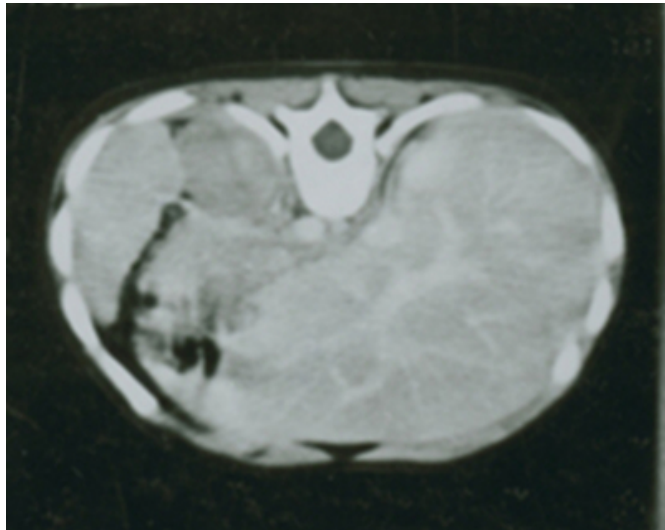


A wrist radiograph revealed a bone age of more than 3 years and less than 5 years. Ultrasonography of the abdomen

revealed a hypoechoic mass of 3.5 x 3.5cm size in left adrenal gland. Other abdominal organs and the uterus and adenexae were normal. An axial abdominal CRCT scan at the suprarenal level showed a hypodense mass 3.5cm X 4cm seen in the region of left adrenal and confirmed the above findings (Fig.2).

Figure 2

Figure 2: The preoperative CT scan of patient showing left adrenal tumor.



A CT scan of the skull was normal with no evidence of macroadenoma in the pituitary fossa. Systemic examination, complete hemogram and routine blood biochemistry were within normal limits. Serum estradiol levels were elevated (74 pg/ml; normal range 1-36 pg/ml). Urinary 17-ketosteroids were also elevated (99mg/24hr; normal range 0.3-1.3mg/24 hr.). The patient had marked elevation of plasma 17-alpha hydroxyprogesterone (12.7ng/ml; normal range Nil – 0.60 ng/ml). Plasma cortisol (3.70µgm/ml; normal range 5-25µgm/ml), LH (<0.07 mIU/ml; normal prepubertal <0.10-6.00 mIU/ml) and FSH levels (0.41 mIU/ml) were not elevated. A provisional diagnosis of left adrenal feminizing tumor was made and an exploratory laparotomy was performed. There was a 3.5cm diameter tumor in left adrenal gland, which was completely excised. The histopathological examination confirmed a benign adrenal cortical adenoma with insignificant mitotic activity. A final diagnosis of a benign feminizing left adrenal cortical adenoma was established. Six months after the operation the patient was well with normal secondary sexual characteristics. Postoperatively, the elevated urinary 17-ketosteroids returned to normal (0.17mg/24hr; normal range 0.3-1.3mg/24hr.). The post-operative serum estradiol levels were also normal (10pg/ml; normal range 10-36pg/ml).

DISCUSSION

There are three major types of sexual precocity: central, peripheral and combined central and peripheral type. If the sexual precocity results from premature reactivation of the hypothalamic LHRH, the condition is called true or central precocious puberty.^{1,2} If it results from extra-pituitary secretion of gonadotropins or gonadal steroids, independent of pulsatile LHRH stimulation, it is termed as pseudoprecocious or peripheral puberty.^{1,2} (e.g. because of adrenal adenoma etc.). The combined central and peripheral precocity sets in with the peripheral production of sex steroids, secondarily activating the hypothalamic – pituitary axis.^{1,2}

Adrenal adenoma is a benign neoplasm of adrenal cortical cells.¹ It may present with peripheral precocious puberty, because of functional autonomy.⁶ Adrenal adenomas usually produce syndromes of hypercortisolism and hyperaldosteronism but seldom produce adrenogenital syndromes.⁶ The prognosis of adrenal cortical adenoma that produces Cushing's syndrome is excellent but those producing hyperaldosteronism may not be as favorable.⁶ Adenomas that induce the adrenogenital syndrome have the least favorable outcome.⁶ In general, an adenoma usually does not exceed 5cm in the largest dimension. The tumor in presented above was 3.5 cm in diameter. Tumors larger than 6cm that produce adrenogenital syndromes are usually carcinomas.⁶

Just less than 10% of the adrenal tumors are feminizing, producing oestrogenic steroids.⁶ Adrenal adenoma associated virilization or feminization may be combined with hypercortisolism, or the tumor may secrete only estrogen or testosterone. In our patient the cortisol levels were normal. The elevated levels of estrogens in adrenal adenoma are usually unresponsive to endocrine manipulation, such as adrenocorticotrophic hormone stimulation or dexamethasone suppression and may be associated with elevated levels of other steroids as cortisol and 11-deoxycortisol.³

Feminization in girls, because of adrenal adenoma produces isosexual precocity in childhood, although regular menstruation is not a presenting feature.³ Our patient had occasional vaginal bleeding as the presenting symptom along with bilateral breast enlargement. Feminizing tumors of the adrenal gland are almost always malignant, with an equal preference for the left or right adrenal gland.⁴ Our patient had the rare distinction of having a feminizing, benign adrenal adenoma.

The definitive treatment of benign adrenal adenoma is surgical resection of the adrenal gland with the adenoma.^{1,2,7,8,9} Surgical resection of an adenoma is usually curative.^{2,3,6} The prognosis of feminizing tumors is poor, with little agreement to the optimal therapy.³ Surgical debulking with or without radiotherapy to the tumor bed is the first requirement.³ The post operative radiotherapy was not considered in our patient, as the tumor was completely excised, with histopathological confirmation of benign nature of tumor, with insignificant mitotic activity. Feminizing adrenal adenoma, usually, is not associated with regular menstrual bleeding. Irregular vaginal bleeding that occurs in few cases as in present case is attributed to withdrawal bleedig.¹⁰ If the excessive feminization is clinically problematic, tamoxifen may be cosmetically useful.³ Mitotane has been reported to be useful on occasion.³ At present, there is no effective tumoricidal agent for malignant adrenal cortical tumors.³

CONCLUSION

We have reported a rare case of feminizing adrenal cortical adenoma where the patient presented with vaginal bleeding, pubic hair appearance and bilateral breast development. The tumor was treated with complete excision. Postoperatively, the raised hormonal levels and secondary sexual characteristics returned to normal. The literature review has revealed that the feminizing adrenal tumors in children are invariably malignant, yet our patient had a benign tumor. However, as per the current recommendation, even histologically benign tumors should have a long follow up to exclude malignancy.

CORRESPONDENCE TO

Vidhu Kaushik 340,94th street Bay Ridge Brooklyn, New York USA 11209 Email: vidhukaushik@yahoo.com

References

1. Khandekar S, Desh RJ. Clinical and hormonal studies in precocious puberty. *Ind J Pediatr* 1990; 57: 411-19.
2. Melvin M, Grunback, Dennis M. Puberty: Ontogeny, Neuroendocrinology, Physiology, and Disorders. In: Wilson JD, Foster DW, editors. *William's textbook of endocrinology*. 8th ed. WB Saunders Company: 1992. p. 1139-1222.
3. Grossman A. Adrenal tumors. In: Peckham M, Pinedo HM, Veronesi U, editors. *Oxford textbook of oncology*. Oxford: Oxford medical Publishers: 1996. p. 2137-45.
4. Luton JP, Kuhn JM, de Gennes JL, Paulian b, Mahoudeau J, Laudat MH, et al. Adrenal adenoma secreting exclusively estrogens in a woman during her reproductive period. 11-year follow-up. *Presse med* 1984 Jan 14; 13(1): 23-6.
5. Comite F, Schiebinger RJ, Albertson BD, Cassorla FG, Vander VK, Cullen TF, et al. Isosexual precocious pseudopuberty secondary to a feminizing adrenal tumor. *J Clin Endocrinol Metab* 1984 Mar; 58(3): 435-40.
6. Norton JA, Le HN. Adrenal tumors. In: DeVita VT, Hellman S, Rosenberg SA, editors. *Cancer Principles and practice of oncology*. Philadelphia: Lippincott Williams and Wilkins: 2001. p. 1770-87.
7. Daneman A, Chan HS, Martin J. Adrenal carcinoma and adenoma in children: a review of 17 patients. *Pediatr Radiol* 1983; 13(1): 11-8.
8. Agrons GA, Lonergan GJ, Dickey GE, Perez-Monte JE. Adrenocortical neoplasms in children: radiologic-pathologic correlation. *Radiographics* 1999 Jul-Aug; 19(4): 989-1008.
9. Zia-ul-Miraj M, Usmani GN, Yaqub MM, Ashraf S. Cushing's syndrome caused by an adrenal adenoma. *J Pediatr Surg* 1998; 33(4): 644-6.
10. Migeon CJ, Lanes RL. Adrenal cortex: Hyperfunction and hypofunction. In: Lifshitz F, editor. *Pediatric Endocrinology*. New York: Marcel Dekker Inc: 1996. p.321-45.

Author Information

Vivek Kaushal

Department of Radiotherapy, Pt. B.D. Sharma, Post Graduate Institute of Medical Sciences

Kamal Nain Rattan

Department of Pediatric Surgery, Pt. B.D. Sharma, Post Graduate Institute of Medical Sciences

Vidhu Kaushik

Department of Pathology, Pt. B.D. Sharma, Post Graduate Institute of Medical Sciences

Sarita Magu

Department of Radiology, Pt. B.D. Sharma, Post Graduate Institute of Medical Sciences

Shubhi Kaushik

Department of Pathology, Pt. B.D. Sharma, Post Graduate Institute of Medical Sciences