

# Low anorectal malformation in females without fistula: A rare entity

V Upadhyaya, A Gangopadhyaya, A Pandey, D Gupta, A Upadhyaya

## Citation

V Upadhyaya, A Gangopadhyaya, A Pandey, D Gupta, A Upadhyaya. *Low anorectal malformation in females without fistula: A rare entity*. The Internet Journal of Surgery. 2006 Volume 12 Number 1.

## Abstract

Anorectal malformations (ARM) are one of the most common congenital defects. Male and female patients are equally affected. Low anorectal malformations are common in males as well in females. Most of the male low ARM present without fistula. Low ARM in female without any fistula is very rare. We are presenting 3 cases of low ARM in female without fistula (anocutaneous, vestibular and vaginal). All these patients were treated by cut-back anoplasty. None of the patients were associated with any other congenital anomaly. Postoperative results were excellent.

## INTRODUCTION

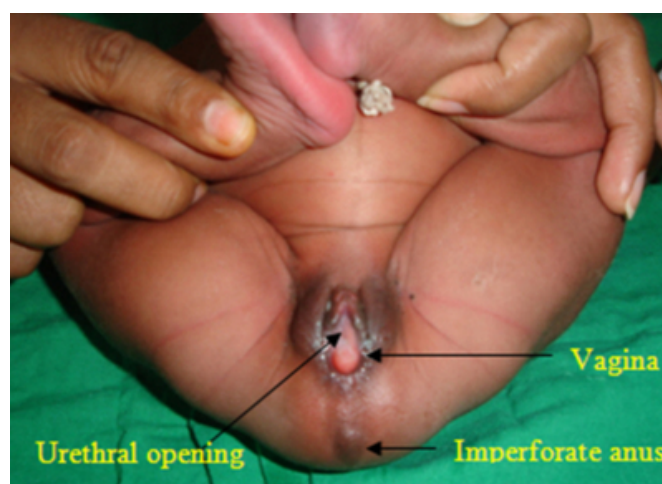
Imperforate anus has been a documented anomaly since antiquity. It has an incidence of 1 in 4000 newborns. Anorectal malformations affect all racial, social, cultural and economic groups equally. Low anorectal malformations without fistula are common in males whereas low anorectal malformations with fistula are common but low anorectal malformations without fistula are very rare in females. It has been consistently shown that low anorectal malformations predominate in female children<sup>1,2</sup> (perineal fistulas, anteriorly placed anus, and ano-vestibular fistula). Low anorectal malformation of females without fistula is very rare and accounts for less than 1% cases of ARM in females. In one study, low ARM without fistula in females was reported up to 4.5%<sup>3</sup>, whereas in one large series from India not a single case of low ARM without fistula in females was reported<sup>4</sup>. We are presenting three cases of low anorectal malformation without fistula.

## CASE HISTORY

All the patients presented at 2-4 days of age with absence of the anal opening (Fig 1). On careful examination no fistulous opening was present in the perineum or in the fourchette. Abdominal distension was present. All the patients were operated by cut back anoplasty. The patients are in regular follow-up and anal dilation.

## Figure 1

Figure 1: Showing low anorectal malformation in a female without fistula.



## DISCUSSION

ARMs occur quite commonly<sup>5, 6</sup>. Many systems of classification have been suggested; however, the terms high and low have been broadly recognized and applied worldwide. Pena reports the most common lesion to be ARM with recto-urethral fistula in males and cloacae amongst females<sup>7</sup>; however, the most commonly seen defect in the Liverpool series was anocutaneous fistula<sup>8</sup> and rectovestibular followed by perineal fistulas type of malformation in other series<sup>9</sup>. In males, high defects were more common whereas intermediate defects were commonest in females in the reports from India<sup>4</sup>. We are presenting three cases of low anorectal malformations in

females without any fistula, their management and follow-up. The importance of this article is rarity of the disease, and such case has not been reported previously.

## **CONCLUSION**

Low anorectal malformation without fistula in females is a very rare entity; management is very simple.

## **CORRESPONDENCE TO**

Dr. Vijai D. Upadhyaya Department of Pediatric Surgery  
IMS, BHU Varanasi, 221005 U.P. India  
upadhyayavj@rediffmail.com

## **References**

1. Okada A, Kamata S, Imura K, Fukuzawa M, Kubota A, Yagi M et al. Anterior sagittal anorectoplasty for rectovestibular and anovestibular fistula. J. Pediatr. Surg. 1992 27(1): 85-8
2. Hashmi MA. Anorectal malformations: a study of 104 patients. Pak. Armed Forces Med. J. 1992; 42(1): 5-11
3. Anorectal malformations in female children - 10 years experience: M. A. Hasmi and S. Hasmi: .R.Coll.Surg.Edinb., 45, June 2000, 153-158
4. Bhargava Pranshu, Mahajan JK, Kumar Ajay. Anorectal malformations in children. J Indian Assoc Pediatr Surg 2006;11:136-139
5. Gupta DK, Charles AR, Srinavas M. Pediatric Surgery in India - A specialty come of age. Pediatr Surg Int 2002;18:649-52
6. Saaul DB, Harrison EA. Classification of Anorectal malformations - Initial approach, diagnostic tests and colostomy. Semin Pediatr Surg 1997;16:187-95
7. Pena A. Anorectal Malformations. Semin Pediatr Surg 1995;4:35-47.
8. Cook RC. Anorectal malformations, In: Neonatal Surgery. Lister J, Irving IM (editors). Butterworth Heinmann: 1991. p. 547-70
9. Ahmad Khaleghenejad, Mahmood Saeeda. The results of posterior sagittal anorectoplasty in anorectal malformations: Archives of Iranian Medicine: 2005; (8), 4: 272-76

**Author Information**

**Vijay D. Upadhyaya, M.S.**

Senior Resident, Pediatric Surgery, IMS

**A. N. Gangopadhyaya, M.Ch.**

Professor, Pediatric Surgery, IMS, BHU

**Anand Pandey, M.S.**

Senior Resident, Pediatric Surgery, IMS

**D. K. Gupta, M.Ch.**

Professor, Pediatric Surgery, IMS, BHU

**Ashish Upadhyaya, M.A.**

Statistical Research Officer, AIIMS