

# Episodic Painful Oculomotor Nerve Palsy From An Orbital Metastasis Of Oesophageal Adenocarcinoma

J Tysome, J Kanagalingam, W Grant

## Citation

J Tysome, J Kanagalingam, W Grant. *Episodic Painful Oculomotor Nerve Palsy From An Orbital Metastasis Of Oesophageal Adenocarcinoma*. The Internet Journal of Otorhinolaryngology. 2005 Volume 4 Number 2.

## Abstract

Painful oculomotor nerve palsy is most commonly due to posterior communicating artery aneurysms. It is usually progressive. Gastrointestinal metastases to the orbit are rare. We present a 75 year old lady who presented with episodic partial left oculomotor nerve palsy one year following neoadjuvant chemotherapy and surgical resection of an oesophageal adenocarcinoma. Endoscopic transthemoidal biopsy identified metastatic oesophageal adenocarcinoma in the orbit. This is the first description of a metastatic tumour to the orbit presenting in this manner and also demonstrates the use of the transthemoidal approach for medial orbital biopsy where direct ophthalmological approaches have failed.

## INTRODUCTION

Gastrointestinal adenocarcinoma metastasising to the orbit represents 5 % of orbital metastases [1]. There are several reported cases of metastatic gastric adenocarcinoma [2,3,4,5] but only 3 of oesophageal adenocarcinoma metastasising to the orbit [1,6,7].

Orbital metastases commonly present with ophthalmoplegia, proptosis, exophthalmos and ptosis [1]. Pain and diplopia are uncommon. Painful oculomotor palsy is seen in enlargement or rupture of intracranial aneurysms, most commonly of the posterior communicating artery. Transient or spontaneously reversible oculomotor nerve palsies resulting from intracranial aneurysms are rare [8]. Intermittent painless oculomotor nerve palsy can be caused by myasthenia gravis. An intermittent painful eye with partial third nerve palsy due to an orbital metastasis has not been described. We report the first case to present in this manner, which is also the fourth case of oesophageal adenocarcinoma metastasising to the orbit.

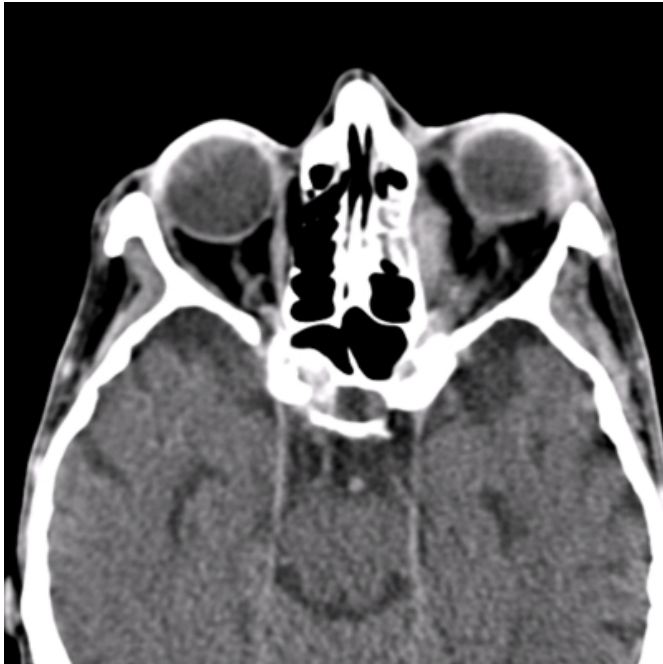## CASE REPORT

A 65 year old lady was diagnosed with a T3 N0 adenocarcinoma of the lower oesophagus. This was treated with neoadjuvant 5-fluorouracil and cisplatin followed by an oesophagogastrectomy. The lateral circumferential margin was close at 0.75 cm and therefore postoperative radiotherapy was given (45 Gy in 20 fractions). Two months later, the patient presented to the ophthalmologists with a

history of 4 episodes of pain, ptosis and diplopia of the left eye. Each episode lasted for 3 to 7 days and resolved spontaneously. Examination revealed normal visual acuity, no anisocoria and no enophthalmos. Pupillary responses were intact. A Magnetic Resonance Imaging (MRI) scan of brain and orbits found no posterior communicating artery aneurysm and no orbital or intracerebral space occupying lesion. The patient was reviewed by the neurology team who suggested the possibility of paratrigeminal neuralgia or Raeder's syndrome or an introrbital mass. A Computed Tomography (CT) scan 4 months later revealed a left medially situated intraorbital mass suggestive of a metastasis (Fig 1 a,b).

**Figure 1**

Figure 1a: Axial CT scan showing soft tissue medially in the left orbit.



**Figure 2**

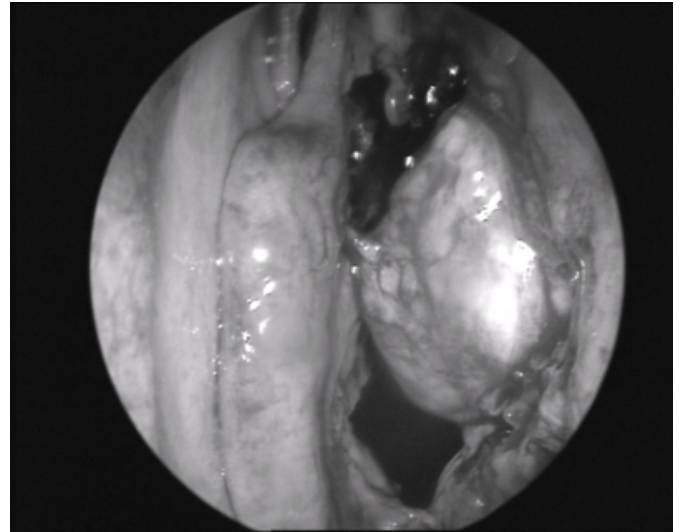
Figure 1b: Coronal CT scan showing soft tissue superomedially in right orbit and sclerotic expansion of the orbital roof.



A biopsy of the lesion taken by the ophthalmology team using an upper eyelid crease incision under local anaesthesia was non-diagnostic. The patient was referred to our otolaryngology team for assessment. We performed an endoscopic transethmoidal biopsy of the lesion (Fig 2).

**Figure 3**

Figure 2: Intraoperative endoscopic video of orbital mass following left ethmoidectomy



Histology showed features consistent with oesophageal adenocarcinoma, similar to that of the original primary. Further imaging revealed a 5.5cm liver metastasis in segment VII. The patient went on to receive palliative radiotherapy to the left orbit (20 Gy in 5 fractions).

## DISCUSSION

Tumours that metastasise to the orbit are relatively uncommon accounting for 7 – 12 % of all orbital tumours [9,10]. The origins of these tumours are most commonly breast, prostate and lung [1,9,10]. A comprehensive review of orbital metastases discovered that most are solitary and occur in elderly patients with a known primary tumour [1]. They found that 22 of 469 cases of metastatic carcinoma to the orbit reported are gastrointestinal in origin. Of these only three are oesophageal tumours [1,6,7]. This in itself makes this case unusual. However, the unique feature of this case is the manner of presentation of the patient.

Although ptosis is a common presenting symptom of orbital metastases, pain is experienced in 17 % of patients and diplopia in just 9 % [1]. The combination of pain, diplopia and ptosis is most unusual and the episodic nature of their presentation, with complete resolution between episodes, is unreported. The differential diagnosis includes a posterior communicating artery aneurysm, diabetes and paratrigeminal neuralgia, which is also known as Raeder's syndrome.

Expanding or ruptured posterior communicating artery aneurysms commonly present with a severe headache and oculomotor nerve palsy. The pupil is usually involved. This

is of course a neurosurgical emergency. Recovery of this palsy is known to occur after early surgical clipping of the aneurysm [8], although pre-operative resolution has been reported [11]. A case of painful episodic oculomotor palsy due to a supraclinoid aneurysm has been described [12]. This is clearly a rare phenomenon, but was an important differential diagnosis to consider in our patient. Pain is observed in some oculomotor nerve palsies due to diabetic microvascular disease [13]. These cases are more likely to have pupillary sparing. There are cases reported of an episodic oculomotor palsy due to diabetes, but none associated with pain [14,15].

Cyclical oculomotor palsy is seen in patients with ocular neuromyotonia. This is a rare clinical entity, most of which have been in patients following skull base radiotherapy [16, 17, 18]. It is characterized by spontaneous spasm of ocular muscles resulting in paroxysmal diplopia and strabismus. This is however painless.

Raeder's syndrome or paratrigeminal neuralgia is another rare condition where there are mixed features of trigeminal nerve pathology and oculosympathetic impairment, with or without other cranial nerve lesions [19]. There is neuralgic pain in the trigeminal nerve distribution associated with ptosis and or miosis, but not anhidrosis. It is facial sweating which differentiates this condition from Horner's syndrome associated with a painful eye, where anhidrosis is present. This may be seen following carotid dissection or in severe internal carotid artery stenosis [20,21]. Raeder's syndrome may be due to pathology in the middle cranial fossa where the oculomotor and abducent nerves pass close to the trigeminal nerve [22]. One of Raeder's original five reported cases had a painful pupil with ptosis and intermittent diplopia [19]. However, in our case all three symptoms were intermittent together.

Diagnosis of orbital metastases is made by a combination of a characteristic history, thorough ocular and general examination, orbital imaging and tissue biopsy. Histological diagnosis can be made by fine needle aspiration biopsy or open biopsy. In this case the failure to gain an adequate biopsy using an upper eyelid incision necessitated an alternative method. A direct transcuruncular approach to this lesion outside the muscle cone could have been carried out by an oculoplastic surgeon [23]. The endoscopic transthemoidal approach to the medial orbit is an indirect approach which can be used by otolaryngologists experienced in endoscopic sinus surgery. A combined

transnasal endoscopic and transcuruncular approach for orbital decompression for thyroid related eye disease and subperiosteal abscess drainage has been described [24,25]

Oesophageal adenocarcinoma metastasising to the orbit is rare. Transthemoidal endoscopic orbital biopsy is a method which can be considered for biopsy of medially situated intraorbital lesions. In cases presenting with episodic painful partial oculomotor nerve palsy, posterior communicating artery aneurysm should be excluded and in patients with a history of malignancy, an introrbital metastasis considered.

## CORRESPONDENCE TO

James Tysome 2 Catherine Grove, London SE10 8BS E-mail: james\_tysome@yahoo.com Tel: +44 780 371 0935

## References

1. Shields JA, Shields CL, Brotman HK, Carvalho C, Perez N, Eagle RD Jr: Cancer metastatic to the orbit: the 2000 Robert M. Curts Lecture. *Ophthalmol Plast Reconstr Surg* 2001;17:346-354.
2. Van Gelderen WF: Gastric carcinoma metastases to extraocular muscles. *J Comput Assist Tomogr* 1999;17:499-500.
3. Singer MA, Warren F, Accardi F, Sabatini M, D'Amico RA: Adenocarcinoma of the stomach confirmed by orbital biopsy in a patient seropositive for human immunodeficiency virus. *Am J Ophthalmol* 1990;110:707-709.
4. Henderson JW, Campbell RJ, Farrow GM, et al.: Metastatic carcinomas; in *Orbital tumours*. 3rd ed. New York, Raven Press, 1994, pp 361-376.
5. Lekse JM, Zhang J, Mawn LA: Metastatic gastroesophageal junction adenocarcinoma to the extraocular muscles. *Ophthalmology* 2003;110:318-321.
6. Collins MJ, Wojno TH, Grossniklaus HE: Metastatic esophageal carcinoma to the orbit. *Am J Ophthalmol* 1999;127:228-229.
7. Seretan EL: Metastatic adenocarcinoma from the stomach to the orbit. *Arch Ophthalmol* 1981;99:1469.
8. Bateman DE, Saunders M: Cyclic oculomotor palsy: description of a case and hypothesis of the mechanism. *J Neurol Neurosurg Psychiatry* 1983;46:451-453.
9. Shields JA, Shields CL, Scartozzi R: Survey of 1264 patients with orbital tumors and simulating lesions: The 2002 Montgomery Lecture, part 1. *Ophthalmology* 2004;111:997-1008.
10. Font RL, Ferry AP: Carcinoma metastatic to the eye and orbit III. A clinicopathologic study of 28 cases metastatic to the orbit. *Cancer* 1976;38:1326-1335.
11. Hamer J: Prognosis of oculomotor palsy in patients with aneurysms of the posterior communicating artery. *Acta Neurochir (Wien)*;1982 66:173-185.
12. Greenspan BN, Reeves AG: Transient partial oculomotor nerve paresis with posterior communicating artery aneurysm. A case report. *J Clin Neuroophthalmol* 1990;10:56-58.
13. Sadun AA: Neuro-ophthalmic manifestations of diabetes. *Ophthalmology* 1999;106:1047-1048.
14. Miller NR, Moses H: Transient oculomotor nerve palsy. Association with thiazide-induced glucose intolerance. *JAMA* 1978;240:1887-1888.

15. Roberts DK: Bilateral monocular diplopia secondary to occult diabetes mellitus. *Optom Vis Sci* 1991;68:743-746.
16. Miller NR, Lee AG: Adult-onset acquired oculomotor nerve paresis with cyclic spasms: relationship to ocular neuromyotonia. *Am J Ophthalmol* 2004;137:70-76.
17. Yuruten B, Ilhan S: Ocular neuromyotonia: a case report. *Clin Neurol Neurosurg* 2003;105:140-142.
18. Loewenfeld IE, Thompson HS. Oculomotor paresis with cyclic spasms. A critical review of the literature and a new case. *Surv Ophthalmol* 1975;20:81-124.
19. Raeder JG: "Paratrigeminal" paralysis of the oculo-pupillary sympathetic. *Brain* 1924;47:149-158.
20. Hollinger P, Sturzenegger M: Painful oculomotor nerve palsy - A presenting sign of internal carotid artery stenosis. *Cerebrovasc Dis* 1999;9:178-181.
21. Balcer LJ, Galetta SL, Yousem DM, Golden MA, Asbury AK: Pupil-involving third-nerve palsy and carotid stenosis: rapid recovery following endarterectomy. *Ann Neurol* 1997;41:273-276.
22. Goadsby PJ. Raeder's syndrome [corrected]: Paratrigeminal paralysis of the oculopupillary sympathetic system. *J Neurol Neurosurg Psychiatry* 2002;72:297-299.
23. Graham SM, Thomas RD, Carter KD, Nerad JA. The transcaruncular approach to the medial orbit. *Laryngoscope* 2002;112:986-989.
24. Graham SM, Carter KD. Combined-approach orbital decompression for thyroid-related orbitopathy. *Clin Otolaryngol* 1999;24:109-113.
25. Pelton RW, Smith ME, Patel BC, Kelly SM. Cosmetic considerations in surgery for orbital subperiosteal abscess in children: experience with a combined transcuruncular and transnasal endoscopic approach. *Arch Otolaryngol Head Neck Surg* 2003;129:652-655.

**Author Information**

**James R. Tysome, MA MRCS**

Department of Otolaryngology - Head and Neck Surgery, Charing Cross Hospital

**Jeevendra Kanagalingam, MA, MRCS**

Department of Otolaryngology - Head and Neck Surgery, Charing Cross Hospital

**William E. Grant, MCh FRCS (ORL)**

Department of Otolaryngology - Head and Neck Surgery, Charing Cross Hospital