

# A Case of Posterior Reversible Encephalopathy Syndrome (P.R.E.S.)

G Merra, A Dal Lago, L Natale, E Gaetani, A Caricato, A Cianfoni, P Pola, G Gasbarrini, A Gasbarrini, G Ghirlanda

## Citation

G Merra, A Dal Lago, L Natale, E Gaetani, A Caricato, A Cianfoni, P Pola, G Gasbarrini, A Gasbarrini, G Ghirlanda. *A Case of Posterior Reversible Encephalopathy Syndrome (P.R.E.S.)*. The Internet Journal of Neurology. 2008 Volume 11 Number 2.

## Abstract

Posterior reversible encephalopathy syndrome is a proposed cliniconeuroradiological entity characterized by several symptoms of different aetiologies. The most important symptoms are headache, confusion, seizures, cortical visual disturbances or blindness, etc. There are three theories for PRES. The aetiology of PRES in this patient remains unclear but it may be related to a pharmacotoxic cause (abuse of drugs) because symptoms including altered mental function, visual loss, stupor and seizures are specific of acute encephalopathy based on treatment with immunosuppressive drugs. The syndrome should be promptly recognized, since it is reversible and readily treated by controlling blood pressure and, based on our experience, decreasing the dose of NSAIDs and eliminating the use of drugs, such as those used by our patient.

## INTRODUCTION

Posterior reversible encephalopathy syndrome is a proposed cliniconeuroradiological entity characterized by several symptoms of different aetiologies<sup>2,3</sup>. The most important symptoms are headache, confusion, seizures, cortical visual disturbances or blindness<sup>6</sup> and, rarely, other focal neurological signs. There are many known causes such as hypertension, pre-eclampsia/eclampsia, tacrolimus or cyclosporin A neurotoxicity, uraemia and porphyria, but there are many other unknown causes too<sup>1</sup>.

In this article we report the case of a patient with PRES whose blood pressure was highly elevated, for which the aetiology could be toxic based.

## CASE REPORT

The patient was a 46-year-old woman, a housewife and heavy smoker (40/50 cigarettes a day), drinking 7-8 cups of coffee a day. She reported an irregular menstrual cycle for about the last 6 months. The most important factor shown by the anamnesis was a familiarity with arterial hypertension (father, mother, a brother and a sister). She reported two episodes of extrauterine pregnancies 20 years and 12 years earlier and 10 laparoscopic operations in the past for reconstruction of the uterine tubes and artificial insemination. A year and a half ago she was diagnosed with

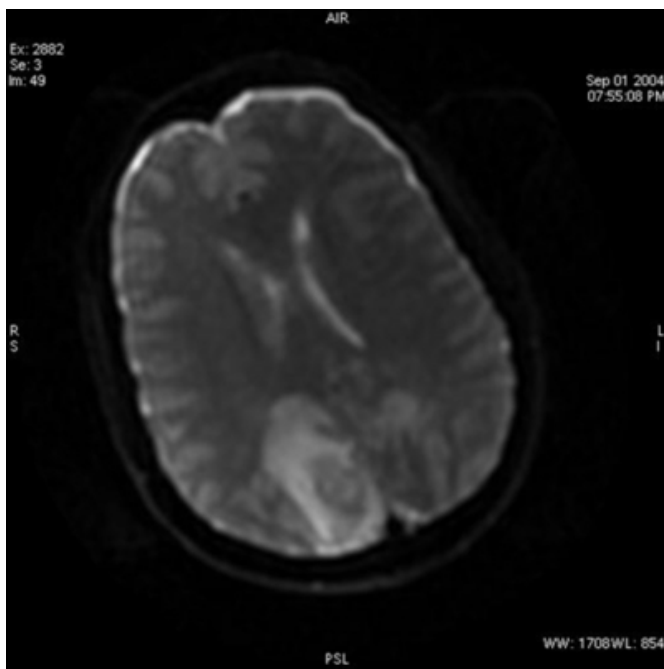
multinodular goitre, in treatment with levothyroxine (125 mcg/day). A short while before the pathological event in question she reported the use or abuse of NSAIDs and dieting products (diuretics, metformin, phendimetrazine, potassium clorazepate).

When the symptoms first appeared, characterised by an intense headache (with no improvement after taking Nimesulide 200 mg), vomiting and dizziness, she went to the casualty department of a local hospital and was hospitalised with the diagnosis of possible "meningitis". She underwent an encephalon CT, which was negative. The symptomatology was repeated after 2 days and after 4, but this time with the appearance of generalised tonic-clonic seizures, so she was transferred to the intensive-care unit. After a further 3 days a brain NMR was carried out showing "T2 hyperintensity sited in the left posterior cerebellar and bilaterally in the occipital-parietal region" and, during the same night, she suffered a new epileptic seizure treated with Midazolam + Fenobarbital 200 mg IV. She was then admitted to our University General Hospital. From the neurological objective examination the patient appeared soporose, respondent to painful stimuli, capable of making simple movements, restless and suffering and complained of headache and cervicalgia. Cardiac action was rhythmic at 58 bpm and the abdomen was flat and soft, with good

peristalsis. The arterial pressure, despite treatment with Clonidine IV, remained persistently at 220/110 mmHg, so the patient was transferred to the intensive-care unit. The results of the haematochemical examinations, with the exception of WBC (16,000), pH 7.475, Potassium 2.7 mEq/l and CK 402 UI/l, were normal. An electroencephalographic examination showed “high voltage slow activity, bihemispheric, with no significant occurrences on the side”. During her stay in hospital, her arterial pressure levels were > 240/130 mmHg. So an NMR examination of the cranium was carried out with a diagnosis of: “extensive areas of altered signal, cortical and subcortical bilateral parieto-occipital and left cerebellar, attributed to vasogenic oedema, excluded without doubt the ischemic hypothesis, no sign of venous sinus thrombosis, picture attributed to PRES based on hypertension with loss of cerebral autoregulation (Fig. 1).

### Figure 1

Figure 1: Magnetic resonance imaging of the brain with T2 hyperintensity sited in the left posterior cerebellar and bilaterally in the occipital-parietal region with signes of vasogenic oedema.



The cranium CT showed: “widespread swelling of the cerebral parenchyma with obliteration of the convexity sulci and, essentially, of all of the basal cisterns, no evident acute intracranial haemorrhages, no cerebral hernias. The size of the ventricular system was unchanged compared to the MR control, as were the hypodense alterations of the subcortical and deep white matter of the occipital lobe”. An ultrasound scan and a Doppler scan of the kidneys and the suprarenal glands were carried out which showed: “kidneys within

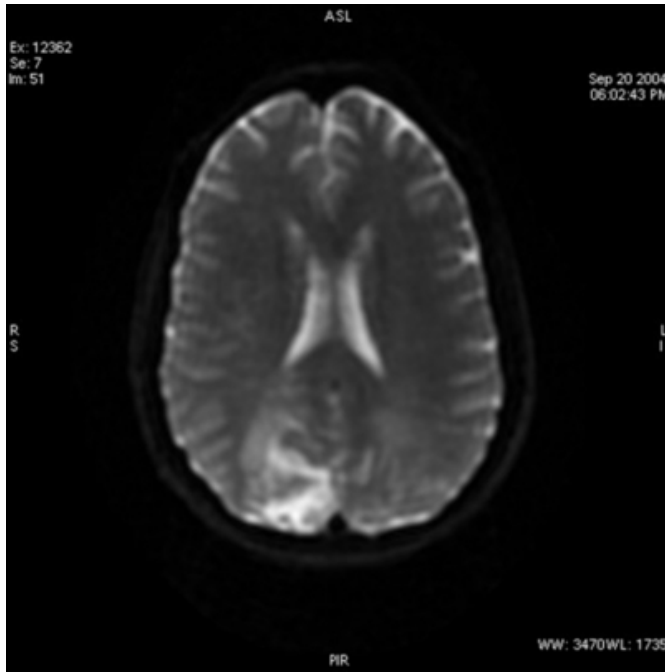
limits in terms of site, form, size and structural characters, parenchymal thickness within limits, no dilation of the calico-pyelic cavities, intraparenchymal vascular recordings were within the norm, fully explorable right renal artery, with regular Doppler recordings, partially explorable left renal artery with blood flow velocity recordings within the norm, no suprarenal space-occupying lesions”. A new EEG showed: “widespread slow anomalies, associated with widespread parossistic anomalies with a correlated medical history of axial hypertone” and an echocardiogram showed: “left ventricular hypertrophy, left atrium and right sections within limits, negligible mitral and tricuspidal regurgitation”.

During her stay in the intensive-care unit, the patient underwent numerous other laboratory-instrumental tests (e.g. haematochemical, virologic markers, autoimmune patterns). A new CT scan then showed: “no significant changes; in particular the diffuse hypodensity bilaterally affecting the posterior parieto-occipital white matter appeared unchanged, as was the morphological volumetry of the ventricular system, the convexity sulci and the base cisterns were barely recognisable due to diffuse cerebral swelling”. A new NMR test showed: “a slight increase in the extent of the altered signal areas, hyperintense in T2-weighted images, already noted previously: in particular similar alterations close to the left lateral ventricle, less evident in the previous examination. The DWI images show hyperintensity in the above-mentioned areas, as if an acute event was in evolution. A marked increase was noted in the extent and intensity of enhancement of the same areas after administration of gadolinium-DTPA. The picture still appeared to be compatible with the expansion of increased permeability of the hematoencephalic barrier, already noticeable to a minimum extent in the previous examination. The extent of the development is largely gyratory along the convolutions inscribed in the areas of hyperintensity in the T2-dependent images. Other reports were unchanged and the picture was compatible with vascular-based lesions”.

Considering the stability of the patient's general condition, she was transferred to the Medical Pathology Department and kept under close medical control. The haematochemical parameters subsequently became progressively more normal and the vital signs more stable, as did the arterial pressure, stabilizing at an average of about 150/80 mmHg. A final pre-discharge brain NMR showed an almost complete resolution of the previous lesions (Fig. 2).

### Figure 2

Figure 2: Magnetic resonance imaging of the brain with an almost complete resolution of the previous lesions.



On completion of the diagnostic process the patient appeared alert and self-sufficient, except for the presence of a “neglect” syndrome. The arterial pressure was effectively pharmacologically compensated with transdermic Clonidine, Nifedipine and Enalapril <sup>5</sup>.

### DISCUSSION

As said in the introduction, PRES is a complex multifactorial syndrome and can be diagnosed with reversible hyperintensities on T2-weighted cranial MR-images <sup>7-10</sup>. It predominantly affects the posterior circulation territory and the clinical hallmarks are headache, confusion, seizures, cortical visual disturbances or blindness and other neurological signs.

There are three theories for PRES. The earliest theory suggested that overreaction of brain autoregulation results in reversible vasospasm, which in turn results in potentially reversible ischemia to the brain, especially in vascular borderzone territories <sup>2</sup>. The newer theory suggested that autoregulation maintains a constant blood flow to the brain, despite systemic blood pressure alterations, by means of arteriolar constriction and dilatation. So, the constricted arterioles are forced to dilate because of the increased systemic blood pressure, resulting in brain hyperperfusion. This increased perfusion pressure is sufficient to overcome the blood-brain barrier, allowing extravasation of fluid,

macromolecules, and even red blood cells into the brain parenchyma. So, P.R.E.S. represents vasogenic rather than cytotoxic oedema in the majority of cases <sup>8</sup>. The last theory suggests that at intravascular pressures just below those that could rupture the capillary wall, permeability through the endothelium increased markedly, which was most likely due to increased pinocytotic activity through the capillary wall. The active passage of fluid through the capillary wall may act to relieve intravascular pressure, forestalling the development of large haemorrhages <sup>4</sup>. So in this case, P.R.E.S. is not an example of cytotoxic or vasogenic oedema but hydrostatic oedema. However the pathogenesis is attributed to a failure of cerebral autoregulation that is probably facilitated in posterior brain regions due to a sparse sympathetic innervation of the vertebrobasilar vascular system.

The aetiology of P.R.E.S. in this patient remains unclear but it may be related to a pharmacotoxic cause (abuse of drugs) because symptoms including altered mental function, visual loss, stupor and seizures are specific of acute encephalopathy based on treatment with immunosuppressive drugs.

### CONCLUSION

The cause of PRES is certainly multifactorial <sup>3,11</sup>. The syndrome should be promptly recognized, since it is reversible and readily treated by controlling blood pressure and, based on our experience, decreasing the dose of NSAIDs and eliminating the use of drugs, such as those used by our patient. The key to diagnosis is certainly the image, but clinicians must raise suspicion when there is a case with these characteristics <sup>1</sup>.

### References

1. Hagemann G, Ugur T, Witte OW, Fitzek C. Recurrent posterior reversible encephalopathy syndrome (PRES). *J Hum Hypertens*. 2004 Apr;18(4):287-9.
2. Casey SO, Sampaio RC, Michel E, Truwit CL. Posterior reversible encephalopathy syndrome: utility of fluid-attenuated inversion recovery MR imaging in the detection of cortical and subcortical lesions. *AJNR Am J Neuroradiol*. 2000 Aug;21(7):1199-206.
3. Hinchey J, Chaves C, Appignani B, et al. A reversible posterior leukoencephalopathy syndrome. *N Engl J Med*. 1996 Feb 22;334(8):494-500.
4. Schwartz RB. Hyperperfusion encephalopathies: hypertensive encephalopathy and related conditions. *Neurologist*. 2002 Jan;8(1):22-34.
5. Servillo G, Bifulco F, De Robertis E, et al: Posterior reversible encephalopathy syndrome in intensive care medicine. *Intensive Care Med*. 2007 Feb;33(2):230-6. Epub 2006 Nov 21. Review.
6. Fitzgerald-Hines J, King ML. Posterior reversible encephalopathy syndrome: a case study.

7. 2006 Oct;38(5):338-41, 373. Review.
8. Kahana A, Rowley HA, Weinstein JM. Cortical blindness: clinical and radiologic findings in reversible posterior leukoencephalopathy syndrome: case report and review of the literature. *Ophthalmology*. 2005 Feb;112(2):e7-e11. Review.
9. Finocchi V, Bozzao A, Bonamini M, et al Magnetic resonance imaging in Posterior Reversible Encephalopathy Syndrome: report of three cases and review of literature. *Arch Gynecol Obstet*. 2005 Jan;271(1):79-85. Epub 2004 Oct 9. Review.
10. Lamy C, Oppenheim C, Méder JF, Mas JL. Neuroimaging in posterior reversible encephalopathy syndrome. *J Neuroimaging*. 2004 Apr;14(2):89-96. Review.
11. Kinoshita T, Moritani T, Shrier DA, et al. Diffusion-weighted MR imaging of posterior reversible leukoencephalopathy syndrome: a pictorial essay.
12. 2003 Sep-Oct;27(5):307-15. Review.
13. Minagar A, DeToledo JC, Falcone S. Cortical-subcortical lesions in "reversible posterior leukoencephalopathy syndrome". *Encephalopathy or seizures?* *J Neurol*. 2001 Jun;248(6):537-40. Review.
14. Pavlakis SG, Frank Y, Chusid R. Hypertensive encephalopathy, reversible occipitoparietal encephalopathy, or reversible posterior leukoencephalopathy: three names for an old syndrome. *J Child Neurol*. 1999 May;14(5):277-81. Review.

**Author Information**

**G. Merra**

Department of Internal Medicine, Department of Anesthesiology , and Department of Radiology Catholic University of Sacred Heart, Rome, Italy

**A. Dal Lago**

Department of Internal Medicine, Department of Anesthesiology , and Department of Radiology Catholic University of Sacred Heart, Rome, Italy

**L. Natale**

Department of Internal Medicine, Department of Anesthesiology , and Department of Radiology Catholic University of Sacred Heart, Rome, Italy

**E. Gaetani**

Department of Internal Medicine, Department of Anesthesiology , and Department of Radiology Catholic University of Sacred Heart, Rome, Italy

**A. Caricato**

Department of Internal Medicine, Department of Anesthesiology , and Department of Radiology Catholic University of Sacred Heart, Rome, Italy

**A. Cianfoni**

Department of Internal Medicine, Department of Anesthesiology , and Department of Radiology Catholic University of Sacred Heart, Rome, Italy

**P. Pola**

Department of Internal Medicine, Department of Anesthesiology , and Department of Radiology Catholic University of Sacred Heart, Rome, Italy

**G. Gasbarrini**

Department of Internal Medicine, Department of Anesthesiology , and Department of Radiology Catholic University of Sacred Heart, Rome, Italy

**A. Gasbarrini**

Department of Internal Medicine, Department of Anesthesiology , and Department of Radiology Catholic University of Sacred Heart, Rome, Italy

**G. Ghirlanda**

Department of Internal Medicine, Department of Anesthesiology , and Department of Radiology Catholic University of Sacred Heart, Rome, Italy