

Hydatid Disease Of The Bone

S Agarwal, Z Kundu, S Singh, N Soni

Citation

S Agarwal, Z Kundu, S Singh, N Soni. *Hydatid Disease Of The Bone*. The Internet Journal of Spine Surgery. 2008 Volume 5 Number 1.

Abstract

INTRODUCTION: Hydatid disease of the bone is a very rare condition and is almost nonexistent in some parts of the world. The present case was the only case diagnosed at our institute in the past 4 years. **CASE REPORT:** A 60 year old woman presented with complaints of a discharging sinus in the perianal region of 2 weeks duration. There was history of repeated fractures of the left femur which were treated conservatively. On examination foul smelling discharge was present over an ulcerated lesion in the ilio-sacral region which extended upto a boggy, indurated swelling in the perianal region suggestive of an abscess. Deformity was present over left thigh and there was no tenderness. Biopsy from the iliac region revealed evidence of Hydatid cyst. Radiograph and CT of the pelvis and left thigh revealed multiple expansile osteolytic lesions with no evidence of osteosclerosis or calcification. Hematological parameters were normal except for anemia. Hindquarter amputation was performed. Post-operative period was turbulent and the patient died on the fourth post-operative day. **CONCLUSION:** Hydatid disease of the bone is a rare manifestation of Echinococcosis. Its management also differs from most other conditions involving the bone. It is hence important to consider the possibility of Hydatid disease of the bone as a differential diagnosis of luculent lesions of the bone especially in the areas where it is prevalent for proper treatment of the patient.

INTRODUCTION

Hydatid disease (HD) is prevalent and widespread in most sheep-raising countries in Asia, Australia and South America. It is produced by the larval stage of the *Echinococcus* tapeworm. HD can occur almost anywhere in the body and demonstrates a variety of imaging features that vary according to growth stage, associated complications, and affected tissue.¹² Osseous involvement is very rare and occurs in only 0.5 -4% of all the cases of Hydatid diseases.³

CASE REPORT

A 60 year old female presented with complaints of a discharging sinus in the perianal region of 2 weeks duration. Approximately 7 years back there was history of injury to the left lower limb that was treated conservatively. She again sustained injury to the same limb approximately 7 months back which was treated conservatively. On examination the patient was anaemic, while the rest of the vital parameters and hematological parameters were normal. Foul smelling discharge was present over an ulcerated lesion in the sacral region which extended upto a boggy indurated swelling in the perianal region which was suggestive of an abscess. Deformity was present over left thigh and there was no tenderness. Radiographs of the pelvic and left thigh region revealed multiple cystic lesions and deformity of the left

hemipelvis and left thigh. In addition there was comminuted non-healing fracture of the shaft of the left Femur with dislocation of the head of Femur.(Fig 1) No evidence of osteosclerosis was seen. Ultrasound of the abdomen was normal. Thyroid and parathyroid hormone levels were also normal. Ulcerated lesion over the sacral region was debrided and perianal abscess was drained. An open biopsy from the site rendered a diagnosis of Hydatid cyst. After debridement patient went into shock and was revived. Computed Tomogram of the patient was performed extending from the pelvic brim to the region of the upper thigh which revealed multiple intramedullary cystic lesions with destruction of the cortex at multiple places and involvement of adjacent soft tissues. No evidence of osteosclerosis and calcification was noted (Fig 2a & b)

There-after patient was operated upon and hind quarter amputation was performed taking care and avoiding spillage of material from the collection into surrounding tissue. Microscopy of the resected specimen confirmed the diagnosis. (H & E x 100;Fig 3) Post-operative period was turbulent and the patient died on the fourth post-operative day

Figure 1

Figure 1: Radiograph of the Pelvis and both femurs reveals multiple expansile osteolytic lesions involving the left hemipelvis and left femur. No osteosclerosis noted. In addition there was nonunited comminuted fracture of the shaft of left Femur. Dislocation of the left femoral head is also seen.

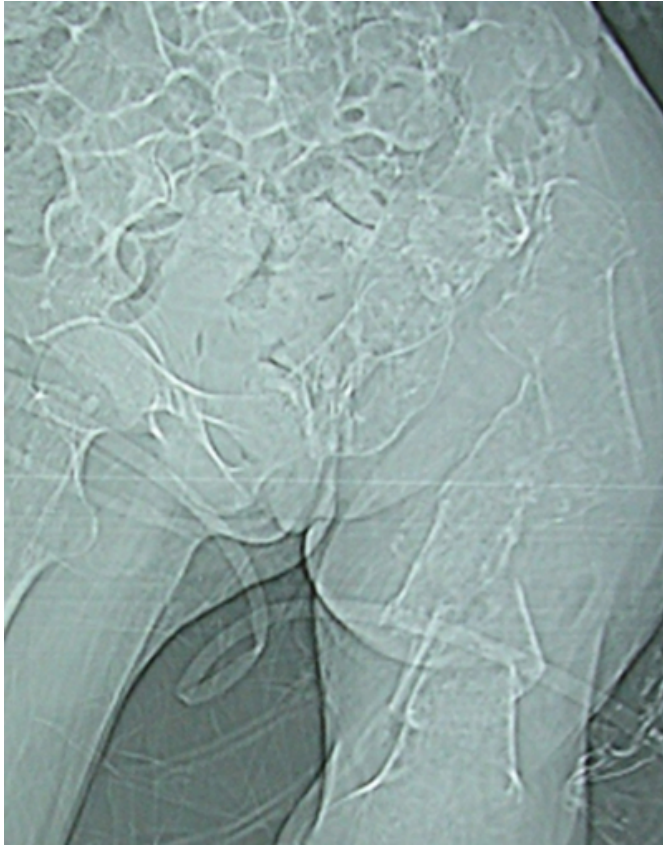

Figure 2

Figure 2a: Axial CT section at the level of acetabular roof confirms the findings of radiograph.

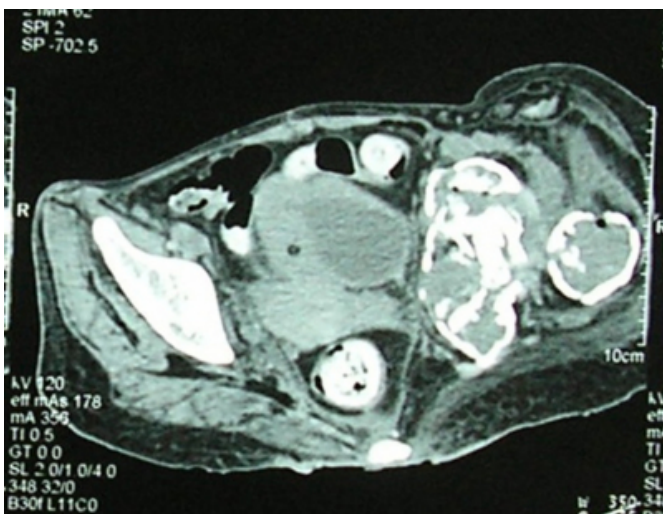


Figure 3

Figure 2b: Sagittal reconstruction of the axial CT images showing the same findings

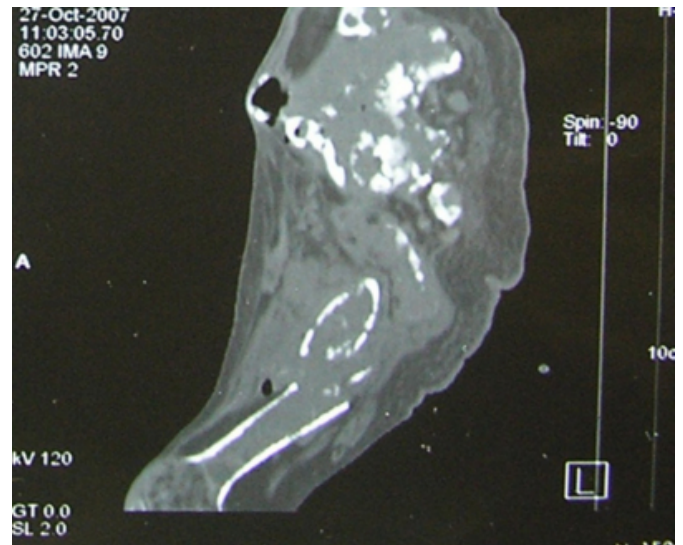
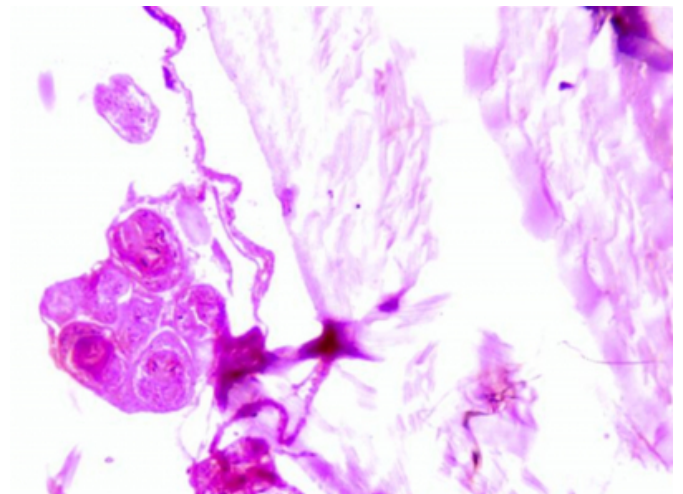


Figure 4

Figure 3: Microscopic section from the perianal region reveals hydatid cyst with the wall composed of ectocyst with germinative layer & blood capsule (H& E,100X)



DISCUSSION

Hydatid disease of the bone is a very rare condition and is almost non-existent in some parts of the world. The present case was the only case diagnosed at our institute in the past 4 years. Sapkas GS et al (1998) ⁴ reported a series of 8 cases which were treated at their institute over a period of 11 years. While Rong SH et al, (1985) reported a series of 20 patients over 23 years. Thomas JD (1884) collected twenty-eight examples, mostly from isolated reports in the literature.⁶ The most detailed account of hydatid disease of bone is that of Ivanissevich (1934) who published a review

of the subject and described forty-seven cases.⁷

In humans, hydatid disease involves the liver in approximately 75% of cases, the lung in 15%, and other anatomic locations in 10%.⁸ The frequency of osseous involvement in hydatid disease is 0.5%–4%.³ It is most commonly seen in the spine and pelvis, followed by the femur, tibia, humerus, skull, and ribs.³⁸

Osseous foci may be manifested as pain and deformity, particularly in 30–60 years old age group. Hydatid disease of bone is rarely seen in childhood.² The hydatid cyst lie dormant in the bone for as long as 40 years and most skeletal hydatid cyst cases have been adults.¹ Skeletal cystic echinococcosis lesion may be single or multiple.⁹ As Hydatid disease of bone remains asymptomatic over a long period, it is usually detected after a pathological fracture or secondary infection or following the onset of compressive myelopathy in cases of vertebral lesions.¹⁰

The initial location of the lesion in long bones is metaphyseal or epiphyseal, later extending to the diaphysis.¹¹¹² In bone involvement, pericyst formation does not occur, thereby allowing aggressive proliferation in an irregular branching fashion along the line of least resistance, especially the bone canals.³⁹ The parasite replaces the osseous tissue between trabeculae due to the slow growth of multiple vesicles. With time, the parasite reaches and destroys the cortex, with subsequent spread of the disease to surrounding tissues.³⁸⁹ Extraosseous cysts may calcify, whereas intraosseous disease rarely demonstrates calcification.⁹ The findings in our case were very similar.

Spinal hydatid disease, the most common form of bone involvement, is usually difficult to distinguish from tuberculous spondylitis or chronic osteomyelitis. Some imaging characteristics have been described as typical of spinal hydatid disease. These include lack of osteoporosis and sclerosis in host bone; absence of damage to the disk spaces and vertebral bodies and spread of the disease via a subperiosteal and subligamentous path³⁹¹³; paraspinal extension; and, particularly, involvement of a contiguous rib.¹³ Although CT allows precise assessment of osseous lesions and clearly depicts hydatid cyst calcification, MR imaging is superior in demonstrating involvement of neural structures.⁹

The most common radiological manifestation of skeletal hydatid disease is a lucent expansile lesion with cortical thinning.² The differential diagnosis of skeletal cystic

echinococcosis includes other infectious lesions, like tuberculosis, fibrous dysplasia, tumors (simple bone cyst, aneurismal bone cyst, plasmocytoma, osteosarcoma, chondrosarcoma, chondromyxoid fibroma, lymphoma, giant cell tumors, brown tumor, metastases, etc.).¹²

Radiologic and serologic findings can generally help establish the diagnosis of HD, but an HC in an unusual location with atypical imaging findings may complicate the differential diagnosis. Accurate diagnosis may be aided in some persons by eosinophilia (25 to 35% of cases) and positive result of complement fixation tests, intradermal injection of hydatid fluid (casoni test), and indirect hemagglutination tests.¹²

The diagnosis is difficult since daughter cysts, calcification, and germinal membrane detachment, typical manifestations of cystic echinococcosis in parenchymal organs, are not usually observed in skeletal hydatid cysts. The definitive diagnosis can usually be made by histopathological examination.¹¹⁴

Surgery is the treatment of choice for hydatid bone lesions. Many authors have advocated wide resection of the involved bone along with surrounding soft tissues as the only definitive treatment of the condition.¹¹ with or without chemotherapy using albendazole or mebendazole. Natrajan et al¹⁵ emphasized on the need for complete surgical extirpation of the cyst.

CONCLUSION

Hydatid disease of the bone is a rare manifestation of Echinococcosis. Its management also differs from most other conditions involving the bone. It is hence important to consider the possibility of Hydatid disease of the bone as a differential diagnosis of lucent lesions of the bone especially in the areas where it is prevalent; so as to render proper treatment to the patient.

CORRESPONDENCE TO

Dr. Shalini Agarwal Wardens Residence Girl's Hostel, Pt. BD Sharma, PGIMS Rohtak, Haryana-124001 (India)
Mobile: 91-9355622099 91-9896840382 Email:
agarwalsdr@gmail.com agar_shalini@yahoo.com

References

1. Merkle E, Schulte M, Vogel T. Musculoskeletal involvement in cystic echinococcosis. Report of eight cases and review of literature. 1997; 168: 1531.
2. Tüzün M, Hekimolu B. Various Location of cystic and alveolar hydatid disease: CT appearances. J comput Assist Tomogr. 2001; 25:81-7.

3. Torricelli P, Martinelli C, Biagini R, Ruggieri P, De Cristofaro R. Radiographic and computed tomographic findings in hydatid disease of bone. *Skeletal Radiol* 1990; 19:435-9.
4. Sapkas SG, Stathakopoulos DP, Bibis GC, Tsarouchas JK. Hydatid disease of bones and joints. *Acta Orthop Scand* 1998;69: 89-94.
5. Rong SH, Nie ZQ. Hydatid disease of bone. *Clin Radiology*. 1985; 36: 301-5
6. Thomas JD. Hydatid disease. Adelaide : E Spiller ; 1884 : 47-9.
7. Ivanissevich O. Hidatidosis osea [in Spanish]. Buenos Aires: Amorrortu ; 1934 : 16-8.
8. King CH. Cestodes (tapeworms) In: Mandell GL, Bennett JE, Dolin R. Principles and practice of infectious diseases. 4th ed. New York, NY: Churchill Livingstone, 1995; 2544-53.
9. Ögüt AG, Kanberoglu K, Altug A, Cokyüksel O. CT and MRI in hydatid disease of cervical vertebrae. *Neuroradiology* 1992; 34:430-432.
10. Morris B, Madiwale C, Gary A, Chavhan G. Case report: Hydatid disease of bone. *Australasian Radiology*. 2002 Dec; 46(4): 431.
11. Zlitni M, Ezzaouia K, Lebib H, Karray M, Kooli M, Mestiri M. Hydatid cyst of the bone: Diagnosis and treatment. *World J Surg* 2001; 25: 75-82.
12. Markakis P, Markaki S, Prevedorou D, Bouropoulou V. Echinococcosis of bone: clinico-laboratory findings and differential diagnostic problems. *Arch Anat Cytol Pathol* 1990; 38: 92-4.
13. Braithwaite PA, Lees RF. Vertebral hydatid disease: radiological assessment. *Radiology* 1981; 140:763-766.
14. Resnick D. Osteomyelitis, septic arthritis and soft tissue infection. IN: Resnick. *Diagnosis of bone and joint disorders: From saunders*, 2002: 2510-2626.
15. Natrajan MV, Kumar AK, Sivaseelam A, Lyakutty P, Raja M, Rajagopal TS. Using a custom mega prosthesis to treat hydatidosis of the bone: a report of 3 cases. *J Orthop Surg* 2002; 10: 203-5.

Author Information

Shalini Agarwal, M.D., DNB

Associate Professor, Department of Radiology, Pt. B.D. Sharma, Post Graduate Institute of Medical Sciences

Zile Singh Kundu, MD, DNB

Associate Professor, Department of Orthopedics, Pt. B.D. Sharma, Post Graduate Institute of Medical Sciences

Sunita Singh, MD

Professor, Department of Pathology, Pt. B.D. Sharma, Post Graduate Institute of Medical Sciences

Neetu Soni, MD

Senior Resident, Department of Radiology, Pt. B.D. Sharma, Post Graduate Institute of Medical Sciences