

Tapia's Syndrome Following Hunting Rifle-Shot

E Dursun, H C?nc?k, E Cek?n, S Dogru, A Gungor, E Poyrazoglu

Citation

E Dursun, H C?nc?k, E Cek?n, S Dogru, A Gungor, E Poyrazoglu. *Tapia's Syndrome Following Hunting Rifle-Shot*. The Internet Journal of Head and Neck Surgery. 2006 Volume 1 Number 1.

Abstract

Tapia's syndrome is rare entity characterized by unilateral paralysis of the tongue and vocal cord which is caused by a lesion of the 10th and 12th cranial nerves. A very limited number of cases have been reported in English literature. In our case, Tapia's syndrome occurred following a hunting rifle shot and was presented in light of the literatures.

INTRODUCTION

Tapia's syndrome or Tapia's vagohypoglossal syndrome is first described by Antonio Garcia Tapia who was an otorhinolaryngologist (1). The syndrome is characterized by unilateral paralysis of the tongue and vocal cord which is caused by a lesion of the 10th and 12th cranial nerves (2).

Most common clinical symptoms are hoarseness, difficulty in tongue movement and dysphagia. The typical presentation is immobility of the vocal cord and tongue deviation to the denervated side on protrusion. Although various causes have been reported to explain Tapia's syndrome, the main causes are parotideal and other tumours or injuries to the upper neck (3).

We report a patient with unilateral paralysis of the tongue and vocal cord occurred following a hunting rifle shot to the lateral neck, that was compatible with those of Tapia syndrome.

CASE REPORT

A 21-year-old male was accidentally injured by himself with hunting rifle-shot and had a lot of lesion over face and neck. In physical examination, the tongue deviation to the left side on protrusion was observed (Fig 1), and direct laryngoscopy showed that left vocal cord was fixed on median position (Fig 2). There was no disturbance of facial movement or of sternocleidomastoid and trapezius muscle and no horner syndrome. No more nerve and body muscles were involved in this condition and also blood screen tests were unremarkable.

Figure 1

Figure 1: The tongue deviation to the denervated side during tongue protrusion and atrophy on the same side.

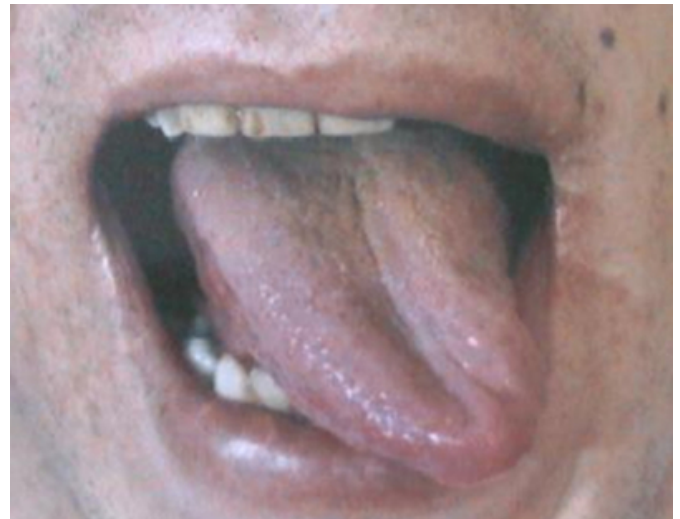
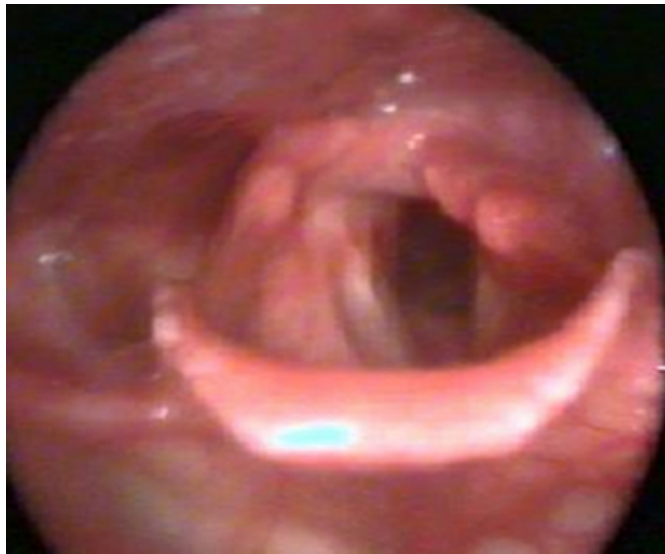
Figure 2

Figure 2: Left vocal cord paralysis



A x-ray scan of the neck revealed a lot of metallic round pellets that spreaded between the left zygomatic arc and the supraclavicular line (Fig 3). A computed tomographic (CT) scan confirmed the presence of multiple round metallic pellets, which was lodged within the posterior neck muscles and lateral portion of the neck (Fig 4). There were no signs of fluid or air accumulation in the neck. The CT scan excluded any damage to the neck structures. No signs of haemorrhage, abscess formation, tumour, ischaemia vascular pathology were observed in all the transverse sections.

Figure 3

Figure 3: Multiple pellets in the neck X-ray films.

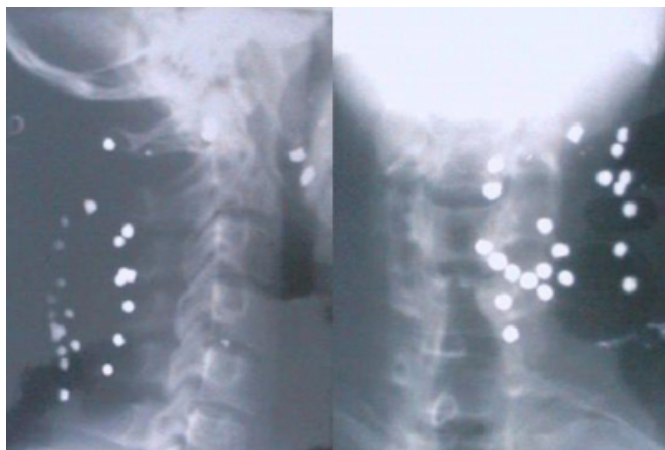
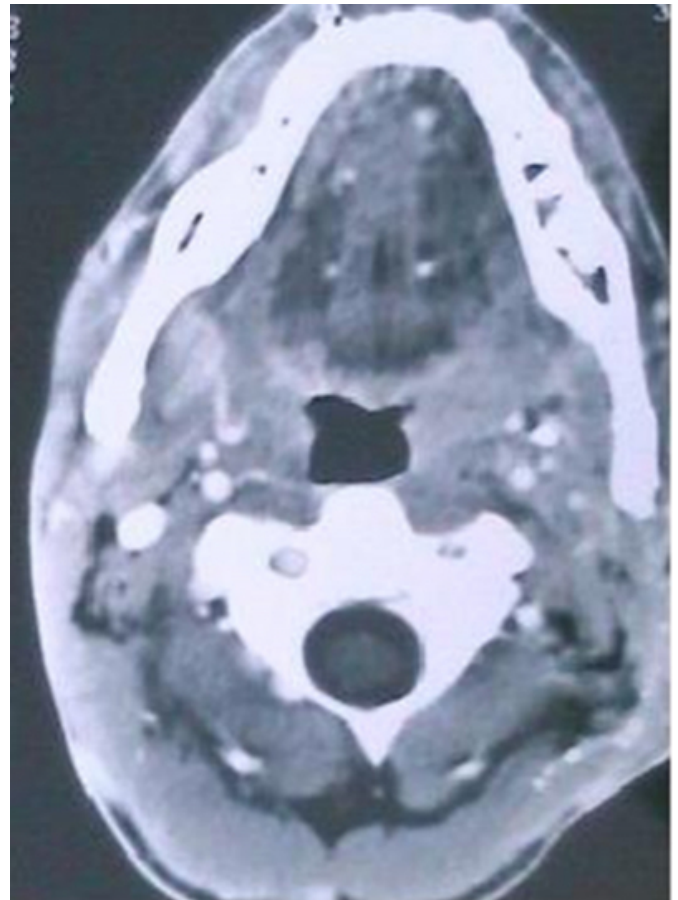


Figure 4

Figure 4: CT scan performed after trauma showing multiple pellets located on left cervical region.



After clinical evaluation it was suggested that cranial nerve palsies caused by hunting rifle-shot injury. We discussed the situation with the patient but the high risk for morbidity, he refused the surgical procedure. Because of the absence of organ damage or lifethreatening structural lesion we agreed with him about invasive surgery in case of iatrogenic injury of the other nerves. He is still under close follow-up for a year.

DISCUSSION

Tapia's syndrome is a combinations of recurrent laryngeal and hypoglossal nerve palsy (2). Our patient had two symptoms following a hunting rifle-shot injury. Due to the association of the 10th and 12th cranial nerves we could consider it within the called as Tapaia`s syndrome.

The vagal nerve leaves the cranium through the jugular foramen and passes through the neck to the thorax. The hypoglossal nerve is medial to 9th, 10th and 11th cranial nerve after left the cranium. The hypoglossal nerve enters the paravertebral spatium and descends to the anterior

triangle of the neck, during which it is close to the surface of the inferior vagal ganglion. Then the hypoglossal nerve crosses vagal nerve in order to continue its route medially and finally reach the tongue (4). This close relationship between vagal and hypoglossal nerve may explain the possible mechanism of the both nerve injury in a patient. The combination injury of hypoglossal and the vagal nerves due to extracranial involvement is a very rare entity. The main causes are tumors or injuries to the upper neck (1) and also various reasons such as congenital (5), idiopathic (6), iatrogenic, endotracheal intubations (4) were reported.

During surgery cranial nerve injuries can be occur following trauma, exaggerated dorsiflexion of the head, pressure or extensive stretching. The lingual, vagal, hypoglossal and abducens are the most commonly injured cranial nerves. In most cases there is a direct trauma to the associated nerve related to the surgery. Carotid endarterectomy, radical neck dissection, thoracotomy are common surgical causes of cranial nerve palsy (7).

Penetrating injuries of the neck are uncommon but potentially life threatening injuries. Midportion of the neck is the most affected location of injury (8). The most commonly injured structures are the trachea, esophagus, and larynx (9). However, in patients presenting with any lesion of the neck along with a history of penetrating injury, cranial nerve damage must first be suspected and ruled out.

Physical examination is a reliable method for detecting significant injuries following penetrating neck trauma. The foreign bodies may consist of metal, plastic, or glass and can be identified on radiographs, CT or MRI scans. In our case multiple pellets seen in the plain x-ray and CT scan. The CT scan may exclude any damages on the structures.

There has been no recommended therapy for these cranial nerve palsies. In some case steroid and vitamin complex administration may be used to shorter the recovery period. The steroid is the commonly used drug to treat nerve palsy

(4). Management of patients who sustained gunshot to the neck remains controversial and surgical interventions for metallic foreign bodies is also challenging situation for surgeon due to the high risk for mortality and morbidity. The removal of foreign bodies in the head and neck area is difficult due to a combination of difficult access and a close anatomical relationship of the foreign body to vital structures(10). We followed our case for a year but the palsy of the nerves was not regressed in spite of conventional medical therapy. In conclusion, this is the first case report describing a Tapia's syndrome following hunting rifle-shot injury.

CORRESPONDENCE TO

Engin DURSUN, MD. GATA Haydarpasa Training Hospital
Department of Otorhinolaryngology 34668 Kadikoy /
ISTANBUL E-mail: drengindursun@yahoo.com GSM : +90
505 217 01 32

References

1. Tapia AG. Un caso de parálisis del lado derecho de la laringe y de ungue, con parálisis del externo-cleido-mastoidea y trapecio del mismo lado. *Siglo Medica* 1905; 52: 211-213.
2. Andrioli G, Rigobello L, Mingrino S, Toso V. Tapia's syndrome caused by a neurofibroma of the hypoglossal and vagus nerves: case report. *J Neurosurg* 1980; 52(5): 730-732.
3. Gelmers HJ. Tapia's syndrome after thoracotomy. *Arch Otolaryngol* 1983;109:622-623.
4. Yavuzer R, Basterzi Y, Özköse Z, Demir HY, Yılmaz M, Ceylan A. Tapia syndrome following septorhinoplasty. *Aesth Plast Surg* 2004; 28: 208-211.
5. Ruhrmann G. Congenital right-sided vagus and hypoglossal nerve paralysis (Tapia syndrome) as the cause of congenital stridor. *Z Kinderheilkd* 1963;88:22-6.
6. Millan Guevara J, Royo Lopez J, Pascual Millan LF, Rivas Rodriguez P, Fumanal Senz L, Castellote Armero A. Idiopathic associated paralysis of the Xth and XIIth cranial nerves. *An Otorrinolaringol Ibero Am* 1993; 20(1): 61-64.
7. Keane JR. Twelfth nerve palsy: Analysis of 100 cases. *Arch neurol* 53:561-566,1996
8. Nason RW, Assuras GN, Gray PR, Lipschitz J, Burns CM. Penetrating neck injuries: analysis of experience from a Canadian trauma centre. *Can J Surg* 2001; 44(2): 122-126.
9. Bumpous JM, Whitt PD, Ganzel TM, McClane SD. Penetrating injuries of the visceral compartment of the neck. *Am J Otolaryngol* 2000;21(3):190-194.
10. Miller RH, Duplechain JK. Penetrating wounds of the neck. *Otolaryngol Clin North Am.* 1991;24(1): 15-29.

Author Information

Engin Dursun, M.D.

Department of Otorhinolaryngology, GATA Haydarpasa Training Hospital

Hakan C?nc?k, M.D.

Department of Otorhinolaryngology, GATA Haydarpasa Training Hospital

Engin Cek?n, M.D.

Department of Otorhinolaryngology, GATA Haydarpasa Training Hospital

Salim Dogru, M.D.

Department of Otorhinolaryngology, GATA Haydarpasa Training Hospital

Atila Gungor, M.D.

Department of Otorhinolaryngology, GATA Haydarpasa Training Hospital

Ethem Poyrazoglu, M.D.

Department of Otorhinolaryngology, GATA Haydarpasa Training Hospital