

The Foreign Body Granuloma Of A Plant Thorn Preoperatively Detected By Ultrasonography

T Chijiwa, H Domoto, N Miyazaki

Citation

T Chijiwa, H Domoto, N Miyazaki. *The Foreign Body Granuloma Of A Plant Thorn Preoperatively Detected By Ultrasonography*. The Internet Journal of Plastic Surgery. 2005 Volume 2 Number 2.

Abstract

We report herein a case of a small foreign body granuloma that was detected preoperatively by ultrasonography in spite of the patient's unawareness of injury by a plant thorn. We propose that high-performance ultrasonography is valuable for routine preoperative examination of soft tissue tumors even if they are tiny in size.

INTRODUCTION

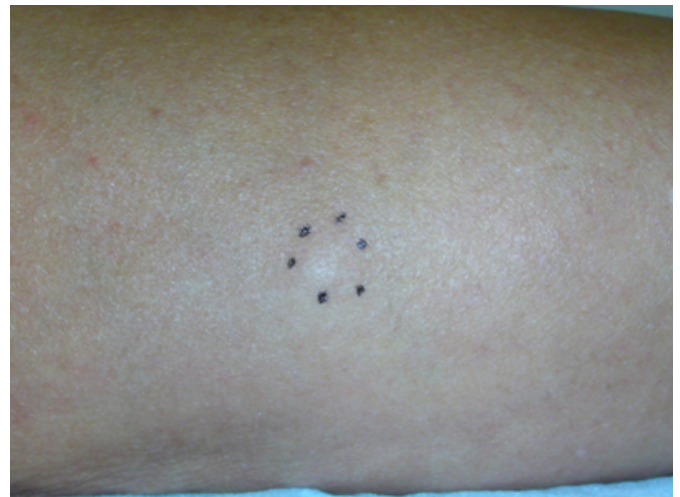In today's medicine the development of the ability of ultrasonography (US) to provide high resolution is occurring in a remarkable manner. The latest facilities are able to detect objects that are under a single millimeter. In the field of plastic and reconstructive surgery, the use of US has become common. We report herein a case of a small foreign body granuloma (FBG) that was detected preoperatively by US. It testifies that the high-performance US could be valuable for preoperative examination of every soft tissue tumor.

CASE REPORT

A 53-year-old man with a subcutaneous tumor of the right forearm was referred to our clinic. This tumor was smooth, elastic hard, and had a round shape of about 8mm in diameter (Fig. 1).

Figure 1

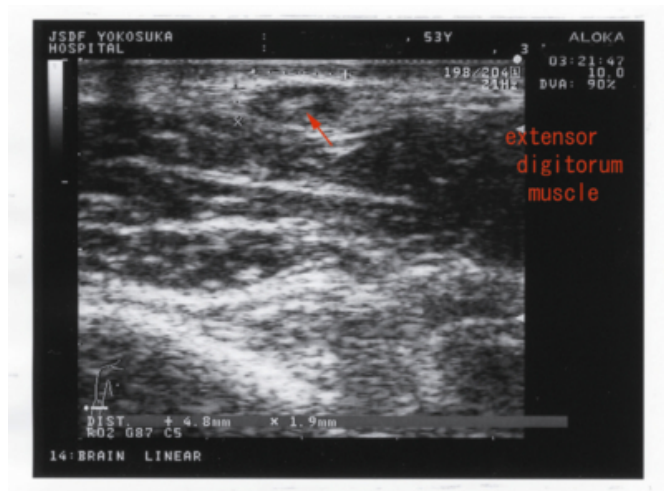Figure 1: There is a small mass on the dorsal side of the right forearm (dotted line). No specific sign of the skin appearance can be indicated.



Its epidermal appearance was not peculiar. It had good mobility and showed no adhesion to his skin. The patient insisted that this tumor had appeared three months earlier but that he had felt no discomfort from it. He denied that there had been any trauma associated with it. We suspected the tumor of being a benign subcutaneous neoplasm like a neurofibroma. The preoperative US (SSD-5500 and UST5545 linear probe, Aloka, Tokyo, Japan) showed a low-echoic mass above the extensor muscle that included a high-echoic spiculate object (Fig. 2).

Figure 2

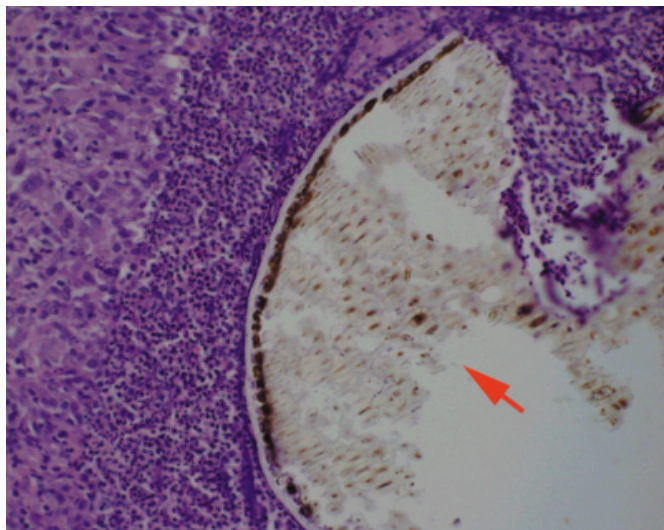
Figure 2: Echogram reveals a spiculate object within the low-echoic lesion above the extensor digitorum muscle (arrow).



The linear shadow that was revealed seemed to be longer and clearer than that of a dermoid cyst, which usually consists of hair and tooth. This tumor was extracted under local anesthesia. Histologically, it consisted of foreign body granulomas with a central abscess where a plant thorn of unknown origin was identified. Special stains did not confirm the presence of any particular organisms (Fig. 3).

Figure 3

Figure 3: Histological features (x200) show the abscess including foreign bodies (arrow) with granulomatous reaction. Foreign bodies are suspected to be a plant thorn because of regular sized cell walls.



Our final diagnosis was the FBG from a plant thorn. We questioned the patient closely as to whether he had been hurt on his arm by a thorny shrub, but he did not remember any such incident.

DISCUSSION

Foreign body injuries (FBI) that sometimes result in granulomatous reactions are extremely common. Suspicion of a FBI is usually easy to make because most patients remember such painful experiences. However, in the case of FBG where there is no basis for such suspicion or a FBI with unusual size or radiolucency, diagnosis may be difficult. US is very useful in detecting the small foreign bodies that support such a diagnosis [1]. In further support of this contention, we note that some papers have reported that FBGs were characteristically disclosed by US [2, 3]. A foreign body that is harder than the softer skin or fat nearby would be well imaged by ultrasonography because echo impedance occurs in proportion to an object's hardness. In our case US disclosed the FBG of a plant thorn preoperatively in spite of both its small size and the patient's unawareness of the cause of his injury. We recommend US strongly for the routine preoperative examination of soft tissue tumors even if they are tiny in size.

References

1. Adams, C. D., Timms, F. J., Hanlon, M.: Phoenix date palm injuries; a review of injuries from the Phoenix date palm treated at the Starship Children's Hospital. *Aust N Z J Surg* 70: 355-7, 2000. PMID: 10830599
2. Fujita, K., Ichikawa, T.: Encapsulated paravesical foreign body. *J Urol* 143: 1004-5, 1990. PMID: 2184250
3. Herzog, P.: Silicone granulomas; detection by ultrasonography. *Plast Reconstr Surg* 84: 856-7, 1989. PMID: 2682704

Author Information

Tsuyoshi Chijiwa, M.D.

Division of Dermatology and Plastic Surgery, Japan Self Defense Force Yokosuka Hospital

Hideharu Domoto, M.D., Ph.D.

Division of Laboratory Medicine, Japan Self Defense Force Yokosuka Hospital

Noriyuki Miyazaki, M.D.

Division of Dermatology and Plastic Surgery, Japan Self Defense Force Yokosuka Hospital