

Inguinal Abscess, A Rare Complication Of Amyand's Hernia. Case Report And Literature Review.

A Mohamed, Y Al Suhaibani, F Emran, M Abukhater

Citation

A Mohamed, Y Al Suhaibani, F Emran, M Abukhater. *Inguinal Abscess, A Rare Complication Of Amyand's Hernia. Case Report And Literature Review..* The Internet Journal of Surgery. 2009 Volume 24 Number 1.

Abstract

INTRODUCTION

The presence of the appendix within an inguinal hernia sac was first described by Claudius Amyand in 1736 and named after him as Amyand's hernia. The presence of the appendix in the hernial sac is found in less than 1% of inguinal hernias. Acute appendicitis, perforated appendix and periappendicular abscess formation within an inguinal hernia sac occur much less frequently and present extremely rare clinical entities. We report a case of appendicular abscess complicating an Amyand's hernia in a 20 weeks pregnant lady who presented with tender inguinal swelling found to be an appendicular abscess complicating an Amyand's hernia. We also review the literature for this rare complication of this rare type of hernia.

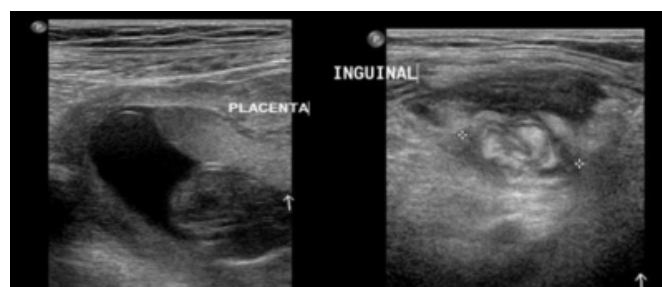CASE PRESENTATION

A 32-year-old 20 weeks pregnant lady was presented to the emergency department at KFMC Riyadh with a right inguinal swelling of 7 days duration. She recalled that the swelling appeared suddenly after coughing, increased gradually in size, and never reduced or disappeared. The swelling became painful and extremely tender to touch two days prior to her presentation. She had on-and-off fever for two days but she did not have abdominal pain vomiting or constipation. On examination, she was febrile with a temperature of 38.8° C. The abdomen was lax, not tender and bowel sounds were normal. The uterus fundus was at the level of the umbilicus. Examination of the inguinal region revealed a lump of about 5x7 cm immediately above the mid inguinal point extending from the level of the deep inguinal ring downwards and forward towards the pubic tubercle. It was tender, non reducible and not fluctuant with negative cough impulse. There were no signs of inflammation of the skin and subcutaneous tissue overlying the lump. Blood investigations including full blood count, liver function test,

coagulation screen and urea and electrolytes were normal apart from leucocytosis of 12.8×10^3 . The abdominal ultrasound showed a gravid uterus with viable fetus and a phlegmon at the right inguinal region (figure 1).

Figure 1

Figure 1: Abdominal ultrasound showing the gravid uterus and a phlegmon at the right inguinal region.



To avoid radiation hazards to the fetus we proceeded with MRI rather than CT scan. The MRI showed a lobulated mass in the right inguinal area measuring 6 x 7 x 5cm in craniocaudal, transverse and anteroposterior diameter, respectively. The appendix was distended measuring 8mm in maximum diameter and was partially lying within the mass. The mass was protruding through the right inguinal canal anterior to the femoral sheath without invasion of the adjacent vessels. There was high signal intensity in T2-weighted images of the adjacent right rectus and iliopsoas muscles which was likely due to reactive inflammation. Reactive lymphadenopathy was seen in the right iliac lymph group. The uterus showed a single fetus with normal location of the placenta. The MRI findings were suggestive of acute appendicitis with abscess formation (figure 2 and 3).

Figure 2

Figure 2: MRI showing the pregnant uterus with enhanced caecal pole together with the inflamed appendix and complex collection around the appendix extending to the pelvis anterior to the psoas muscle

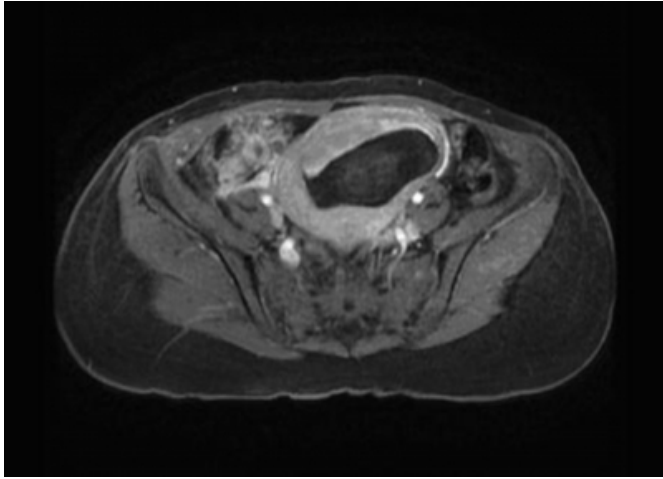
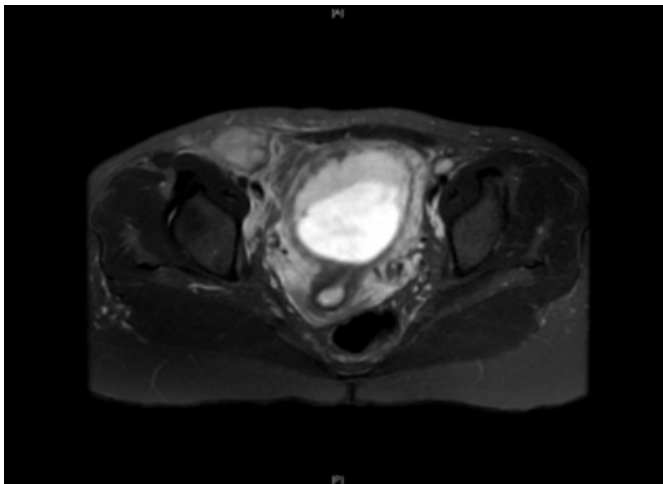


Figure 3

Figure 3: T2-weighted MRI showing multiloculated fluid collection anterior and lateral to the common femoral vessels in the inguinal region.



The patient was taken to theatre and the inguinal region was explored under general anaesthetics by a transverse incision centered over the swelling immediately above the mid inguinal point. The subcutaneous and myofascial tissues were grossly oedematous and as soon as the external oblique aponeurosis was opened, greenish pus started to pour out. A swab was taken for culture and sensitivity and the pus was sucked out leaving an abscess cavity of about 5 x 7cm extending from the internal ring anteriomedially to the pubic tubercle. The cavity was bounded anteriorly by the external oblique muscle and posteriorly by the fascia transversalis. In addition to debris and necrotic tissue found within the

abscess cavity, the appendix was identified with the tip lying medial to the pubic tubercle (figures 4 and 5). The appendix was dissected, traced upwards towards the internal ring, found to be ending at the caecum which was lying at the level of the internal ring, and was inflamed and friable. The appendix was ligated at the base and removed. The abscess cavity was washed out with warm normal saline and a corrugated drain was placed within the cavity and brought out through a different stab wound together with closing of the wound in layers. The histopathology of the appendix confirmed the diagnosis of acute suppurative appendicitis.

Figure 4

Figure 4: showing a tubular structure within the abscess cavity.

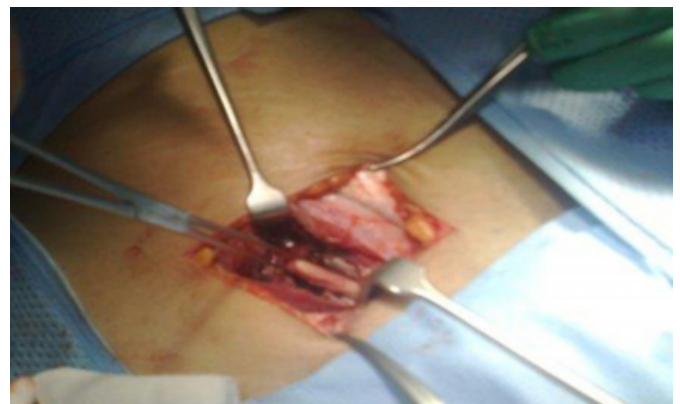
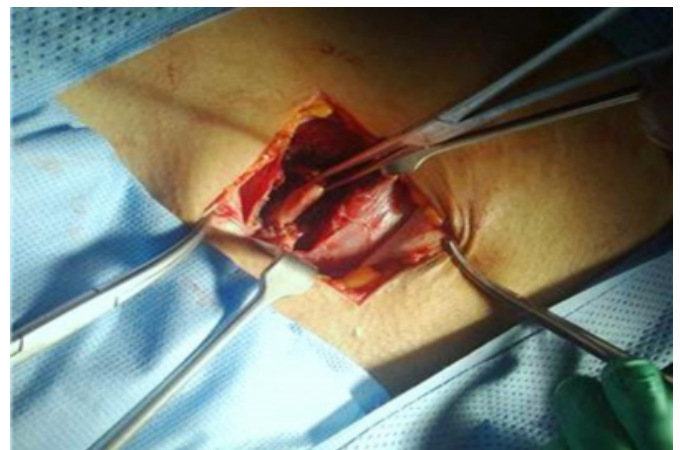

Figure 5

Figure 5: showing the appendix with the tip at the level of the external ring and the base at the level of the internal ring.



The patient had an uneventful post-operative recovery and she was discharged home on the 7th post operative day. She was seen in the outpatient clinic after a month, the wound was healing well without fistula formation.

DISCUSSION

Inguinal hernia is a common surgical problem. Inguinal hernia sacs may contain a usual structure as small bowel (Enterocoele) or omentum (Omentocoele). Unusual contents may be encountered within the hernia sac such as the bladder (1), a Meckel's diverticulum (Littre's hernia), or a portion of the circumference of the intestine (Richter's hernia). The presence of the appendix within inguinal hernia sac is termed Amyand's hernia (2-4) and was first described by Claudius Amyand in 1736. It is worth mentioning that Amyand was the first surgeon to perform appendectomy by removing a perforated appendix from an inguinal hernia sac in an 11-year-old boy in 1735. Interestingly, the first appendectomy ever to be performed in the USA, more than a century later, was also a case of Amyand's hernia in which an abscess with gangrenous appendicitis was found inside the hernial sac (5).

Although the finding of an appendix within an inguinal hernia is more common than that of a Meckel's diverticulum (Littre's hernia), it is surprising that Claudius Amyand, who was the first to describe it, has not enjoyed the same fate of eponymous immortality as Littre (2). Until the 1990s, the eponym Amyand's hernia was not popularly used and the great surgeon was not given due credit. It is only thanks to meticulous research by Deaver, that Amyand's important contribution to surgery got known to all (2,6) and to Hutchinson who presented a detailed description of the historical background and the management of Amyand's hernia in 1993 (2).

The presence of the appendix in the hernial sac is found in less than 1% of inguinal hernias (7-11) and an inflamed appendix is found in the inguinal hernia in only 0.13% of cases (12). Males are more commonly affected than females.

Most of the cases occur on the right side because of the normal anatomical position of the appendix, in addition to the fact that right-sided inguinal hernia is more common. Left-sided Amyand's hernia can be associated with situs inversus, intestinal malrotation or mobile caecum (13). An extensive literature search revealed three reported cases of left-sided Amyand's hernia (7).

Presence of pus at the inguinal region can result from a wide variety of pathological processes and diseases including suppuration of inguinal lymph nodes, abscess of the psoas muscle (14) and appendicular abscesses (15). Intra-abdominal abscesses also result in inguinal canal abscesses that can mimic strangulated hernia. Greenberg et al. reported

a case of a diverticular abscess presenting as a left inguinal hernia (16). Similarly, Andrabi et al. presented an unusual case of diverticulitis with perforation and a resulting abscess presenting as a strangulated inguinal hernia. The abscess formation was not due to strangulation of the contents of the hernia but rather due to pus tracking into the hernia sac from the peritoneal cavity around the round ligament of the uterus (17).

The pathophysiology of Amyand's hernia is unknown. The relationship between incarceration and inflammation of appendix is not yet clarified. It is difficult to determine whether a primary visceral inflammation, which could be referred to as appendicitis, is the pathological mechanism, or if the primary event is strangulation of the herniated appendix, leading subsequently to ischemic necrosis and secondary inflammation (18).

Abu-Dalu and Urca (10,19) suggest that when the appendix enters the sac it becomes more vulnerable to trauma and is ultimately retained there by adhesions. Successive trauma, contraction of abdominal muscles, and other sudden increases in intraabdominal pressure may cause ischemia and compression of the appendix resulting in further inflammation, bacterial overgrowth, and acute appendicitis.

Amyand's hernia can be a challenge for the surgeon (20). Pre-operative diagnosis of hernial appendicitis is very difficult, exceptional and requires awareness of the disease process by the clinician in combination with the physical findings of a tender hernia without radiological or clinical evidence of obstruction. Even with this clinical finding, the condition can be easily confused with strangulated omentocoele. Weber was the first surgeon reported to make the correct diagnosis of an Amyand's hernia preoperatively (21). In his review of sixty cases of acute appendicitis in Amyand's hernia from 1959 to 1999, a correct diagnosis was reached preoperatively only in one case.

The difficulty in diagnosis results from the fact that the medical history and physical examination usually point to incarcerated hernia with localized peritonitis (22). It seems that typical symptoms are similar to those of acute appendicitis, with initial epigastric pain that becomes later located to the right lower quadrant or the hernia sac. Several authors suggest that the pain of strangulated appendicitis tends to be episodic and crampy instead of the constant dull ache usually seen in strangulated bowel (10). Some authors suggest that the presence of pain and peritoneal irritation signs near an incarcerated hernia may provide a hint on the

presence of appendicitis inside the hernia sac (23,24,10). In most revised works, fever and leukocytosis are inconsistent (24,25).

Diagnosis of Amyand's hernia is usually made intraoperatively (20). Ultrasound often demonstrates a potentially inflammatory mass within the hernial sac. Due to the physical condition of the patient, the diagnosis of a strangulated hernia is often made (4).

CT is a very powerful technique to establish early diagnosis, which is very important considering the high risk of perforation. Diagnosis is made by demonstration of an inguinal herniation containing a blind-ending tubular structure with thickened walls, in connection to the caecum.

Preoperative computed tomography (CT) examinations revealed the previously unsuspected diagnosis of Amyand's hernia in some reports (4). However, CT is not routinely used in such clinical situations. Bruno et al. diagnosed Amyand's hernia preoperatively in a 59-year-old man by inguinal sonography, subsequently confirmed by CT (26). In our case, although the diagnosis was suspected preoperatively clinically and ultrasonically, we preferred to confirm the finding with an MRI rather than a CT scan to avoid radiation hazards to the fetus. MRI is reported to be most useful investigation allowing better visualization of the appendix and demonstrates its relationship with surrounding structures. It aids in making the right diagnosis pre-operatively (27).

The preferred repair for Amyand's hernia is determined by the inflammatory state of the appendix (28). Uncomplicated Amyand's hernia is usually treated with appendectomy (through the same wound) with simple repair of the posterior inguinal wall. Mesh should not be used in presence of gross contamination because the prosthetic material can increase the inflammatory response and result in wound infection and a possible appendiceal stump fistula (7). Laparoscopic reduction of Amyand's hernia has also been described (29,4). In presence of suppuration and abscess formation the recommended treatment is drainage of the abscess with appendectomy and interval hernia repair (30).

Complications of Amyand's hernia is closely linked to peritoneal spread of the septic process and may be life-threatening, with an incidence of mortality varying between 14 and 30% (31,32). Mortality risk is most likely associated with perforated appendix, with or without periappendicular abscess formation, or even peritonitis.

SUMMARY

The presence of the appendix within an inguinal hernia sac is termed Amyand's hernia. It was first described by Amyand in 1735. Amyand's hernia is rare, found in less than 1% of inguinal hernias. Appendicular abscesses complicating inguinal hernias are even rarer. Pre-operative diagnosis is difficult as the presenting symptoms and signs favor diagnosis of strangulated hernia. The increased use of CT scan and MRI in investigation of acute inguinoscrotal conditions resulted in an increased number of cases diagnosed pre-operatively. In presence of gross contamination or abscess formation, the recommended surgical treatment is drainage of the abscess followed by interval hernia repair.

References

1. Oruc MT, Akbulut Z, Ozozan O, Coskun F: Urological findings in inguinal hernias: a case report and review of the literature. *Hernia*; 2004; 8(1): 76-79.
2. Hutchinson R: Amyand's hernia. *Journal of the Royal Society of Medicine*; 1993; 86: 104-105.
3. Nigri G, Costa G, Valabrega S, Aurello P, D'Angelo F, Bellagamba R, Lauro A, Ramacciato G: [A rare presentation of Amyand's hernia. Case report and review of the literature]. *Minerva Chir*; 2008 Apr; 63(2): 169-74.
4. Luchs JS, Halpern D, Katz DS: Amyand's hernia: prospective CT diagnosis. *J Comput Assist Tomogr*; 2000; 24: 884-886.
5. Creese PG: The first appendectomy. *Surg Gynecol Obstet*; 1953; 97: 643-652.
6. Deaver JB: *Appendicitis*. Philadelphia: P Blakiston's Son & Co., 1905.
7. Carey LC: Acute appendicitis occurring in hernias: a report of 10 cases. *Surgery*; 1967; 61: 236-238.
8. D'Alia C, Lo Schiavo MG, Tonante A, Taranto F, Gagliano E, Bonanno L et al.: Amyand's hernia: case report and review of the literature. *Hernia* 2003; 7: 89-91.
9. Franko J, Raftopoulos I, Sulkowski R: A rare variation of Amyand's hernia. *Am J Gastroenterol*; 2002; 97: 2684-2685.
10. Logan MT, Nottingham JM: Amyand's hernia: A case report of an incarcerated and perforated appendix within an inguinal hernia and review of the literature. *Am Surg*; 2001; 67: 628-629.
11. Lyass S, Kim A, Bauer J: Perforated appendicitis within an inguinal hernia: case report and review of the literature. *Am J Gastroenterol*; 1997; 92: 700-702.
12. House MG, Goldin SB, Chen H: Perforated Amyand's hernia. *South Med J*; 2001; 94: 496-498.
13. Gupta S, Sharma R, Kaushik R: Left-sided Amyand's hernia. *Singapore Med J*; 2005; 46: 424-5.
14. Sherman HF: The inguinal hernia: not always straightforward, not always a hernia. *J Emerg Med*; 1989; 7(1): 21-4.
15. Deodhar SD, Muzumdar JD: Appendicular abscess presenting as strangulated inguinal hernia. *Indian J Med Sci*; 1974; 28(2): 80-1.
16. Greenberg J, Arnell TD: Diverticular abscess presenting as an incarcerated inguinal hernia. *Am Surg*; 2005; 71(3): 208-9.
17. Andrabi SI, Pitale A, El-Hakeem AA: Diverticular abscess presenting as a strangulated inguinal hernia: case report and review of the literature. *Ulster Med J*; 2007;

76(2): 107-8.

18. Weir CD, Doan SJ, Lughlin V, Diamond T: Strangulation of the appendix in a femoral hernia sac. *Ulster Med J*; 1994; 63: 114-115.

19. Abu-Dalu J, Urca I: Incarcerated inguinal hernia with a perforated appendix and periappendicular abscess. *Dis Colon Rectum*; 1972; 15: 464-5.

20. Milanchi S, Allins AD: Amyand's hernia: history, imaging, and management. *Hernia*; 2008; 12(3): 321-2.

21. Weber RV, Hunt ZC, Kral JG: Amyand's hernia: Etiologic and therapeutic implications of two complications. *Surg Rounds*; 1999; 22: 552-556.

22. Apostolidis S, Papadopoulos V, Michalopoulos A, et al.: Amyand's hernia: a case report and review of literature. *The Internet Journal of Surgery*; 2005; 6 (1).

23. Priego P, Lobo E, Moreno I, Sánchez-Picot S, Gil Olarte MA, Alonso N, Fresneda V: Acute appendicitis in an incarcerated crural hernia: analysis of our experience. *Rev Esp Enferm Dig*; 2005; 97(10): 707-15.

24. El Mansari O, Sakit F, Janati MI. Appendicite aiguë sur hernie crurale. *Press Med*; 2002; 31: 1129-30.

25. Torres Hernández D, Roselló Fina JR, del Campo Abad R, Canals Rabasa PP, Enríquez Weinmann ES. Hernia de Amyand: presentación de un caso y revisión de la literatura.

Arch Cir Gen Dig 2003; 22 Sep. Available at: www.cirugest.com.

26. Coulier B, Pacary J, Broze B: Sonographic diagnosis of appendicitis within a right inguinal hernia (Amyand's hernia). *J Clin Ultrasound*; 2006; 34: 454-457.

27. Fukukura Y, Chang SD: Acute appendicitis within a femoral hernia, multidetector CT findings. *Abdominal Imaging*; 2005; 30: 620-622.

28. Sharma H, Gupta A, Shekhawat NS, Memon B, Memon MA: Amyand's hernia: a report of 18 consecutive patients over a 15-year period. *Hernia*; 11(1): 31-35

29. Vermillion JM, Abernathy SW, Snyder SK: Laparoscopic reduction of Amyand's hernia. *Hernia*; 1999; 3: 159-160.

30. Meinke AK. Review article: appendicitis in groin hernias. *J Gastrointest Surg*; 2007; 11(10): 1368-72.

31. Ottaviani M, Maglio MN, Papa F, Zitarelli V, Alario G, Di Marzo A: Acute gangrenous appendicitis in incarcerated inguinal hernia. a case report. *Minerva Chir*; 1997; 52: 831-833.

32. Davies MG, O'Byrne P, Stephens RB: Perforated appendicitis presenting as an irreducible inguinal hernia. *Br J Clin Pract*; 1990; 44: 494-495.

Author Information

Abbas AR Mohamed, MBBS, FRCSI, FICS

Consultant General and Laparoscopic Surgeon, Department of Surgical Specialties, King Fahad Medical City

Youssuf Abdullah Al Suhaibani, MBBS

Consultant Colorectal Surgeon, Department of Surgical Specialties, King Fahad Medical City

Fawaz Emran, MBBS

Assistant Consultant General Surgery, Department of Surgical Specialties, King Fahad Medical City

Muhammad Abukhater, MBBS, FRCSI

Assistant Consultant General Surgery, Department of Surgical Specialties, King Fahad Medical City