

# Preputial dartos reinforced Snodgrass tubularized incised plate urethroplasties in distal hypospadias

R Singh, S Dalal, N Pavithran

## Citation

R Singh, S Dalal, N Pavithran. *Preputial dartos reinforced Snodgrass tubularized incised plate urethroplasties in distal hypospadias*. The Internet Journal of Plastic Surgery. 2008 Volume 5 Number 2.

## Abstract

**Purpose:** The present study was carried out to evaluate the role of preputial dartos soft tissue reinforcement interposition flaps in prevention of persistent urethro-cutaneous fistulas (UCFs) in distal Snodgrass tubularised incised plate urethroplasties (STIPUs). **Materials and Methods:** During 2005 – 2007, 20 distal hypospadiacs (coronal n= 12, sub coronal n= 8) aged 12-20 years were subjected to STIPUs. After de-epithelialization of both sides of redundant dorsal preputial hoods, the resultant preputial dartos soft tissue flaps were ventralized (similar to Byars, n= 8; Nesbit, n= 8; and, double - breasting, n=4) to be interposed between the underlying neo – urethral tubes and the overlying skin covers. **Results :** All the three modifications of preputial dartos STRIFs functioned highly effectively and only two cases developed micro UCFs both of which healed spontaneously. **Conclusion :** Prepuclal dartos reinforced flaps are ideal for distal hypospadiacs. Micro UCFs developing after routine use of STRIFs, tend to heal spontaneously.

## INTRODUCTION

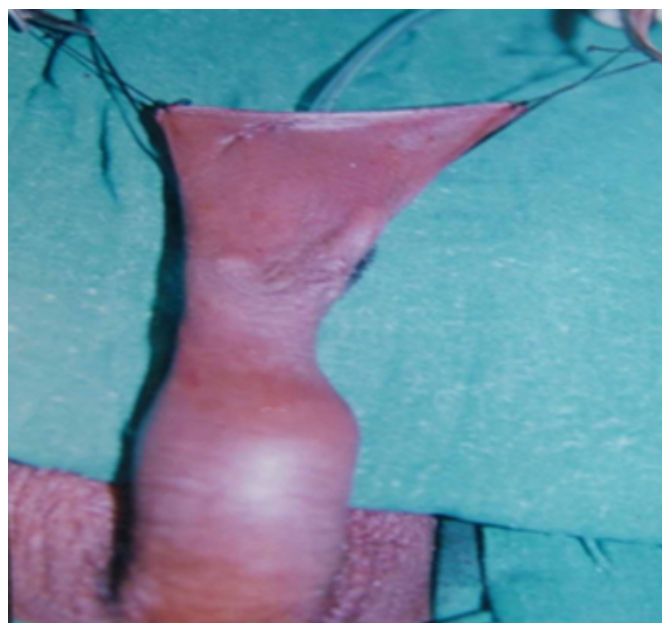
Urethro-cutaneous fistulas (UCFs) formation is the commonest complication of hypospadiac urethroplasties. Different soft tissue reinforcement interposition flaps (STRIFs) have been used to provide mechanical and biological support to neo-urethral tubes against fistulizations.<sup>1,2,3,4</sup>

## PATIENTS AND TECHNIQUE

During 2005-2007, 20 distal hypospadiacs (coronal n=12, sub coronal n=8) aged 15-20 years, were subjected to Snodgrass tubularized incised plate urethroplasties (STIPUs) and their repairs were reinforced using preputial dartos soft tissue reinforcement interposition flaps (STRIFs). The distal hypospadiacs were assessed for the presence of redundant dorsal preputial hood and the availability of enough mobile penile shaft skin to enable tension free circum - coronal closure after degloving of the penile shaft. The redundant preputial hood (Fig. 1) was de-epithelialized on both sides (inner skin and outer skin) up to the level of coronal sulcus to harvest preputial dartos soft tissue flap (Fig. 2).


## Figure 1

Figure 1: Redundant dorsal preputial hood.



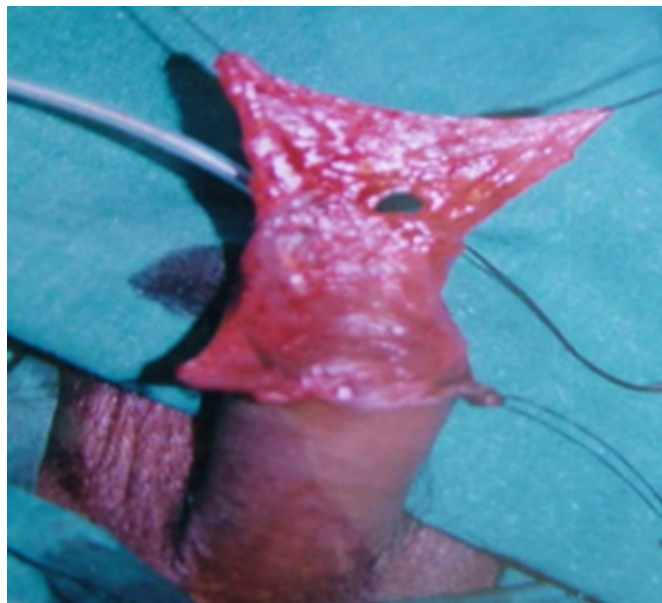
**Figure 2**

Figure 2: De-epithelialization of the preputial hood to harvest preputial dartos STRIF.



**Figure 3**

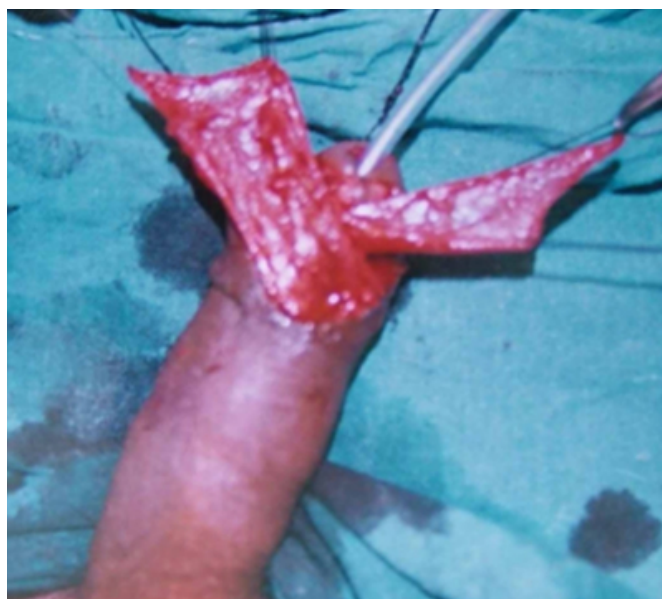Figure 3: STRIF button holed.



In eight hypospadias, this preputial dartos soft tissue flap was divided vertically in two equal halves and both flaps were ventralized and sutured with 5-0 vicryl in Byars fashion to provide reinforcement to the neo-urethral tubes. In other eight hypospadias, this flap was vertically button holed (Fig. 3) to deliver the glans and then ventralized and sutured in Nesbit fashion to have wide spread reinforcement of the neo-urethras. In rest four, the flaps were double-breasted (Fig. 4) like D Smith. The excess and bulky preputial dartos soft tissue flaps were trimmed as per the requirements and tension free adjustment. The degloved penile shaft skin was advanced and sutured in a circum-coronal fashion to give a circumcised look (Fig.5).

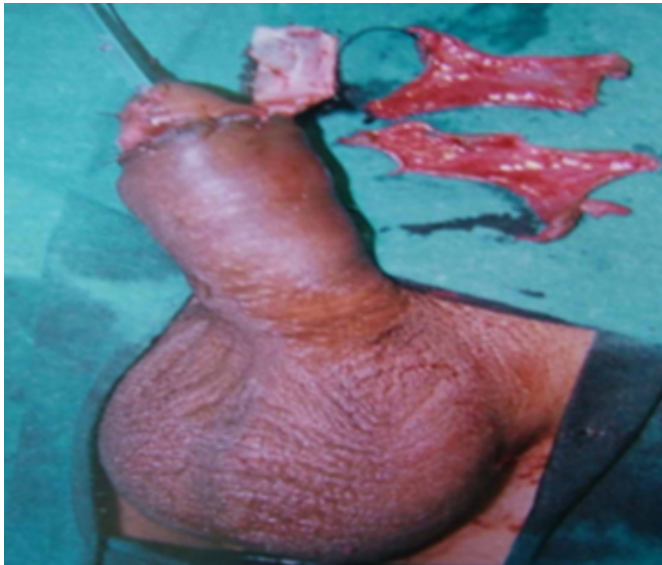**Figure 4**

Figure 4: STRIF divided vertically in two equal halves (flap a and flap b), ventralized and double breasted to reinforce neo-urethra.



**Figure 5**

Figure 5: Circum-coronal closure to give a circumcised look without torsion. De-epithelialized inner and outer skins displayed.



**RESULTS**

Completion of process of both sided de-epithelialization of redundant dorsal preputial hood to harvest preputial dartos soft tissue flap and its interposition between neo-urethral tube and the covering skin required careful dissection and little bit of patience. Byars, Nesbit and double - breasted type of STRIFs provided additional continuous aprons of highly vascular soft tissues for mechanical and biological strengthening of the neo-urethral tubes against persistent fistulizations. Two patients had formation of micro UCFs and both healed spontaneously at six weeks of follow-up. None had developed penile torsion, meatal stenosis, dumbel deformity, dog ears or visible scarring. Circumcised look following circum-coronal closure was aesthetically acceptable.

**DISCUSSION**

Urethro-cutaneous fistulas (UCFs) formation is the most common complication of hypospadiac urethroplasties. Fistula formation depends on a fine balance between (i) healthy versus ischaemic neo-urethral tube, (ii) thick and vascular versus thin and attenuated STRIF, (iii) uniform, patent and adequate neo-urethra versus its irregularity, stenosis or stricture, (iv) long and oblique versus short and superimposed fistulous tract, (v) experienced versus infrequently operating surgeon, (vi) with or without proper pre, per and postoperative precautions, and (vii) many other unknown unidentifiable factors. Different soft tissue reinforcement interposition flaps (STRIFs) have been

described in the literature to provide biological and mechanical support to neo-urethral tubes against fistulizations.<sup>1,2,3</sup> These reinforcement flaps, irrespective of the tissues (preputial skin, penile skin, buck's fascia, scrotum and testes) used for their harvesting, their location (local or distant) and their pattern of vascularity (random or axial), have been collectively named by the authors as STRIFs.<sup>4</sup>

Distal pediatric hypospadiacs with well developed dorsal preputial hoods are ideal cases for reconstruction of functional prepuce. The preputial hoods in these reported adult hypospadiacs were insufficient to enable preputial reconstructions, therefore their preputial hoods were thought to be utilized for harvesting of the STRIFs. The Byars, Nesbit and double - breasting type of STRIFs were equally effective against neo-urethral fistulizations.<sup>5,6,7</sup> Without being reinforced by STRIFs, hypospadiac urethroplasties invariably result in persistent fistulizations requiring subsequent surgical closures. Because of multifactorial etiology of UCFs, they remained the most common complication of hypospadiac urethroplasties despite the use of STRIFs but the STRIFs definitely prevent formation of multiple and macro UCFs, as were seen in the past. Two patients developed UCFs in the present series, which healed spontaneously as they were micro sized and their fistulous tracts were long, oblique, eccentrically placed and without any suture line superimposition, all these had been possible due to the multi-factorial mechanisms of action of the used STRIFs.<sup>4</sup>

**CONCLUSION**

Preputial dartos soft tissue flap like other STRIFs prevent macro UCFs formation. Micro UCFs, developing after routine use of these flaps tend to heal spontaneously.

**CORRESPONDENCE TO**

Dr. Satish Dalal 9J/54, Medical Campus, PGIMS, Rohtak-124001 (Haryana) INDIA Tel. No. +91-1262-213459, Mobile : 09315326802 E-mail : drsatishdalal@rediffmail.com

**References**

1. Smith D. A de-epithelialised overlap flap technique in the repair of hypospadias. *Br J Plast Surg* 1973; 26: 106-14.
2. Snow BW. Use of tunica vaginalis to prevent fistulas in hypospadias surgery. *J Urol* 1986; 136: 861-63.
3. Singh RB, Pavithran NM. Tunica vaginalis interposition flap in the closure of massive disruption of the neo-urethral tube (macrourethrocuteaneous fistulae). *Pediatr Surg Int* 2004; 20:464-66.
4. Singh RB, Dalal S, Pavithran NM, Sharma BD. Soft tissue reinforcement interposition flaps in hypospadias repair.

Indian J Plast Surg 2007; 40 (2): 170-77.

5. Snodgrass W. Tubularized, incised plate urethroplasty for distal hypospadias. J Urol 1994; 151: 464-65.

6. Byars LT. A technique for consistently satisfactory repair of hypospadias. Surg Gynecol Obstet 1995; 100 : 184-90.

7. Nesbit RM. Plastic procedure for correction of hypospadias. J Urol 1941; 45: 699-702.

**Author Information**

**R.B. Singh, M.S., M.Ch.**

Professor, Department of Burns & Plastic Surgery and Special Clinic Hypospadias & VVFs, Pt.B.D.Sharma Postgraduate Institute of Medical Sciences (P.G.I.M.S.)

**S. Dalal, M.S.**

Associate Professor, Department of General Surgery, Pt.B.D.Sharma Postgraduate Institute of Medical Sciences (P.G.I.M.S.)

**N.M. Pavithran, M.S.**

Senior Resident, Department of Burns & Plastic Surgery and Special Clinic Hypospadias & VVFs, Pt.B.D.Sharma Postgraduate Institute of Medical Sciences (P.G.I.M.S.)