

Anaesthetic Considerations For A Patient With Pneumatocele & Vocal Cord Dysfunction: A Case Report

A Hussain

Citation

A Hussain. *Anaesthetic Considerations For A Patient With Pneumatocele & Vocal Cord Dysfunction: A Case Report*. The Internet Journal of Anesthesiology. 2004 Volume 9 Number 1.

Abstract

Patients suffering from pneumatoceles or bullae usually come to the hospital for thoracic surgery but they can present for non-thoracic surgery as well. The same is true for those who have vocal cord injury. The patients with underlying some disease process are vulnerable to further injury. They need more attention and care when compared to other patients. We report about a patient who developed pulmonary bulla and vocal cord injury at the same time during his hospital stay after road traffic accident and later referred to our hospital for further management.

INTRODUCTION

Pneumatocele is the presence of air filled cavity in the lung parenchyma. It has got the potential to reabsorb spontaneously or expand or rupture during perioperative period resulting in life threatening complications if not properly handled. Simultaneous presence of pneumatocele and vocal cord dysfunction in a patient is rare entity.


CASE REPORT

A 38 years old male, malnourished (40 kg), well oriented in time, space and person with right solitary pulmonary bulla and vocal cord dysfunction was scheduled for the removal of implant from right ankle joint. His voice was breathy in quality. There was no sign of using accessory muscles for breathing. There was no air entry on right upper chest. He also reported diplopia.

He was involved in a road traffic accident (July 2003) and sustained severe head injury, bilateral lung contusions, right sided haemopneumothorax and open fracture of right ankle joint. He remained on ventilator for 3 weeks. A right-sided intercostal tube was inserted. After extubation he developed hoarseness, pneumatocele and communication problems. He was then referred to our hospital for further management. Direct Laryngoscopy was done with fiberoptic bronchoscope as shown in Figure 1.

Figure 1

Figure 1: Vocal cords normal in position and strength but with weak adduction.



During his stay in hospital he underwent open reduction and internal fixation with plate for the right ankle joint under combined spinal and regional anaesthesia. The implant got infected and he came for removal.

All investigations were within normal limits.

Figure 2

Figure 2: Indirect Laryngoscopy showing displaced left arytenoid with fixed left cord & adequate chink.

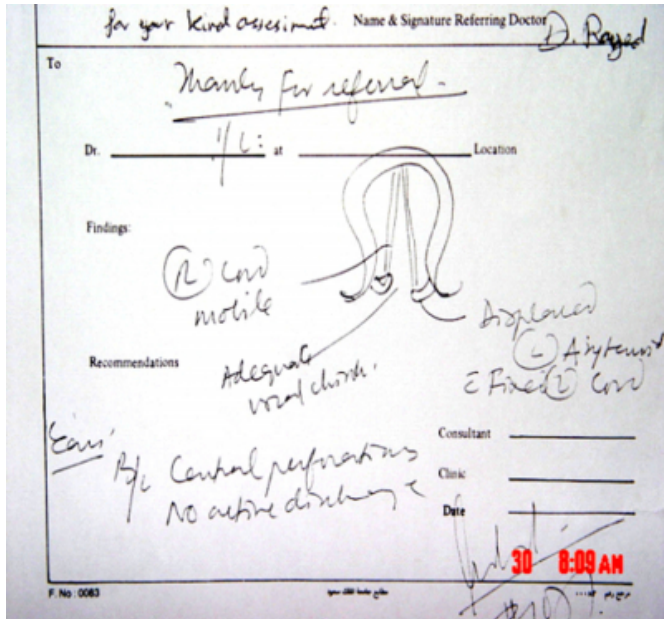
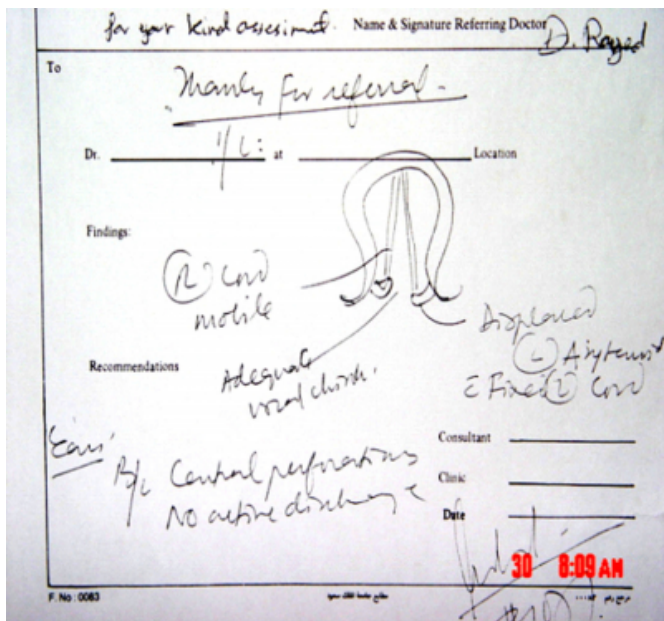


Figure 3

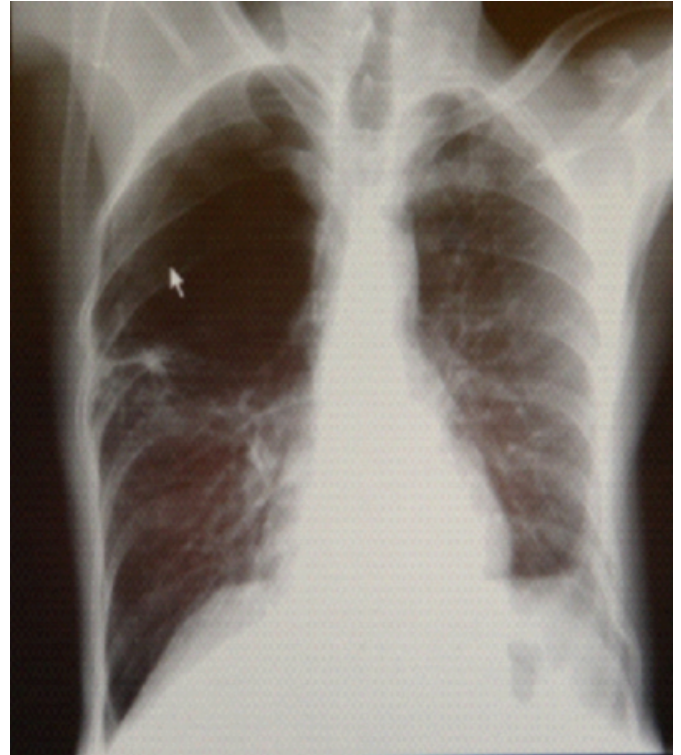Figure 3: Indirect Laryngoscopy showing displaced left arytenoid with fixed left cord & adequate chink.



The infected implant was removed under general anesthesia, breathing spontaneously with oxygen, air, Fentanyl and Sevoflurane with the use of laryngeal mask airway. The perioperative course remained uneventful. Postoperatively a x-ray chest was done as shown in figure 4.

Figure 4

Figure 4: X-ray chest (PA). No change seen postoperatively.



DISCUSSION

Pneumatoceles or pulmonary bullae are thin walled air filled cavities developed within the lung parenchyma. These may be infantile, post infective, emphysematous, traumatic or after ingestion of some hydrocarbons. The anaesthetic considerations, for the management for such cases are:

1. Maintenance of high FiO₂ in perioperative period.
2. If the pneumatocele communicates with the bronchial tree, positive pressure ventilation (PPV), intermittent or continuous (PPV+PEEP) may cause it to expand or rupture if it is complaint producing a situation like tension pneumothorax.
3. If the pneumatocele is highly compliant; tidal volume may be wasted in the form of dead space ventilation.
4. Nitrous Oxide should be avoided whatever the mode of ventilation may be. It causes expansion of air filled cavities in the body because it is 34 times more diffuse able than Nitrogen gas.

Laryngoscopy and tracheal intubation is the most common procedure done in the practice of anaesthesiology. Arytenoid

dislocation and arytenoid subluxation are uncommon laryngeal injuries that occur usually as complications of upper airway instrumentation.²

Direct trauma due to poor Laryngoscopy and intubation technique may result in cricoarytenoid joint injury. Mechanisms of intubation related cricoarytenoid joint injuries have been suggested and includes

1. Anterior displacement is thought to occur when the arytenoid is subluxed directly by the blade of a laryngoscope as it is inserted and lifted in an anterior direction. The same can happen with endotracheal tube tip or stylet.²
2. Posterior dislocation can result from extubation with a partially inflated endotracheal tube cuff.²
3. Posterior glottic stenosis (arytenoids chondritis) secondary to prolonged or traumatic intubation, which ultimately results in fibrosis.³
4. Excessive cuff pressure that compresses the recurrent laryngeal nerve as it enter the larynx.⁴

Sever dysphonia due to recurrent nerve palsy or arytenoid dislocation associated with the use of the LMA has also been reported.^{5,6}

The anaesthetic management of our patient was challenging. Endotracheal intubation can cause further vocal cord injury. With positive pressure ventilation there was a chance of expansion of pneumatocele resulting in tension pneumothorax like condition. Similarly N₂O can expand the lesion as well.

Central neuroaxial block (spinal, epidural or combined spinal and epidural) was excellent choice for this patient.

Problems of laryngoscopy, intubation and ventilation could be avoided with this technique.

We used Laryngeal Mask Airway because there was adequate vocal chink and the sensory supply of vocal cords was intact. Moreover, the patient was with some communication problem. It was a short duration procedure and was being performed in an operating room that was reserved for only infected cases.

CORRESPONDENCE TO

Dr. Altaf Hussain MBBS; DA; MCPS; FCPS. Specialist, Department Of Anaesthesiology (41) King Khalid University Hospital Post Box No.7805 Al-Riyadh 11472 Saudi Arab Phone No.0966-1-4671597 Fax No. 0966-1-4679364 E-Mail: emaildraltaf@hotmail.com emaildraltaf@yahoo.com

References

1. James B.Eisenkraft, Edmond Cohen, and Steven M.Neustein.Clinical Anesthesia .3rd Edition. 1996.Paul Barash et al (editors): 793-94.
2. Yvette V Leslie. Arytenoid dislocation. Available at: <http://www.emedicine.com>. October 23,2003.
3. Robert A Buckmire. Arytenoid Fixation. Available at: <http://www.emedicine.com>. June 5, 2002.
4. Joel A Ernster. Vocal Fold Paralysis, Bilateral. Available at: <http://www.emedicine.com>. May 20,2002.
5. Cros AM, Pitti R, Conil C, et al. Severe dysphonia after use of LMA. Anaesthesiology 1997; 86:498-500.
6. Rosenberg MK, RontalE, Rontal M, et al. Arytenoid cartilage dislocation caused by a laryngeal mask airway treatment with chemical splinting. Anesth Analg1996; 83:1335-1336.

Author Information

Altaf Hussain, MBBS, DA, MCPS, FCPS

Specialist, Department Of Anaesthesiology (41), King Khalid University Hospital