

Perforation Of Meckel's Diverticulum – An Unusual Cause For Acute Abdomen In Pregnancy

C KishanChand, R L, P S S

Citation

C KishanChand, R L, P S S. *Perforation Of Meckel's Diverticulum – An Unusual Cause For Acute Abdomen In Pregnancy*. The Internet Journal of Gynecology and Obstetrics. 2009 Volume 13 Number 2.

Abstract

Symptomatic Meckel's diverticulum is an extremely rare entity in pregnancy, and Perforated Meckel's diverticulum even more. The clinical presentation may be variable as in any case of acute abdomen in pregnancy and the preoperative diagnosis may be hampered by the various anatomical and physiological changes that occur during pregnancy. The treating surgeon should have a high index of suspicion to diagnose such cases, as prompt diagnosis and appropriate treatment is imperative in these cases to prevent high rate of maternal and fetal morbidity. We report one such case of perforation of Meckel's diverticulum in whom the clinical findings on abdominal examinations did not reveal any signs of peritonitis, the patient underwent spontaneous abortion within a few hours after admission, massive pneumoperitoneum was only diagnosed after a CT scan of abdomen was done. Patient had been treated outside at a local hospital for 3 days conservatively, probably due to normal abdominal findings except for distension. When we did an exploratory laparotomy we found to our surprise a perforated Meckel's diverticulum with gross fecal contamination, segmental resection and anastomoses was done. The patient was discharged on the 10th post operative day.

INTRODUCTION

Various disorders of the Gastrointestinal tract can present during pregnancy and in fact 0.2 – 1 % of all pregnant women require non obstetrical general surgery [1], the incidence of acute abdomen during pregnancy being 1 in 500 – 635 pregnancies [2]. Pregnancy with symptomatic Meckel's is an extremely rare entity and requires sound clinical knowledge of the various changes that occur in pregnancy to appropriately interpret the clinical findings. Increased heart rate and cardiac output, physiologic anaemia, leucocytosis and tachycardia may be present even without underlying pathology. Diagnosis may also be difficult as the enlarged uterus stretches the abdominal wall and compresses the viscera, which results in a diminished response to peritoneal irritation and altered or referred pain perception, making the localization of the etiology of the pain more difficult [3]. Treatment of perforation of Meckel's diverticulum remains same in both the pregnant and the non pregnant patient, and requires segmental resection and anastomoses although there is little morbidity after simple diverticulectomy [4].

CASE REPORT

A 24 year old woman in 24th week of her second pregnancy presented to us with history of pain abdomen and abdominal

distension since 3 days, for which she was initially treated conservatively at a local hospital and referred to us for further management. On examination the patient was afebrile and tachycardia was present, blood pressure was normal. The abdomen was distended, it was soft with diffuse tenderness, there were no signs to suggest peritonitis. Blood picture suggested features of septicaemia, within the first few hours of admission, the patient developed bleeding per vaginum and underwent spontaneous abortion.

A CT scan of abdomen was sought which showed massive pneumoperitoneum [fig 1], however no underlying pathology could be identified. Patient was taken for emergency exploratory laparotomy which revealed a perforated Meckel's diverticulum [fig 2] with gross faecal contamination, the diverticulum was attached to the umbilicus in the form of a short and broad fibrous cord, the remnant of the Vitellointestinal duct was divided and segmental resection was done [fig 3]. The uterus was found to be normal corresponding to the duration of pregnancy. Thorough peritoneal toileting was done and abdomen closed. Post operative period was uneventful and the patient was discharged on the 10th post operative day.

Figure 1

Fig 1 : CT scan of abdomen showing massive pneumoperitoneum

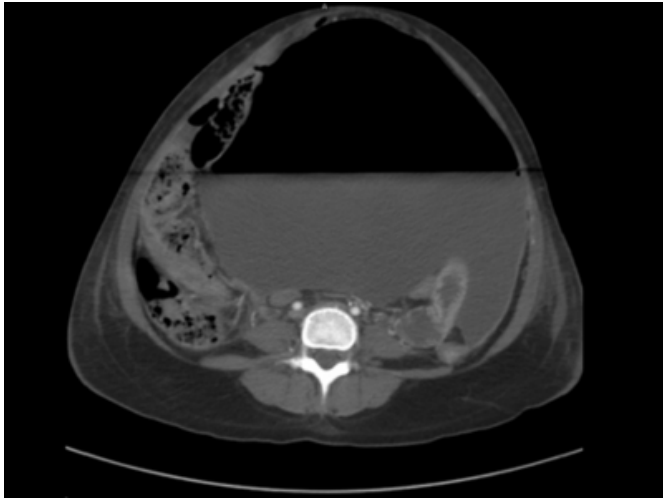


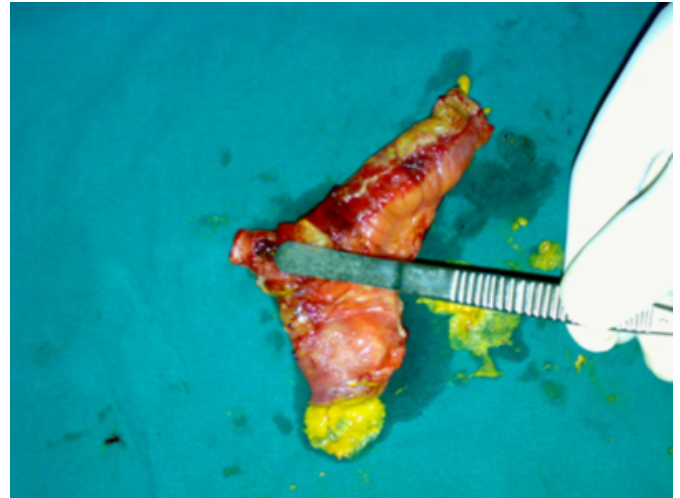
Figure 2

Fig 2 : Perforated Meckels with vitellointestinal duct attached to umbilicus

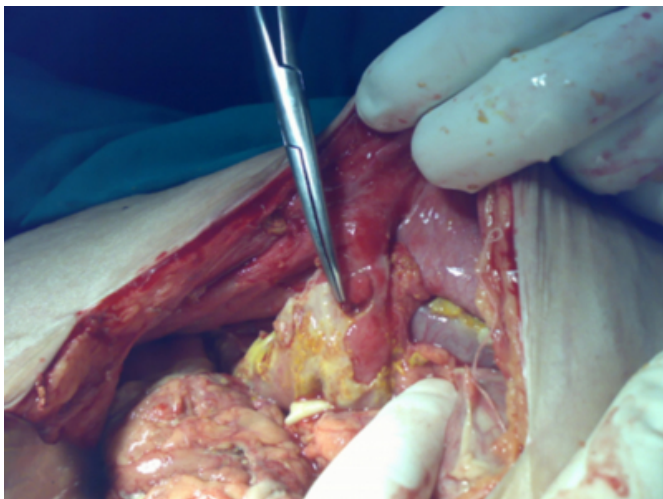

Figure 3

Fig 3 – Segmental resection of Perforated Meckel's diverticulum



DISCUSSION

Meckel's diverticulum complicating pregnancy is an extremely rare entity and to our knowledge only one other case of perforation of Meckel's diverticulum during pregnancy has been reported till date, with the other case reported being a 14 year old girl with 32 weeks of gestation [5]. Other complications of Meckel's diverticulum in the form of diverticulitis and obstruction have also been reported [6,7]. The most common complication of Meckel's diverticulum is haemorrhage. Gastrointestinal bleeding is seen in approximately 55% of patients with Meckel's diverticulum [8]. Perforation of the diverticulum is usually secondary to inflammatory diverticulitis and gangrene, although peptic ulceration also can lead to perforation [9]. More emphasis in pregnancy should be given to preoperative diagnosis taking into consideration the anatomical and physiologic changes occurring in pregnancy, treatment should be prompt as any delay in treatment may lead to significant maternal and foetal morbidity and mortality, in our case delay in the diagnosis lead to foetal mortality which could have been prevented. Surgical treatment remains same in both the pregnant and non pregnant woman and involves segmental resection as described earlier. Although a rare entity, complication of Meckel's diverticulum should be considered in all cases of acute abdomen in pregnancy.

References

1. Malagoni MA . Gastrointestinal surgery and pregnancy. Gastroenterol Clin North Am 2003 ; 32: 181-200.
2. Coleman NT, Triano VA, Rund DA. Nonobstetric emergencies in pregnancy: trauma and surgical conditions. Am J Obstet Gynecol 1997; 177: 497-502
3. Sareh Parangi, Deorah Levine, Antonia Henry et al .

Surgical gastrointestinal disorders during pregnancy .

American Journal of Surgery 2007; 193 (2)

4. Williams RS . Management of Meckel's diverticulum. Br J Surg 1981; 68 : 477-480

5. Rudloff U, Jobanputra S, Smith-Levitin M et al. Arch Gynecol Obstet. 2005 ; 271 (1): 89-93 .

6. Sergio Huerta, Andrew Barleben, Michael A et al .

Meckel's Diverticulitis : A rare etiology of an acute abdomen during pregnancy. Journal of Surgical Education 2006 ; 63(4) : 290-293

7. Ignacio Zapardiel, Jesus DelaFuente-Valero, Sofia

Herrero-Gamiz. Large Meckel's diverticulum complicating pregnancy with intestinal obstruction. Acta Obstetricia et Gynaecologica. Scandinavica. 2009; 88 (4): 492-493

8. Cullen JJ, Kelly KA, Moir CR et al. Surgical management of Meckel's diverticulum. An epidemiologic , population-based study . Ann Surg 1994; 220 : 564-569

9. Fa-Si-Oen PR, Roumen RMH, Croiset van Uchelen.

Complications and management of Meckel's diverticulum – A review. Eur J Surg1999; 165 :674-678

Author Information

Chethan KishanChand

Department of General Surgery, Kasturba Medical College

Ramachandra L

Department of General Surgery, Kasturba Medical College

Prasad S S

Department of General Surgery, Kasturba Medical College