

Argon gas embolism with the use of argon beam coagulation during open hepatic resection

A Cornejo, L Liao, W Kenneth

Citation

A Cornejo, L Liao, W Kenneth. *Argon gas embolism with the use of argon beam coagulation during open hepatic resection*. The Internet Journal of Surgery. 2009 Volume 22 Number 2.

Abstract

We present a case of argon gas embolism with the use of the argon beam coagulator (ABC) during an open partial right hepatic lobectomy. The ABC has gained popularity among surgeons as it is a useful method of electrosurgical coagulation. However, its use has been associated with venous gas embolism resulting in significant morbidity and mortality. In our case the incorrect use of the ABC led to gas embolism with subsequent cardiac arrest. In this report we draw attention to the most common errors that lead to this complication as well as to the preventative measures for a safer use.

CASE REPORT

The patient was a 25-year-old female who underwent an open partial right hepatic lobectomy for a symptomatic 11 x 8cm hepatic adenoma in segment V. General anesthesia was induced with midazolam (1 mg), fentanyl (100 mcg), ketamine (50 mg), propofol (50 mg) and rocuronium (50 mg) and maintained with desflurane in oxygen (5-6% ET). Tracheal intubation was performed and the central venous pressure (CVP), arterial blood pressure, pulse oximetry and capnography (ETCO₂) monitored continuously. The abdomen was entered and the tumor identified in the inferolateral aspect of the right lobe of the liver. In order to minimize bleeding, a bipolar RFA device (Habib 4X-RITA® Model 1500X, Angiodynamics, NY, USA) was introduced in the liver parenchyma multiple times in a circumferential manner along the intended transection plane. We then used the Argon beam Coagulator (ABC) (Conmed 7500; Conmed, NY, USA automatic mode) close to the liver while resecting a 2 cm peripheral segment of the liver parenchyma previously treated with radiofrequency ablation (RFA). This was followed by an abrupt decrease in the arterial pressure to 55/20mm Hg and ETCO₂ to 15mm Hg and an increase in CVP to 22 mmHg. Subsequently the patient went in to cardiac arrest. After 8 minutes of resuscitation with chest compressions, epinephrine (1mg x 3) and atropine (1mg x 1) a cardiac rhythm reappeared. At this point a trans-esophageal echocardiogram (TEE) was introduced and showed a large mass of echo-dense bubbles in the right atrium, right ventricle, and pulmonary artery (Figure 1). No bubbles were seen on the left side of the heart. The TEE

probe was advanced to assess the liver and a large quantity of air was found in the hepatic veins (Figure 2). The patient was placed in Durant's position and the distal CVP port aspirated yielding a large amount of frothy blood. After the patient stabilized the operation was completed. Her postoperative course was remarkable for anoxic brain injury manifested by short term memory loss.

DISCUSSION

The argon beam coagulation is a method of electrosurgical coagulation that has gained popularity among surgeons as it is a useful tool to achieve hemostasis in bleeding surfaces of highly vascularized organs such as the liver. In the argon-enhanced coagulation technique, the electrosurgical current forms an ionized arc within an argon gas stream that flows between an electrode and the tissue resulting in a fine spray of electrical current and uniform coagulation of tissue surfaces (1,2). However, its use has been associated with venous gas embolism leading to life threatening complications including death (3). The risk factors associated with such complication are using the argon gas under pneumoperitoneum, puncturing the liver parenchyma, injuring the hepatic venous system and placing the tip of the ABC electrode in direct contact with the liver surface (2). After reviewing the literature, it seems that regardless of the circumstances most of the cases of argon gas embolism share a similar technical error which is placing the tip of the ABC electrode in close or direct contact with the tissue that is being treated. This is well represented by two open cases where the direct application of the ABC electrode on hepatic

punctures caused by biopsy needles resulted in embolism (4,5).

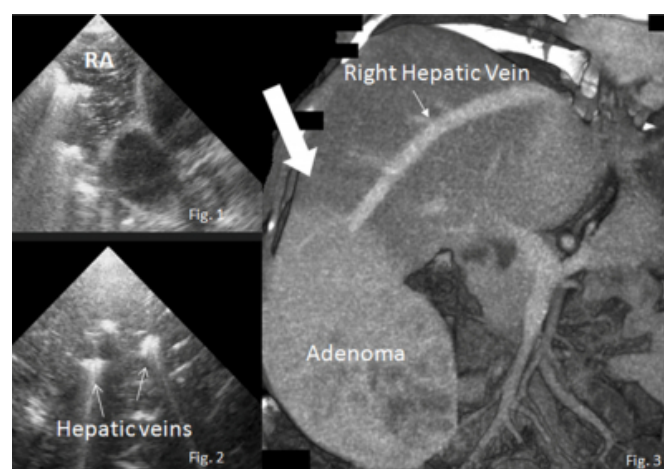
The first cases of argon gas embolism were reported during laparoscopic procedures (6) and therefore, the intra-abdominal over-pressurization caused by the accumulation of argon gas under pneumoperitoneum was thought to lead to the embolic events. However, at present most of the cases of argon gas embolism reported during laparoscopy did not have a significant increase in intra-abdominal pressure at the time of the event. One of them occurred during a laparoscopic hepatic resection after the ABC electrode was placed directly onto a bleeding liver puncture caused by microwave coagulation needles (2) and the other was during a laparoscopic resection of a splenic cyst (3). In the former case it was clear that placing the ABC electrode into the needle hole was the fault. In the latter, the ABC was used to dissect the splenic cyst which entailed continuous and close contact of the electrode with the spleen. A similar error lead to argon gas embolism in our case after we used the ABC very close to the liver while dissecting a peripheral segment of parenchyma previously treated with RFA. This is particularly feasible because if used close enough, the ABC system can reach a depth of penetration of about 5 mm at flows of 0.3 to 2L/min and power of 20 to 80W which makes it useful in the field of interventional pulmonology for ablation of small lesions (7). However, it is not designed for this purpose in highly vascularized tissues such as the liver or the spleen because at a standard flow of 4L/min and power of 150W it can penetrate into the tissue even deeper and enter into the circulation. In fact, a case of argon gas embolism was recently reported during a laparotomy after using the ABC on the diaphragm for the ablation of lesions from ovarian metastasis (8).

Kono et al. reported one case of argon gas embolism during a laparoscopic cholecystectomy where the intra-abdominal pressure raised to 20mm Hg at the time of the event (9). Here the authors reported using the ABC to dissect the gallbladder from the liver bed which likely led to embolism through the same mechanism as mentioned above. Weld et al. evaluated the association of gas embolization with increased intra-abdominal pressures and showed that argon gas embolization was associated with intra-abdominal pressures of 30 to 50mm Hg during laparoscopy in pigs (10). Furthermore, it has been demonstrated that at typical insufflation pressures a pneumoperitoneum caused by argon gas does not lead to embolism as long as it is not directly infused into the circulation (11).

The ABC device used during our case is considered one of the safest among its type because in automatic mode it shuts down or reduces the gas flow when it detects a complete or partial occlusion on the tip. As a result, we do not know the exact flow rate at the time of the accident. According to the manufacturer, it could have been as high as 10L/min during the initial contact with the venous system before its deactivation despite the safety features. During liver surgery, argon gas embolism has been reported with flows that range from 3.8 to 6L/min (9,12). In this regard, it has been demonstrated that the number of gas emboli significantly increases with increasing gas flow rates (2). Nonetheless, if used properly, argon beam coagulation should not have a significant change in the hemodynamic status of the patient. The problem arises when large amounts of gas are surreptitiously infused into the circulation. Junghans et al. exposed pigs to intravenous boli of argon gas and showed that 1ml/kg of argon gas emboli can be lethal in pigs (13). At the standard flow setting of 4L/min the ABC can produce 66ml of gas in only one second which, if embolized, can lead to significant cardiopulmonary dysfunction and be potentially lethal in an average size adult. Furthermore, at such a high flow rate argon gas clearly exceeds pressure in the venous system and can embolize not only through major veins (14) but also through small peripheral veins. In our case, the ABC electrode was not next to a major vein and yet argon gas found its way into the circulation (Figure 3).

Figure 1

Figure 1. TEE showing air bubbles in the right atrium (RA). Figure 2. Air in the hepatic venous system. Figure 3. Site of ABC application in the periphery of the liver (big arrow) in relation to the right hepatic vein.



From our experience we conclude that from all the risk factors, placing the ABC probe in close contact with the liver parenchyma is by far the most hazardous, irrespective

of the approach (laparoscopic vs. open), the anatomical location treated, whether there is exposure of peripheral or major vasculature, the flow settings or the ABC device used. The ABC is a useful tool in surgery and this complication is uncommon; therefore, to maximize patient safety, focus should be on prevention by rigorously following the manufacturer's recommendations. Such recommendations include never placing the electrode tip less than several millimeters from the surgical site and limiting the argon flow setting to the lowest level that will provide the desired clinical effect (this does not apply with the new ABC devices). Also recommended is holding the tip of the electrode at an oblique angle and moving the hand piece away from the tissue after each activation. In order to prevent intra-abdominal over-pressurization during laparoscopic surgery, flushing the abdominal cavity with carbon dioxide between activation periods of the ABC and always leaving one instrument cannula open to the atmosphere is advised (1).

References

1. [No authors listed]. Argon beam coagulation systems. *Health Devices*. 1990;19(9):299-320.
2. Ikegami T, Shimada M, Imura S, et al. Argon gas embolism in the application of laparoscopic microwave coagulation therapy. *J Hepatobiliary Pancreat Surg*. 2009;16(3):394-8.
3. Sezeur A, Partensky C, Chipponi J, Duron JJ. Death during laparoscopy: can one gas push out another? Danger of argon electrocoagulation. *Surg Laparosc Endosc Percutan Tech*. 2008;18(4):395-7.
4. Stojeba N, Mahoudeau G, Segura P, Meyer C, Steib A. Possible venous argon gas embolism complicating argon gas enhanced coagulation during liver surgery. *Acta Anaesthesiol Scand*. 1999;43(8):866-7.
5. Veyckemans F, Michel I. Venous gas embolism from an Argon coagulator. *Anesthesiology*. 1996;85(2):443-4.
6. Croce E, Azzola M, Russo R, Golia M, Angelini S, Olmi S. Laparoscopic liver tumour resection with the argon beam. *Endosc Surg Allied Technol*. 1994;2(3-4):186-8.
7. Reddy C, Majid A, Michaud G, Feller-Kopman D, Eberhardt R, Herth F, Ernst A. Gas embolism following bronchoscopic argon plasma coagulation: a case series. *Chest*. 2008;134(5):1066-9.
8. Kizer N, Zigelboim I, Rader JS. Cardiac arrest during laparotomy with argon beam coagulation of metastatic ovarian cancer. *Int J Gynecol Cancer*. 2009;19(2):237-8.
9. Kono M, Yahagi N, Kitahara M, Fujiwara Y, Sha M, Ohmura A. Cardiac arrest associated with use of an argon beam coagulator during laparoscopic cholecystectomy. *Br J Anaesth*. 2001;87(4):644-6.
10. Weld KJ, Ames CD, Landman J, et al. Evaluation of intra-abdominal pressures and gas embolism during laparoscopic partial nephrectomy in a porcine model. *J Urol*. 2005;174(4 Pt 1):1457-9.
11. Mann C, Boccara G, Grevy V, Navarro F, Fabre JM, Colson P. Argon pneumoperitoneum is more dangerous than CO2 pneumoperitoneum during venous gas embolism. *Anesth Analg*. 1997;85(6):1367-71.
12. Ousmane ML, Fleyfel M, Vallet B. Venous gas embolism during liver surgery with argon-enhanced coagulation. *Eur J Anaesthesiol*. 2002;19(3):225.
13. Junghans T, Böhm B, Neudecker J, Mansmann U, Gründel K. Effects of argon gas embolism during pneumoperitoneum. *Chirurg*. 1999;70(2):184-8; discussion 189.
14. Min SK, Kim JH, Lee SY. Carbon dioxide and argon gas embolism during laparoscopic hepatic resection. *Acta Anaesthesiol Scand*. 2007;51(7):949-53.

Author Information

Agustin Cornejo, M.D

Surgery, University of Texas Health Science Center at San Antonio

Lillian Liao, M.D

Surgery, University of Texas Health Science Center at San Antonio

Washburn W Kenneth, M.D

Transplant Center, University of Texas Health Science Center at San Antonio