

# Post-Caesarean Vesico-Uterine Fistula: A Rare Entity

L Rai, K Ramgopal

## Citation

L Rai, K Ramgopal. *Post-Caesarean Vesico-Uterine Fistula: A Rare Entity*. The Internet Journal of Gynecology and Obstetrics. 2008 Volume 10 Number 2.

## Abstract

Vesicouterine fistula is an uncommon urogenital fistula. The incidence is on the rise because of increasing incidence of cesarean sections. Cyclical hematuria or menouria is an important clinical feature of this fistula which may or may not be associated with urinary incontinence depending on the location of the fistulous tract. We present a case report of vesicouterine fistula following 2 previous cesarean sections. This was successfully managed by cystoscopic fulguration followed by hormonal suppression of menstruation for 3 months. Vesicouterine fistula can be prevented if care is taken to separate the bladder from the uterus during repeat cesarean sections.

## INTRODUCTION

Vesicouterine fistula (VUF) is a rare type of fistula accounting for only 1-4% of all cases of urogenital fistula. However the incidence of vesicouterine fistula has been on the rise due to increasing incidence of lower segment caesarean section (LSCS). It is seen more after repeat caesarean section rather than after the primary <sup>1,2</sup>. There are other newer causes for these fistulas such as uterine artery embolisation <sup>3</sup>.

## CASE REPORT

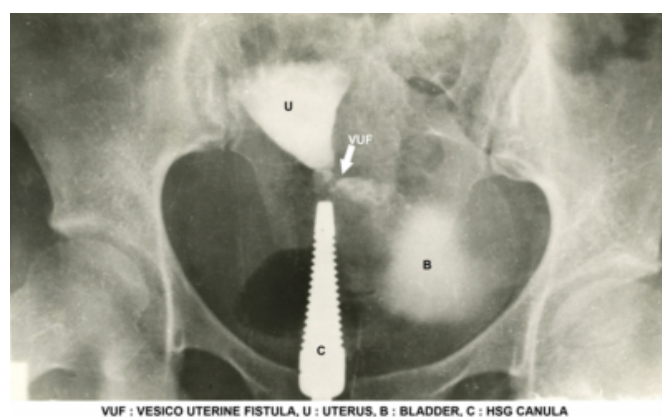
Mrs. S. aged 24 years, a para 2 was admitted with history of haematuria during periods following her last caesarean section, performed 2 years earlier. Menouria or cyclical haematuria was her only complaint and she had no urinary incontinence. She had caesarean section for both the pregnancies in view of cephalopelvic disproportion. The post operative period following her last caesarean section had been uneventful. She noticed menouria when she resumed her cycles 10 months after the LSCS. Her menstrual flow through the genital tract was scanty. Her general and systemic examinations were normal. She had a midline vertical subumbilical caesarean scar. Pelvic examination revealed a normal sized anteverted uterus and fornices were free. Hystero-graphy showed the flow of contrast from the uterus to the bladder, thereby confirming the presence of the fistula. Cystoscopy showed a fistulous opening in the bladder measuring around 7 mm in size (Fig 1). It was supratrigonal in position. Intravenous pyelography showed a normal upper renal tract. The bladder capacity was normal.

The vesicouterine fistula was then treated by endoscopic fulguration after circumscribing the fistula. A parallel mucosal incision was made to allow the fistula to collapse. Continuous bladder drainage was maintained using a Foley's catheter for one week.

She was then put on tablet Medroxyprogesterone continuously for 3 months to suppress menstruation. When the patient resumed her cycles four months later she did not have menouria and her menstrual flow was normal.

## Figure 1

Figure 1: Hystero-graphy reveals the fistula with dye leaking into the bladder from the uterus



## DISCUSSION

Caesarean section is the most common cause for vesicouterine fistula. It is said to be responsible for 83-92% of all VUF <sup>2</sup>. It is interesting to note that prior to 1947 operative vaginal delivery was the commonest cause of

vesicouterine fistula and total urinary incontinence was the usual complaint. However in post caesarean vesicouterine fistula menouria is an important symptom while incontinence may or may not be there <sup>4</sup>. As bladder injury is more during repeat caesarean, the incidence rises with the number of caesarean sections. Jozwik et al also observed that vesicouterine fistulas following caesarean section were more common on the left side of the uterus due to dextrorotation. It can occur after forceps/ vacuum delivery or after vaginal birth following previous caesarean section

Menouria or cyclical vesical menstruation is a rare phenomenon seen in vesicouterine fistula situated above the isthmus. The classical Youssef's syndrome is characterized by menouria, absence of urinary incontinence, vesicouterine fistula and amenorrhoea despite a patent cervical canal. This is explained by the differential pressure gradient between the uterus and the bladder and the sphincteric action of the isthmus, which facilitates passage of blood from the uterus into the bladder <sup>5</sup>.

Our case is not a classical Youssef's syndrome as she was not amenorrhoeic. She had hypomenorrhoea. Absence of leakage of urine is due to the high level of the fistula in the bladder. To demonstrate the fistula the hystrogram should be ideally performed with a short tipped cannula <sup>4</sup>.

Endometriosis of the bladder is a differential diagnosis for menouria. Here, along with other symptoms of endometriosis, menstrual flow occurs through the vagina in addition to menouria. Imaging studies help in outlining the fistulous tract and planning treatment. In patients with menouria, hystero-graphy reveals the fistula with dye leaking into the bladder from the uterus. However in recent times helical CT with sagittal reformation performed soon after hystero-graphy helps one to visualize the fistulous tract clearly <sup>5</sup>. If the fistula is complicated with vaginal leakage of urine, opacification of the bladder reveals the fistula better.

Vesicouterine fistula following caesarean section may heal spontaneously with involution of the puerperal uterus. Spontaneous healing may occur in 5% of cases. When it does not, continuous hormonal therapy can be given to suppress menstruation for 3 to 6 months as first line of therapy. Suppression of menstruation can be tried with progestogens or luteinising hormone. Before resorting to major surgical methods, simple procedure like electrocoagulation of the fistula, as done in our case can be tried. It is successful only in small fistulas. Fistulous tract

heals by fibrosis. There are a few other case reports of this simple technique of cystoscopic fulguration as a primary approach with successful outcome. <sup>6</sup> Laparoscopic repair of VUF is now evolving as a new procedure with minimal blood loss and less morbidity. <sup>7</sup> If the patient is not keen on future conceptions, a total hysterectomy can be done. The other approach is to separate the bladder from the uterine wall, excise the fistula and close the bladder and uterus separately. The bladder should be closed in two layers without tension. To strengthen the repair myouterine flap has been used by Char Et al. while omentum has also been interposed, though the risk of postoperative bowel obstruction is present with the latter <sup>8</sup>. Successful pregnancy and delivery by caesarean section after fistula repair has been reported <sup>9</sup>. However it is always better to prevent the occurrence of fistula by careful dissection of the bladder away from the site of uterine incision during repeat caesarean sections if bladder is pulled up. This simple precaution can prevent a major problem.

## CONCLUSION

Vesico-uterine fistula can still be encountered especially with the wide-spread use of lower segment cesarean section and should be suspected when a multiparous woman with history of repeated cesarean sections, presents with menouria.

## CORRESPONDENCE TO

Lavanya Rai Email – railavanya@yahoo.com  
lavanya.raai@manipal.edu Fax - 91-820-2571934, 2570061 / 62

## References

1. Jozwik-M, Jozwick M, Lotocki- W, Vesicouterine fistula - an analysis of 24 cases from Poland- Int J Gynecol-Obstet, 1997;57(2): 169-72..
2. Hadzi-Djokic JB, Pejic TP, Colovic VC -Vesico-uterine fistula: report of 14 cases BJU Int 2007;100(6):1361-3
3. Sultana C J, Goldberg J, Aizenman. L, Chon JK- Vesicouterine fistula after uterine artery embolisation: a case report- Am J obstet Gynecol 2002 ;187:1726-27
4. Leon - Tracer M: Vesicouterine Fistula - A Review- Obstet & Gynecol Surv 1986; 41(12): 743-753.
5. Smayra T , Ghossain MA, Buy JN, Moukarzel M, Jacob D, Truc JB Vesicouterine Fistulas: Imaging findings in three cases - AJR Am J Roentgenol 2005;184(1):134-142
6. Tarhan F, Erbay E, Penbequl N, Kuyumcuo?lu U : Minimal invasive treatment of vesicouterine fistula: a case report - Int Urol Nephrol 2007;39(3):791-3
7. Das Mahapatra P, Bhattacharyya P Laparoscopic intraperitoneal repair of high-up urinary bladder fistula: a review of 12 cases Int Urogynecol J Pelvic Floor Dysfunct 2007;18(6):635-9.
8. Char-D; Krasnokutsky-S;Frischer-Z, Shah-SM; Bayshtok-J, Khan-SA Surgically correcting a vesicouterine fistula with

a myouterine flap. A case report.J Reprod Med 1997; 42(6): 372- 4  
9. Issa MM, Schmid HP, Stamey TA- Youssef"s syndrome :

Preservation of Uterine function with subsequent successful pregnancy following surgical repair Uro-Int 1994;52(4):220-2

**Author Information**

**Lavanya Rai, MD DGO**

Professor, Department of OBGYN, Kasturba Medical College Hospital

**KS Ramgopal, MS Mch**

Assoc Professor, Department of Urology, Kasturba Medical College Hospital