

Ingested Foreign Body In The Nasopharynx: An Unusual Presentation

M Sajad, M Kirmani, A Patigaroo

Citation

M Sajad, M Kirmani, A Patigaroo. *Ingested Foreign Body In The Nasopharynx: An Unusual Presentation*. The Internet Journal of Otorhinolaryngology. 2008 Volume 8 Number 2.

Abstract

We describe a case of an ingested foreign body into the nasopharynx.

HISTORY

A one and half year old male child was noticed by his parents putting some thing into his mouth, the apprehensive mother performed an immediate finger sweep of his oral cavity after holding the child upside down however the foreign body could not be removed. This gave a false sense of security for the parents and the patient was apparently alright for the next few hours when he developed restlessness, refusal of feeds and could not sleep properly. The child was brought to the emergency department of our SKIMS medical college hospital and in view of the doubtful history of foreign body ingestion a PA view of the neck and chest and abdomen was advised by the resident in emergency which proved out to be inconclusive. However in view of the audible noisy breathing and persistent rubbing of the ear the patient was referred to the ENT department of the hospital for consultation with the ENT specialist.

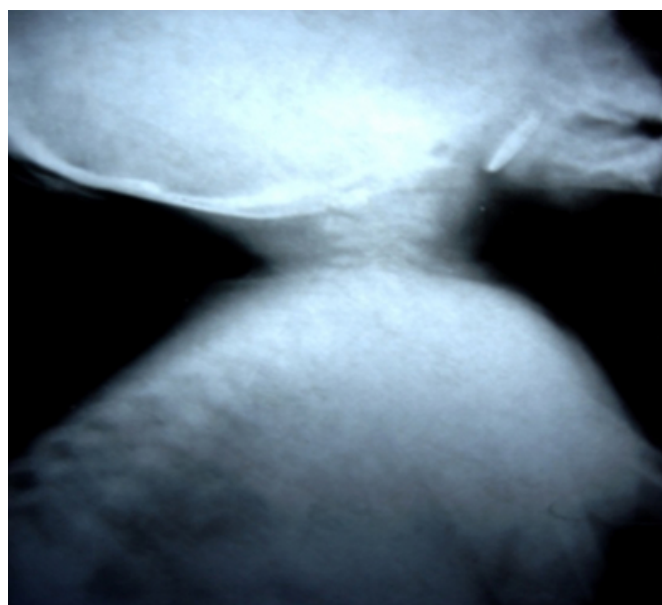
EXAMINATION

An anxious looking, one and half year old child, with inspiratory stridor of sonorous nature and open mouth. The rest of general physical examination was otherwise normal and the bilateral air entry into the chest was normal. The ENT examination of the patient was insignificant except for inspiratory stridor of sonorous type, mouth breathing and the hyperemia of right tympanic membrane. In view of the acute onset of the symptoms and doubtful history of foreign body an urgent X-ray soft tissue neck lateral view was advised.

INVESTIGATION

X-ray nasopharynx showed a radio-opaque shadow in the nasopharynx of the profile similar to coin occupying the space between the adenoids and the soft-palate (plate-I)

Figure 1



TREATMENT

Keeping in view the location of the foreign body, and the age of the patient. The patient was admitted on emergency basis for examination under general anesthesia after discussing the case with the anesthetist. The attempt to pass the Ryle's tube with an idea to retract the plate was unsuccessful. An indirect laryngoscopy mirror was used to visualize the nasopharynx and a 2-rupee coin was dislodged into the oropharynx after retracting the soft-palate anteriorly with tonsillar pillar retractor and using the negus curved artery forceps to gently manipulate the foreign-body and remove it. The postoperative period of the patient was uneventful and the patient was discharged the next day.

DISCUSSION

Foreign bodies are seldom seen in the nasopharynx in fact the condition does not merit mention in the standard text. The only data regarding this clinical entity is in the form of occasional case report.^{1,2,3,4} Most objects reach this space as a result of negligence at the time of surgeries on throat as left over swabs after adenoidectomy, broken blade of adenoid curette or fragments of other instruments. It is very rare for the ingested foreign body to get lodged up in this space. The probable cause of the ingested foreign body getting lodged in the nasopharynx in our case could be the emergency maneuver used by the attendants at home i.e. holding the child head down and performing the finger sweep of oral cavity.

The foreign body in the nasopharynx is an emergency as the foreign body seldom remains lodged up in the nasopharynx for too long and tends to pass rapidly into the larynx or esophagus. The chances of the foreign body nasopharynx dropping into larynx could result in fatal consequences and hence the emergency removal of the foreign body nasopharynx is recommended form of treatment and for that matter minimum disturbance to the patient and examination under general anesthesia is the better alternative.^{1, 2}

The presented case is of clinical significance for the patient of foreign body ingestion who has been subjected to the first aid maneuver like head down and performing finger sweep,

although such maneuvers are handy as first aid one should not lower his guard in cases where the maneuver could not retrieve any foreign body and the attending doctor has to ask himself is it in the nasopharynx and hence the importance of early lateral radiograph of upper airway should include the nasopharynx also?² The patients of such a age group with such a complaint should be least irritated and examined under general anesthesia as procedures like nasal endoscopy or posterior rhinoscopy to visualize such a foreign can have drastic consequences if conducted in an awake child. And rarely cases have been reported of foreign bodies staying in the nasopharynx for years together.^{4,5,6}

References

1. Gendeh BS, Gibbs AG. An unusual foreign body presenting in the nasopharynx. *Journal Laryngol Otol* 1988;102:641-2. Case Reports
2. Parker AJ, Bingham BJ, Osborne JE. The swallowed foreign body: is it in the nasopharynx? : *Postgrad Med J*. 1988 Mar;64(749):201-3. Case Reports
3. Gulia Joginder Singh, Kumar R, Sachdeva OP. Unusual foreign bodies in nasopharynx and bronchus. *The Indian journal of pediatrics*: 2002: 69 (3): 273-4,case reports
4. Oysu C, Yilmaz HB, Sahin AA, Kulecki M. Marble impaction in the nasopharynx following oral ingestion. *Eur Arch Otorhinolaryngol* 2003;260:522-3.
5. Ogut F, Bereketoglu M, Bilgen C, Totan S. A metal ring that had been lodged in a child's nasopharynx for 4 years. *Ear Nose Throat J* 2001;80:520-2.
6. Eghtedari F. Long lasting nasopharyngeal foreign body. *Otolaryngol Head Neck Surg* 2003;129:293-4.

Author Information

Mir Sajad

Registrar, Department of Otorhinolaryngology, SKIMS MC

Masood A. Kirmani

Asst.professor, Department of Otorhinolaryngology, SKIMS MC

A.R. Patigaroo

Professor and Head of Deptt, Department of Otorhinolaryngology, SKIMS MC