

# Diagnosis of a Thoracic Aortic Arch Aneurysm in a 63-year-old Female by CT-Angiography

N Saeed, M Majid

---

## Citation

N Saeed, M Majid. *Diagnosis of a Thoracic Aortic Arch Aneurysm in a 63-year-old Female by CT-Angiography*. The Internet Journal of Radiology. 2005 Volume 5 Number 1.

## Abstract

**Introduction:** Thoracic aortic aneurysms are dilated segments of the thoracic aorta. Large aneurysms are at risk of rupture and fatal prognosis. TAA is usually asymptomatic and is discovered incidentally. Radiography, Computed tomography, MRI, Ultrasound and angiography have all been used in the evaluation of TAAs.

**Method and materials:** An aortic arch aneurysm was suspected based on the findings of the chest X-Ray in a 63 year old female. The CXR was part of a preoperative evaluation. Since the patient refused invasive investigations, a CT- angiography was carried out via the Philips 8000X multi-detector multi slice spiral CT scanner and three dimensional images were constructed to evaluate the characteristics of the aneurysm.

**Results:** A 55X48mm aneurysm was detected in the aortic arch with a calcified neck region.

**Conclusion:** Even in countries like Iran when life-threatening anomalies develop in large vessels, ct-angiography should be considered as a non-invasive, low-cost, and low-complication alternative to existing methods of evaluation.

## INTRODUCTION

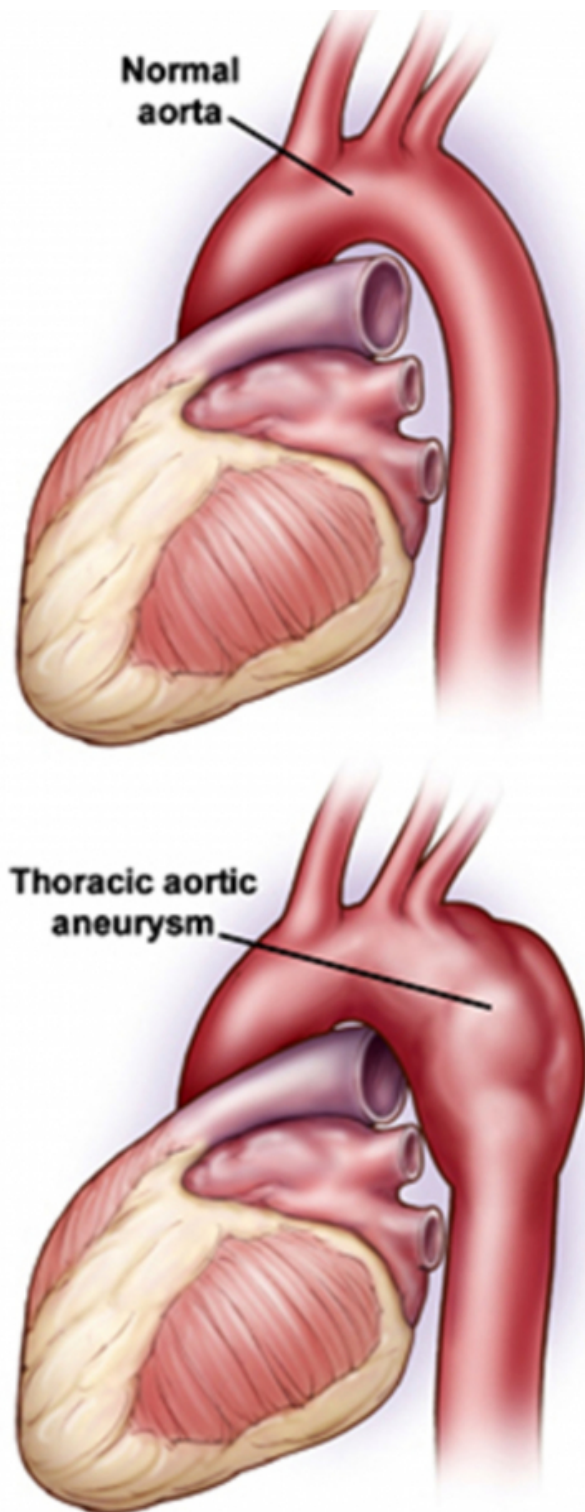
The aorta, acting as the main conduit through which cardiac output is delivered to the systemic arterial bed, is continuously exposed to high pulsatile pressure and shear stress, making it prone to mechanical injury. It is also more prone to rupture than other vessels, particularly with the development of aneurysmal dilation. This is because aortic wall tension (governed by the law of Laplace, i.e. proportional to pressure x radius) is intrinsically high<sup>1</sup>. The following case report looks at thoracic aortic aneurysms and

the use of ct-angiography to diagnose and evaluate an asymptomatic case suffering from the disorder.

A thoracic aortic aneurysm is the term used to describe when a segment of the artery is dilated by more than 50% of its original diameter (fig. 1). Aneurysms of the thoracic aorta may be divided into those involving the ascending thoracic aorta, the aortic arch and the descending aorta. The location of the aneurysm affects clinical manifestations, natural history and treatment options, as well as offering clues as to the etiology.

**Figure 1**

Figure 1



carried out as the next diagnostic step and a clearly dilated aorta with an approximate diameter of 5 centimeters was observed. For complementary information, the cardiologist asked for either Transesophageal Echocardiography or aortic angiography to be performed. Refusing to undergo any invasive measures, the patient allowed neither of the two investigations. Therefore, CT-angiography was carried out as the alternative imaging procedure to determine the necessary information for management.

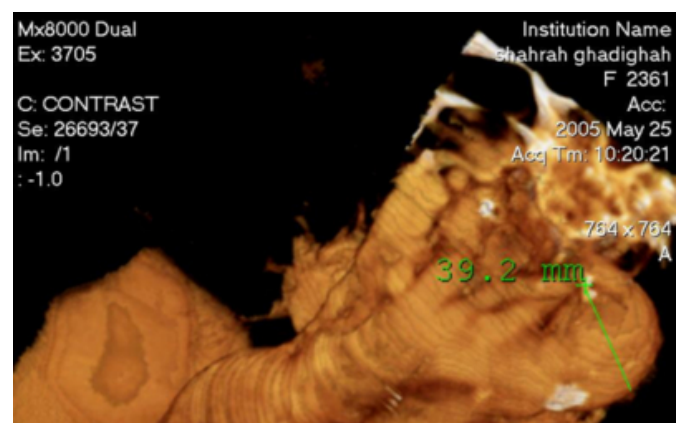
## INSTRUMENTATION AND METHOD

A Philips 8000X multi-detector multi-slice spiral CT scanner was used in the procedure. First 106 axial slices were obtained without contrast enhancement. The thickness of each slice was 3.2mm with an increment of 1.6mm. The scanner was pitched at 1.50 and a table speed of 7.5 cm/S was set. With a normal resolution and an image matrix of 512X512 the total scan time lasted about 24 seconds.

The injection protocol was planned based on the time-lapse curve and the optimal enhancement of the aortic arch, specially in the aneurysmal segment. A non-ionic contrast medium (Omnipaque) was used with a dose of 140cc injected intravenously at a rate of 3.5cc per second, through the cubital vein. The first images were obtained 8 seconds after the initial injection by and injector pump. Later, three-dimensional images were reconstructed (fig.2).

**Figure 2**

Figure 2

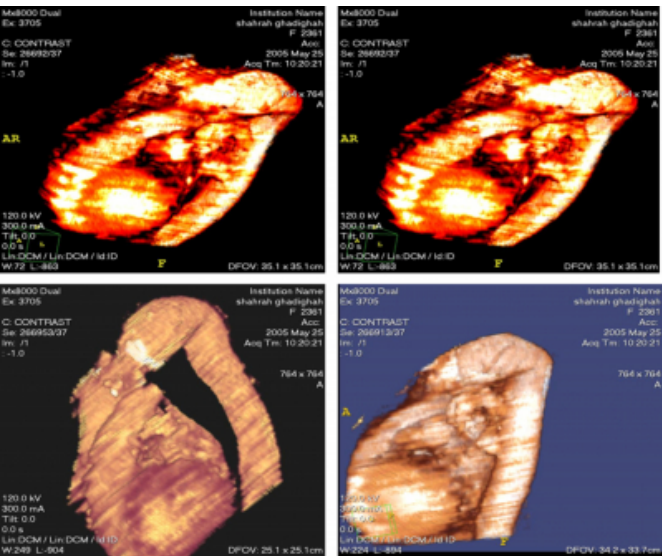


## CASE HISTORY

The patient was a 63-year-old female, admitted to 22-Bahman hospital for a cataract operation on her left eye. In the course of the preoperative evaluations, the chest X-ray revealed a prominent aortic contour. Echocardiography was

Figure 3

Figure 3: Aortic arch aneurysm



RESULTS

The reconstructed 3-dimensional images clearly demonstrated a thoracic aneurysm (55X48mm) in the aortic arch (fig-2). The vessel wall was calcified at the site of lesion and no dissection was visible. Intramural or intraluminal thrombosis was not observed.

DISCUSSION

Thoracic Aortic Aneurysms (TAA) may be caused by atherosclerosis, cystic medial necrosis, syphilis, mycotic aneurysms, rheumatoid disorders, trauma, and inherited diseases (table 1).

Figure 4

Table 1: Aetiology of thoracic aortic aneurysms

<ul style="list-style-type: none"><li>• Atherosclerosis - cause of the majority of descending aortic aneurysms</li><li>• Cystic medial necrosis - cause of the majority of ascending aortic aneurysms</li><li>• Syphilis - usually affects ascending the aorta and arch rather than the descending aorta</li><li>• Mycotic aneurysms - site depends on source of infection, e.g. endocarditis related, infected angiography catheters or direct infection from mediastinal lymph nodes (e.g. TB)</li><li>• Marfans Disease – up to 36 % of patients are affected</li><li>• Rheumatoid disorders - e.g. ankylosing spondylitis, which primarily affects the ascending aorta</li><li>• Trauma</li><li>• Other - e.g. associated with coarctation.</li></ul>
---

Rupture of the aneurysm is the most common cause of death, with rates ranging from 42 to 70%. Size is an important factor in risk of rupture, which escalates rapidly once the diameter of the aorta exceeds 5-6cm. The five year risk of

rupture increases up to five-fold for aneurysms 6cm or greater. Thoracic aneurysms enlarge at an average rate of 0.2-0.4cm per year.

Many patients with thoracic aortic aneurysms are asymptomatic at the time of presentation and detection of the aneurysm occurs during investigation for unrelated reasons, or as part of screening in certain familial cases (e.g. Marfan syndrome)<sub>2</sub>. In this case, the preoperative evaluations for an ophthalmologic operation lead to the diagnosis. Symptoms tend to develop late in the course of aneurysmal dilation and result from local effects on surrounding structures. Ascending aortic aneurysms may cause aortic valvular regurgitation, giving rise to symptoms of congestive cardiac failure. Enlargement of the sinuses of Valsalva may cause myocardial ischemia, or infarction due to arteries, or thromboembolism. Alternatively, these sinuses may rupture directly into the right ventricular cavity, right atrium or pulmonary artery, causing heart failure associated with a continuous murmur.

As in the case presented, the chest x-ray is frequently the first test to suggest the diagnosis in asymptomatic patients. However, approximately 17% of patients with aneurysms or dissections will have no abnormalities on chest radiography. Computer tomography (CT) is the most widely used non-invasive technique for the diagnosis of thoracic aneurysms, revealing size, location and presence of thrombus or chronic dissection. It is a useful method of assessing the rate of growth and determining the timing of surgery. While multi-detector capability has improved the accuracy and rapidity of acquisition, such techniques are not widely utilized in Iran, partly due to the lack of facilities and trained personal.

As explained in the above case, the CT three-dimensional reconstruction, displayed using a combination of maximum intensity projection and volume rendering<sub>3</sub>, can completely determine the length and diameters of the aneurysm as well as the length of the necks, the origin of the major branch vessels, and the extension of the aneurysm<sub>4,5,6</sub>. These data, obtained non-invasively, provide the endovascular specialist with essential information for the determination of the size, design, and deployment sites of the endograft or other management techniques.

Similarly, Magnetic Resonance angiography can provide the same information but does not show mural or thrombus calcifications which are essential for iliac access during endovascular repair<sub>7</sub>, and it has the advantage of being suitable for patients with renal insufficiency. Three-

dimensional images are displayed primarily in a maximum intensity projection mode and supplemented with axial plane T1-weighted sequences to show the lining of a mural thrombus. Stepped-table and bolus-timing strategies continue to improve the overall image quality<sup>8,9</sup>, providing a more accurate definition of the extension of the aneurysm. As suggested by Neschis et al.<sup>10</sup>, in the future MR angiography will be successfully used as the only technique for the design of the aortic endograft, with the advantages of its non-invasiveness and the absence of nephrotoxic risks.

### CONCLUSION

Although MR angiography is predicted to become the only method of evaluation for aneurysms in the future, since such techniques seem too farfetched for the healthcare budget here in Iran, it looks as ct-angiography can be a good non-invasive and relatively low-cost alternative to the available techniques. It has a low risk of complications, the cost is reasonable and the technique used is simple with a significant diagnostic value. In using ct-angiography as the method of choice, the experience of the radiologist and the number of cuts obtained are of most importance.

Thus, when life-threatening anomalies develop in large vessels, ct-angiography should be considered as a non-invasive, low-cost, and low-complication alternative to

existing methods of evaluation.

### References

1. May J, White GH, Waugh R, et al. Endovascular treatment of abdominal aortic aneurysms. *Cardiovasc Surg* 1999; 7: 484-90.
2. Steckmeier B. Epidemiology of aortic disease: aneurysm, dissection, occlusion. *Radiologe* 2001; 41: 624-32.
3. Smith PA, Heath DG, Fishman EK. Virtual angioscopy using spiral CT and real-time interactive volume-rendering techniques. *J Comput Assist Tomogr* 1998; 22: 212-4.
4. Qanadli SD, Mesurolle B, el Hajjam M, et al. Helical computed tomography of the aorta and its branches. *J Radiol* 1999; 80: 998-1010.
5. Willmann JK, Lachat ML, von Smekal A, Turina MI, Pfammatter T. Spiral-CT angiography to assess feasibility of endovascular aneurysm repair in patients with ruptured aortoiliac aneurysm. *Vasa* 2001; 30: 271-6.
6. Imai Y, Urayama S, Uyama C, et al. A system for computer-assisted design of stent-grafts for aortic aneurysms using 3-D morphological models. *Cardiovasc Intervent Radiol* 2001; 24: 277-9.
7. Tillich M, Hill BB, Paik DS, et al. Prediction of aortoiliac stent-graft length: comparison of measurement methods. *Radiology* 2001; 220: 475-83.
8. Amanuma M, Hirata H, Tanaka J, et al. Table-moving contrast-enhanced MR angiography of abdominal aortic aneurysm. *Nippon Igaku Hoshasen Gakkai Zasshi* 1999; 59: 760-4.
9. O'Connell MJ, Murray JG. Value of subtraction technique in Gd-DTPA-enhanced magnetic resonance angiography of the thoracic aorta. *Clin Radiol* 2001; 56: 545-9.
10. Neschis DG, Velazquez OC, Baum RA, et al. The role of magnetic resonance angiography for endoprosthetic design. *J Vasc Surg* 2001; 33: 488-94.

**Author Information**

**Naghibi Saeed, M.D.**

Department of Radiology, Bahman Hospital, AZAD University of Medical Sciences

**Mirsadrai Majid, M.D.**

Department of Radiology, Bahman Hospital, AZAD University of Medical Sciences