

# Prostatic Abscess: Easy to diagnose, difficult to treat

S Dalal, R Sahu, Nityasha, R Dahiya

## Citation

S Dalal, R Sahu, Nityasha, R Dahiya. *Prostatic Abscess: Easy to diagnose, difficult to treat*. The Internet Journal of Surgery. 2009 Volume 23 Number 2.

## Abstract

Prostatic abscesses are uncommon in clinical practice because early antibiotic therapy initiation has reduced complications of prostatitis. But these abscesses are probably underdiagnosed and their true incidence might emerge if trans-rectal ultrasonography is to become routine in the assessment of prostatic disease in males. We encountered an elderly, diabetic male, who presented with features of bladder outflow obstruction with fever. Prostatic abscess in this case was indicated by digital rectal examination and was confirmed by transrectal sonography. The abscess was successfully drained by transrectal needle aspiration under ultrasonographic guidance. Trans-rectal sonography is the most reliable method to diagnose prostatic abscess and trans-rectal drainage is the first choice for therapy because of the lower risk of complications compared with surgery.

## INTRODUCTION

The incidence of prostatic abscess has decreased markedly because of widespread use of potent antibiotics and decreased incidence of gonococcal urethritis. Data in the literature show that prostatic abscess is diagnosed only in 0.5% of patients hospitalized for prostatic symptoms.<sup>1</sup> The differential diagnosis between acute bacterial prostatitis and prostatic abscess is difficult to make on the basis of clinical examination. New imaging methods, especially transrectal sonography, are particularly useful for early recognition and treatment of such collections. USG-guided transrectal drainage represents a simple alternative to more complex and dangerous treatments that can cause hematogenous spread.

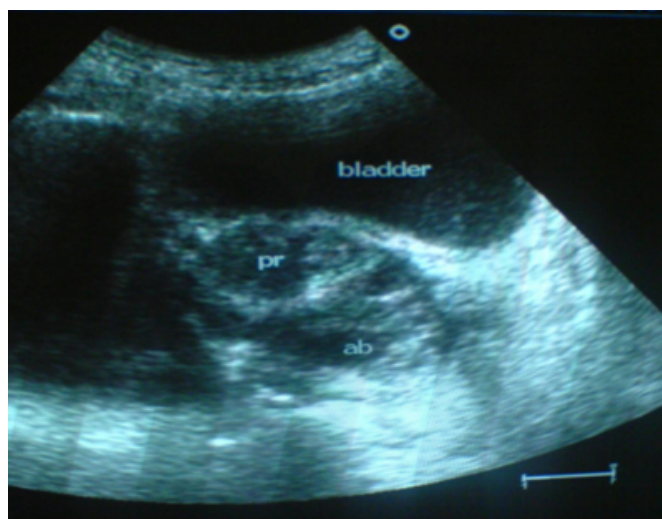
## CASE REPORT

A 60-year-old male was admitted to our hospital with complaints of fever for 10 days and acute retention of urine for 5 days, for which he was catheterised by a private practitioner. He was a known case of diabetes mellitus for the last 10 years, for which he was on oral hypoglycemics. There was a history of lower urinary tract symptoms (LUTS) in the past. His external genitalia and lower abdomen were normal on clinical examination. Per-rectal examination revealed an acutely tender prostate with clinical fluctuations in the left lobe. The fasting and postprandial blood sugar of the patient was 290 and 336mg%, respectively, indicating that his diabetes was uncontrolled. His ELISA for HIV was non-reactive. USG of the abdomen revealed grade-I

hydronephrosis bilaterally and trans-rectal ultrasound (TRUS) showed a hypoechoic lesion of 5.4 × 4.5cm with internal echoes in the left lobe of the prostate (Fig.1).

## Figure 1

Fig. 1: Ultrasonography showing a hypoechoic lesion in the left lobe of the prostate



First of all, the patient was put on regular insulin to control his blood sugar and at the same time was started with parenteral antibiotics, i.e. Levofloxacin and Metrogyl. The prostatic abscess was then aspirated in left lateral position with an 18-gauge spinal needle introduced per-rectally under USG guidance. The stylet was removed and, once the abscess was entered, about 20cc of thick pus were aspirated. Intravenous antibiotics were started two days before and

continued five days after aspiration. After abscess drainage, the patient had a striking symptomatic improvement within 24 hours. He was discharged after one week of the aspiration of the abscess in a healthy condition, after switch over to oral antibiotics.

## DISCUSSION

Since the advent of potent antibiotics, prostatic abscess has become increasingly uncommon. Effective treatment of gonorrhea, a major cause of prostatic abscess in the past, has contributed significantly to this phenomenon. The pathogenesis of the disease has been thought to involve two distinct mechanisms: The first mechanism occurs in older individuals with pre-existing bladder outlet obstruction, in whom a prostatic abscess develops secondary to a lower urinary tract infection. The abscess is caused by *E. coli* or other coliform bacteria in this group. The second mechanism involves a much smaller group of patients with a wide age distribution. The causative organism is usually staphylococcus, as a result of metastatic abscess in the prostate from a focus of infection elsewhere.<sup>3</sup> Predisposing factors for the development of a prostatic abscess are diabetes mellitus, urethral catheterisation/instrumentation and chronic bacterial prostatitis.<sup>4</sup> Chronic dialysis patients with prostatic inflammation have frequent abscess collections. A relatively new group of patients at risk are those with suppressed immune system, caused by AIDS, chemotherapy, etc.<sup>5</sup>

The differential diagnosis between acute prostatitis and prostatic abscess has always been difficult. The distinguishing palpatory finding of a tender, fluctuant prostate on rectal examination has not been a constant occurrence. Recent imaging methods such as TRUS (trans-rectal ultrasound) have been suggested as a noninvasive technique very helpful for the diagnosis of pathological conditions of the prostate.<sup>6</sup> The sonographic pattern of prostatic abscess is characteristic and can be easily differentiated from other glandular lesions.<sup>6</sup>

While it is generally accepted that surgical drainage is the most important step in the treatment of a prostatic abscess, the exact method of drainage remains somewhat controversial. The surgical approaches are transurethral or

transperineal, but these procedures are not currently used because perineal incision can cause impotence due to nerve damage, and transurethral resection can cause widespread haematogenous spread of infection.<sup>7</sup> Currently, percutaneous/transurethral treatment of prostatic abscess under USG guidance is preferred to surgery because of its lower risk of complications. Trans-rectal sonography also makes it possible to follow up abscesses that were not treated with drainage or puncture but with antibiotic therapy alone.<sup>8</sup>

The patient in consideration was an elderly male with symptoms typical of prostatic abscess including a tender, fluctuant prostate on digital rectal examination. He was having uncontrolled diabetes mellitus as a predisposing factor for prostatic abscess. His diagnosis was confirmed by TRUS and the abscess was successfully treated by USG-guided transrectal aspiration combined with antibiotic therapy. The case is being reported to enlighten the readers about the following facts:

- Trans-rectal ultrasound should be a routine in the assessment of prostatic diseases to find the true incidence of prostatic abscesses.
- Once diagnosed, they should be treated immediately by TRUS-guided aspiration, as this is a powerful tool for the management of patients with prostatic abscess.

## References

1. Trapnell J, Roberts M. Prostatic abscess. *Br J Surg* 1987; 57: 565-69.
2. Chitty K. Prostatic abscess. *Br J Surg* 1957; 44: 599-601.
3. Dajani A, O'Flynn JD. Prostatic abscess. A report of 25 cases. *Br J Urol* 1968; 40: 736-39.
4. Jacobson JD, Krist E. Prostatic abscess: A review of literature and presentation of 5 cases. *Scand J Urol Nephrol* 1993; 27: 281-84.
5. Trauzzi SJ, Kay CJ, Kaufman DG, Lowe FC. Management of prostatic abscess in patients with human immunodeficiency syndrome. *Urology* 1994; 43: 629-33.
6. Lee F Jr, Lee F, Solomon MH, Staub WH, McLeary RD. Sonographic demonstration of prostatic abscess. *J Ultrasound Med* 1986; 5: 101-02.
7. Meares EM Jr. Prostatic abscess. *J Urol* 1986; 136: 1281-84.
8. Cytron S, Weinberger M, Pitlik SD, Servadio C. Value of transrectal ultrasonography for diagnosis and treatment of prostatic abscess. *Urology* 1988; 32: 454-58.

**Author Information**

**Satish Dalal, M.S., F.A.I.S., F.I.C.S.**

Associate Professor, Department of General Surgery, Pt.B.D.Sharma Postgraduate Institute of Medical Sciences (P.G.I.M.S.),

**Rajan Sahu, M.S.**

Assistant Professor, Department of General Surgery, Pt.B.D.Sharma Postgraduate Institute of Medical Sciences (P.G.I.M.S.),

**Nityasha, M.S., D.N.B., F.A.I.S.**

Assistant Professor, Department of General Surgery, Pt.B.D.Sharma Postgraduate Institute of Medical Sciences (P.G.I.M.S.),

**R.S. Dahiya**

Senior Professor, Department of General Surgery, Pt.B.D.Sharma Postgraduate Institute of Medical Sciences (P.G.I.M.S.),