

# Subclavian Artery Injury Following Isolated Clavicle Fracture, Which To Repair First?

S Boulis, S Samad

## Citation

S Boulis, S Samad. *Subclavian Artery Injury Following Isolated Clavicle Fracture, Which To Repair First?*. The Internet Journal of Orthopedic Surgery. 2005 Volume 3 Number 2.

## Abstract

Blunt subclavian artery trauma following clavicle fracture is rare. Some controversy exists in the literature regarding the sequence of surgery. We report a case where vascular repair preceded clavicular fixation with excellent outcome. We positioned the graft far away from the fracture site and therefore subsequent manipulation to reduce the fracture was safer. The final decision should be a team one, made by the vascular surgeon, the orthopaedic surgeon and the anaesthetist.

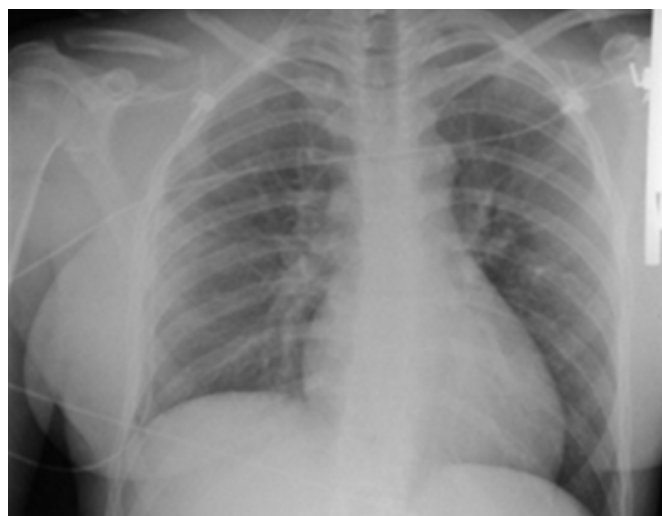
## CASE REPORT

A 23-year-old right-handed woman attended the emergency department after being thrown from her horse. Examination revealed a large haematoma over the right clavicle and absent right brachial and radial pulses. Neurological examination was normal. Early vascular input was sought.

Radiographs confirmed a displaced fracture of the right clavicle at the junction of the medial 2/3 and distal 1/3 (Figure 1). There were no other injuries. Duplex studies were performed in the emergency department and confirmed absent radial pulse with no Doppler signal. Formal angiography showed occlusion of the proximal subclavian artery just beyond the origin of the right internal mammary and vertebral arteries. The occlusion measured ~ 5 to 6 cm with sluggish reconstitution of the right axillary artery distally. Radiological stenting was attempted and failed.

## Figure 1

Figure 1: AP radiograph of the chest showing a displaced fracture of right clavicle. There is no associated pneumothorax or other injuries.



In view of the vascular compromise the joint decision was made to perform revascularisation first as an emergency. It was decided to position the graft far away from the fracture site. A right common carotid to axillary artery bypass was performed using reversed long saphenous vein graft. The graft was positioned in a tunnel crossing the medial end of the clavicle far away from the fracture site. Patency of the graft was confirmed with Doppler ultrasound intra-operatively. The clavicular fracture was opened through a separate incision along medial third of the clavicle and then reduced with gentle manipulation using reduction forceps. The fracture was fixed with a locking plate on the superior surface of the clavicle using unicortical screws. The patient

made a good recovery and the fracture went on to heal with callus formation.

### **DISCUSSION**

Although clavicle fractures are common, accounting for 5 – 10 % of all instances of adult trauma, subclavian artery injury is a rare complication. This is mainly due to protection by the scalene muscles. Blunt trauma injuries to the subclavian artery typically occur at the proximal and mid-portion of the vessel (1). Clinical features include; clavicle haematoma, bruit or neurovascular deficit to the upper extremity or haemodynamic instability (2).

When assessing these injuries, a careful evaluation of vascular supply is crucial to prevent delayed diagnosis. A delay reduces the chance of successful repair, with the optimal period for restorative surgery occurring within the first 6-8 hours (1). It is also important to exclude involvement of other structures such as the subclavian vein, brachial plexus and underlying lung. Important management issues for fractures complicated by vascular injuries include early recognition, angiography and involvement of vascular team (2, 3).

Controversy exists about the order of initial management of combined injuries and whether orthopaedic stabilisation should precede vascular repair or vice versa. Proponents of early vascular repair point to a reduced ischaemic time, therefore improved limb viability, reduced risk of in-situ thrombosis as well as reduced risk of iatrogenic disruption of revascularisation due to subsequent orthopaedic procedure. Even in the absence of primary vascular injury internal fixation of the clavicle can result in secondary vascular damage.

Advantages of early orthopaedic repair include: stabilisation of the extremity thereby aiding vascular repair, improving the exposure of vascular injury and reduced risk of thrombosis in a recently completed vascular repair during subsequent manipulation to reduce the fracture.

Time is an important factor in decision-making and if significant delay has occurred then arterial repair is indicated

initially. If the patient presents within a reasonable time then the fracture may be stabilized very quickly prior to vascular repair. Stability of the fracture is also a consideration. Relatively stable injuries can undergo vascular repair with little risk of subsequent disruption in order to decrease the duration of ischaemia. If however the fracture is unstable and the extremity cannot be stabilized for proper exposure of vascular injury, the orthopaedic repair is performed first. One option in this scenario is a temporary intraluminal shunt to maintain blood flow (4).

We chose to perform vascular repair first for multiple reasons. Firstly, the absence of pulses and capillary refill made restoration of the blood supply to the limb a first priority. Secondly, we decided to position the graft far away from the fracture site and therefore subsequent manipulation to reduce the fracture was safer. The final decision should be a team one, made by the vascular surgeon, the orthopaedic surgeon and the anaesthetist.

### **CONCLUSION**

Despite being a common and, in most cases, uncomplicated injury, the possibility of underlying vascular injury must be excluded in cases of isolated clavicle fracture. Sequence of surgery depends on various factors and close liaison with the vascular team is paramount.

### **CORRESPONDENCE TO**

Miss S. Boulis (First Author)  
SpR in Trauma & Orthopaedics  
Corresponding Author  
126 Sulgrave Road  
London W6 7PU, UK

### **References**

1. Cakir O, Subasi M, Eren N. Treatment of vascular injuries associated with limb fractures. *Ann R Coll Surg Engl* 2005; 87 348-352
2. Katras T, Rush DS, Davis D, Bell TD, Stanton TE. Subclavian arterial injury associated with blunt trauma. *Vas Surg* 2001; 35 (1) 43-50
3. Rozycki GS, Tremblay LN, Feliciano DV, McClelland WB. Blunt vascular trauma in the extremity: diagnosis, management, and outcome. *J Trauma* 2003; 55 814-24
4. Mandel AK, Jordan J, Missouri CG. Fractured clavicle and vascular complications. *Emerg Med J* 2004; 21 (5) 648

**Author Information**

**Samah Boulis, BSc MRCS**

Specialist Registrar, Department of Trauma & Orthopaedics, Addenbrooke's Hospital

**Sazia Samad, BSc MRCS**

Trauma Fellow, Department of Trauma & Orthopaedics, Addenbrooke's Hospital