

Delayed Hypoxic Leukoencephalopathy In A Substance Abuse Patient: A Case Report

D Nigro, C Bergesio

Citation

D Nigro, C Bergesio. *Delayed Hypoxic Leukoencephalopathy In A Substance Abuse Patient: A Case Report*. The Internet Journal of Psychiatry. 2009 Volume 1 Number 1.

Abstract

Objective: A 33-year-old man, after substances overdose developed acute respiratory failure. Consequences of this are delirium and bilateral hypoxic damage to globus pallidus in MRI. Forty days after remission, his mental status worsened quickly. Patient showed grossly disorganized thinking and behaviour, severe memory impairment. Neurological examination revealed diffuse hypertonia and brisk deep tendon reflex. MRI showed bilateral diffuse demyelination of frontal, parietal, temporal and peritrigonal white matter. Pharmacotherapy with neuroleptics was ineffective. The syndrome lasted one month and ended quickly. Attenuating disorganized thought and behaviour, cognitive core of syndrome progressively shifted to loss of initiative, lassitude and indifference. Despite the complete cognitive recovery with normalization of cognitive tests, emotional response remained stiff with perseveration, tendency to indifference and stereotypical trend of happiness. This is the second case in literature in which after globus pallidus lesion, craving disappears and patient become temporary abstinent. **Conclusions:** Delayed hypoxic leukoencephalopathy is a syndrome to consider when delayed onset of neuropsychiatric symptoms follows a hypoxic event. MRI allows a clear diagnosis. Psychotropic medication should be minimized, avoiding antipsychotic because of increased risk of extrapyramidal side effects and unpredictability of clinical results.

INTRODUCTION

Delayed hypoxic leukoencephalopathy (DHL), is a rare and serious complication of cerebral hypoxia. Recovery from acute hypoxia is followed by an asymptomatic interval that can last up to 40 days. Subsequently appear movement and cognitive disorders. Movement disorders can include parkinsonism, various forms of dystonia and myoclonic clinical syndromes, gait disturbances, tic and hyperreflexia. Cognitive disorders are disorientation in time and space, disorganized thinking, impaired attention and memory, lack of initiative. [1,2,3,4] In the past carbon monoxide poisoning was a common cause of hypoxia, linked to the use of coal or carbon monoxide as fuel for heating and cooking systems. Today are common causes, overdose of opioids or benzodiazepines and heart or lungs failure. [3, 4, 5,] The pathologic substrate of delayed hypoxic encephalopathy is thought to be the selective demyelination of white matter. [1, 2, 6,] The incidence of the syndrome is very low, only 2.75% of those who suffered from acute cerebral hypoxia are liable to develop delayed hypoxic encephalopathy. This lead to postulate an individual vulnerability or an unknown pathological mechanism, probably abnormalities or deficiency of some enzymes involved in myelin synthesis .[7] Magnetic resonance imaging shows diffuse bilateral

symmetric confluent demyelination reaching sub cortical u –fibers and posterior fossa. [2]

Literature isn't uniform about the prognosis and overall tends to describe a serious disease with a complicated outcome. Most patients have lasting cognitive deficits commonly in frontal executive functions, such as attention, thinking flexibility, working memory and emotional control or other neurological signs. [6, 8] The tie between demyelination and hypoxia is partially explained and some hypotheses have been made. Cerebral white matter is supplied mainly by few widely spaced arterioles explaining why it's less able to compensate for hypoxic state, even if not necessarily that deep. [9, 10] Substances that cause hypoxia may exert a direct myelinotoxic action through disruption of ATP-dependent enzyme pathways responsible for myelin turnover. Here delayed demyelination represents a failure of synthesis. [6, 11] Hypoxic depletion of ATP causes glutamate release into extracellular space. Sustained activation of glutamate receptors, triggers excitotoxic damage of myelin and death of oligodendrocytes. [12, 13] Hypoxia activates microglia / macrophages which can cause, within two weeks a complete disappearance of both myelin and oligodendrocytes. [14] Hypoxia triggers apoptotic

process primarily affecting oligodendrocytes. Recovery depends on individual differences regarding neural plasticity. [15] The clinical consequences would be delayed due to the long half-life of myelin (2.5–7 days) as the necrosis of the myelin sheaths is known to follow the cell necrosis by 10–14 days [2, 16] or due to the time needed to accumulate oligodendrocyte's damage to become significant enough for symptoms to appear.[17]

CASE REPORT

A 33 year old Italian male found in a coma after taking a mix of heroin, cocaine, alcohol, benzodiazepines and methadone. SpO₂ was 50% with five respiratory acts/min. Thoracic computerized tomography (CT) showed pulmonary edema. Brain computerized tomography (CT) was normal. Intubated and mechanically ventilated for two days, he remained in intensive care unit (ICU) still six days to treat pneumonia, secondary to pulmonary edema. Anamnesis was positive for habitual use of heroin and alcohol and discontinuous use of cocaine, methadone, marijuana and psychopharmacological medications like benzodiazepines, antidepressants and valproate. To avoid opioid withdrawal during ICU admission, replacement therapy with methadone hydrochloride 20 mg/day was initiated.

After extubation and stoppage of sedating agents, patient was transferred to our psychiatric with the initial diagnosis of delirium. He appeared alert but partially temporo-spatial disoriented, aggressive, oppositional to treatment, and he wasn't aware of illness,.

We maintained methadone treatment adding clonidine intramuscular (100mg/day) **. After two days, patient became less aggressive and oppositional, allowing the switch to oral olanzapine (15mg/day). On day 10 patient was fully recovered, regained awareness of the need to treat his substance dependence as well as his psychological problems.

In anticipation of the transfer to a structure for addiction treatment, to assess any possible after effect of hypoxic episode, we performed an Electroencephalogram (EEG) revealing normal trace and a new brain MRI. showing bilateral hypoxic insult in globus pallidus.

Twenty-four days after the overdose, popped up crises with autonomic signs. The first lasted about thirty minutes with diarrhea, vomiting, hypertonia, tremors of right arm, cephalalgia and unexplained sense of anxiety. Two days later, a new episode with added tachycardia, fever 38°C and

increased blood pressure. A third episode with trismus happened three days later. Meanwhile, patient's mental state deteriorated rapidly and within 48 hours, patient showed grossly disorganized speech and behavior, time and space disorientation, inversion of sleep patterns. Neurological examination showed dysarthria, diffuse hypertonia and heightened deep tendon reflex.

He lost long and short term memory and couldn't remember correct biographical information. He couldn't no longer recognize and correctly use objects and rooms. Sometimes he explored orally and manipulated objects aimlessly. He became incontinent needing diapers, lost the ability to use cutlery and need help during meal intake. In two occasions he filled his mouth without swallowing up to the point of suffocation. Meals were restricted to semi-liquid diet. MRI performed at that time confirmed globus pallidus damage and showed that demyelination was extended bilaterally including frontal, parietal, and temporal and peritrigonal white matter and external capsule reaching the subcortical U-fibers. These findings are in agreement with Shprecher marker for DHL. [2]

Figure 1

Fig. 1 MRI Globus pallidus bilateral hypoxic damage

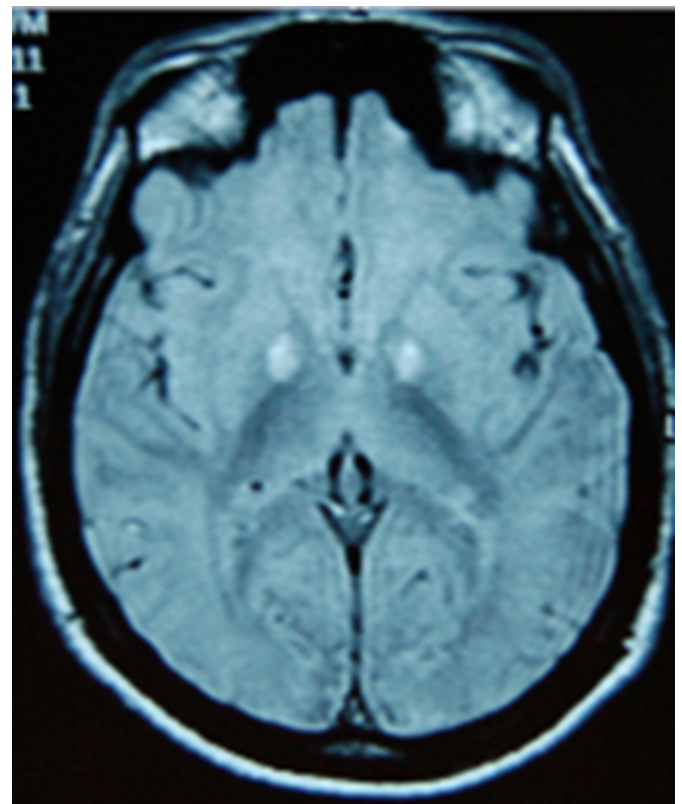
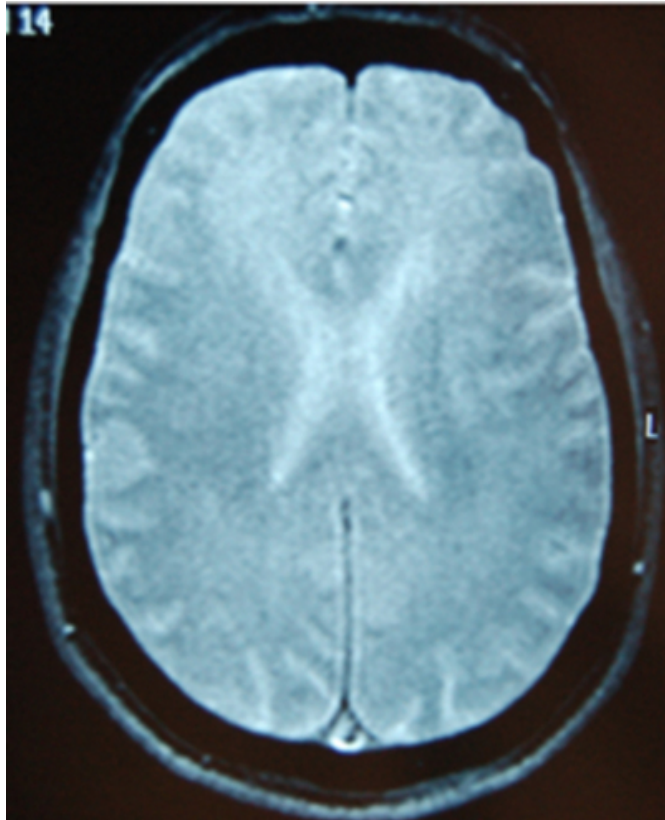


Figure 2

Fig. 2 MRI White matter hyperintensity



EEG showed diffuse continuous polymorphic delta-theta waves with no hemispheric prominence, reflecting diffuse cortical dysfunction. Since the condition was deteriorating we rather stopped neuroleptic therapy and switched to lorazepam I.M. (12mg/d). It was often necessary to use restraint to control nocturnal hyperactivity. Meanwhile we gave per os melatonin 5 mg die as hypnotic and antioxidant and omega 3 fatty acid (1gr die) [18,19,20, 21]. Within fifteen days the sleep wake rhythms began to normalize and the patient regained control of the sphincters. Neuropsychological evaluation *revealed transcortical motor aphasia, constructional apraxia, impaired selective attention, learning and abstract thinking. Severe verbal, graphic and thought perseveration interfered with every finalized task and utilization behavior. Perseverations and observed marked blunted affectivity and aboulia drove us to begin citalopram (10mg/d). Mini Mental State Exam (MMSE) scored 10.

Steady resolution of disorganized thinking and behavior gradually enabled him to complete daily care, supported also by the encouragement and guidance of nurses. Twenty days after he was transferred to neurorehabilitation unit and discharged one month later. After three months interval MRI

Brain was unchanged. Six months later, neuropsychological evaluation was repeated and showed complete remission of the deficit but EEG kept showing diffuse non epileptic encephalopathic pattern [1] Noticeable during DHL weren't symptoms of methadone withdrawal and after remission he lost craving and remained abstinent for two years. [8]

DISCUSSION

Biphasic course is typical of DHL. In our case after unspecific symptoms, the onset of full blown symptomatology happened 27 days from hypoxia with a lucid interval of 17 days.

The syndrome lasted about one month and ended quickly. A slow change anticipated the improvement of clinical situation.

Sporadic character of autonomic hyperactivity and the absence of perceptual distortions exclude delirium tremens, besides patient was taking methadone and benzodiazepines as replacement therapy. We can also exclude Wernicke's encephalopathy.

Classic Wernicke's triad includes oculomotor abnormalities, ataxia and impaired level of consciousness that can progress through stupor, coma and death. This clinical picture differs from our case for the absence of ataxia and oculomotor abnormalities and we witnessed a worsening of cognitive performances not of consciousness.

This is the second case in literature in which after globus pallidus lesion, craving disappears. [8] The ventral pallidum is a key site for drug seeking, taking, and relapse, the centre of "hedonic" liking and "motivational" wanting. Globus pallidus lesions, extending into the ventral pallidum, reduce motivational and hedonic impact of stimuli and ability to motivate behaviors towards positive stimuli. If this sometimes eliminates craving and pleasure from substances, usually reduces the ability to feel emotions and motivational drives, explaining the frequent abnormalities in motivation and affectivity [22, 23]

As noted by Hyang, neuropsychological tests were inconclusive. Despite stifled emotional response, indifference, stereotypical trend of happiness, tests were insensitive to such subtle findings.

After two years enduring behavior abnormalities have led to a serious loss of social capabilities. Probably abnormalities are patchy and tend to escape from the battery of neuropsychological tests normally used [24] Patient

remained abstinent for two years and the relapse of substance abuse motivational stimulus appeared to be fully replaced by peer pressure

This case emphasizes the importance of extending the follow-up of patients who have had episodes of cerebral hypoxia also mild and with good recovery and the role of MRI as main diagnostic tool.

Real therapeutic option remain antioxidant agents , vitamin e, acetylcysteine and melatonin.(25)

Antipsychotic should be minimized, because the augmented risk of extrapyramidal effect [1] and the loss of predictability of clinical effects.

*List of neuropsychological tests: Weigl's test; Stroop's test; Street's Completion test; Rey-Osterrieth Complex Figure Test (ROCF); Gainotti's language examination; Borkowsky,Spinnler,Tognoni Verbal Fluency Test; Novelli's prose memory test.

**Clotiapine

Clotiapine is an antipsychotic agent with a tricyclic structure of the dibenzothiapine type; its general properties are similar to those of phenothiazines. It has a high affinity for D2 and 5-HT2 receptors; Marketed in Argentina, Belgium, Israel, Italy, Luxemburg, South Africa, Spain, Switzerland and Taiwan is used in clinical practice for its sedative properties. [26]

References

1. Lee H B, Lyketsos CG, Delayed Post-Hypoxic Leukoencephalopathy Psychosomatics 2001 42: 530-533
2. Shprecher D R, Flanigan K M, Gordon Smith A, Smith Shawn M., Schenkenberg T, Steffens J. Clinical and Diagnostic Features of Delayed Hypoxic Leukoencephalopathy. The Journal of Neuropsychiatry and Clinical Neurosciences 2008;20:473-477.
3. Ernst A, Zibrak JD. Carbon monoxide poisoning. New England Journal of Medicine 1998;339:1603-1608
4. Wallace I.R,Dynan C., Esmonde T. One confused patient, many confused physicians: a case of delayed post-hypoxic leucoencephalopathy Quarterly Journal of Medicine 2010; 103:193-194
5. Kim J s, Lee SA., Kim JS Myoclonus, delayed sequelae of carbon monoxide poisoning, piracetam trial Yonsei Medical Journal 1987; 28: 231-233
6. Shprecher D, Mehta Lahar The Syndrome of Delayed Post-Hypoxic Leukoencephalopathy NeuroRehabilitation. 2010; 26(1): 65-72.
7. Choi S. Delayed Neurologic Sequelae in Carbon Monoxide Intoxication Archives of Neurology1983;40(7):433-435.
8. Miller J M, Vorel S R, Tranguch A J et al. Anhedonia After a Selective Bilateral Lesion of the Globus Pallidus American Journal of Psychiatry 2006;163: 786-788
9. Ginsberg M D,.Hedley-Whyte T, Richardson E P. Hypoxic-Ischemic Leukoencephalopathy in Man Archives of Neurology 1976;33:5-14.
10. Chalela J A, Wolf R L, Maldjian J A, Kasner S E. MRI identification of early white matter injury in anoxic-schemic encephalopathy Neurology 2001;56:481-485
11. Van der Knaap M S, Valk J. Delayed Posthypoxic Leukoencephalopathy, in Van der Knaap M S, Valk J Magnetic resonance of myelination and myelin disorders., 3rd edn. Berlin , Heidelberg, New York: Springer, 2005; 755- 758
12. Baltan S, Goldberg P M. AMPA/Kainate Receptor Activation Mediates Hypoxic Oligodendrocyte Death and Axonal Injury in Cerebral White Matter. The Journal of Neuroscience 2001; 21: 4237-4248
13. Jenkins B G, Brouillet E, Ching I Chen Y et al. Non-Invasive Neurochemical Analysis of Focal Excitotoxic Lesions in Models of Neurodegenerative Illness Using Spectroscopic Imaging. Journal of Cerebral Blood Flow & Metabolism 1996;16:450-61
14. Jamin N, Junier MP, Grannec G, Cadusseau J. Two temporal stages of oligodendroglial response to excitotoxic lesion in the gray matter of the adult rat brain.Experimental Neurology. 2001;172:17-28.
15. Kim HY,Kim B.J.,Moon SY, KwonJ.C et al. Serial diffusion-weighted MR Imaging in delayed postanoxic encephalopathy Journal of Neuroradiology 2002;29:211-5.
16. Chee PY, Dahl JL. Measurement of protein turnover in rat brain. Journal of Neurochemistry 1978; 30:1485-1493
17. Olivier P, Fontaine R H, Loron G, et al. Melatonin Promotes Oligodendroglial Maturation of Injured White Matter in Neonatal Rats. PlosOne 2009; Sep 22;4; e7128. <http://www.plosone.org/article/attachment.action?uri=info%3Adoi%2F10.1371%2Fjournal.pone.0007122&representation=PDF>
18. Kaur C, Sivakumar V, Liang EA. Melatonin protects periventricular white matter from damage due to hypoxia. Journal of Pineal Research 2010; 48:185-193.
19. Rosales-Corral S, Tan D, Reiter RJ et al Orally administered melatonin reduces oxidative stress and proinflammatory cytokines induced by amyloid-β peptide in rat brain: a comparative, in vivo study versus vitamin C Journal of Pineal Research 2003 sept; (2):80-84
20. Wu A, Ying Z, Gomez-Pinilla F. Dietary omega-3 fatty acids normalize BDNF levels, reduce oxidative damage, and counteract learning disability after traumatic brain injury in rats. J Neurotrauma.2004 Oct;21(10):1457-67.
21. Smith K, Tindell AJ, Aldridge J.W, Berridge K.C Ventral pallidum roles in reward and motivation Behavioural Brain Research Volume 196, Issue 2, 23 January 2009, Pages 155-167
22. Smith K, Berridge KC The Ventral Pallidum and Hedonic Reward: Neurochemical

Maps of Sucrose "Liking" and Food Intake
The Journal of Neuroscience, September 21, 2005,
25(38):8637-8649
23. Hyang JJ, Kwon JC., Chin J, Yoon SJ, Na DL.
Globus Pallidus Lesions Associated with High Mountain
Climbing
Journal of Korean Medical Science 2002; 17: 861-3
24. Kekec Z, Seydaoglu G, Sever H, Ozturk F.

The effect of antioxidants (N-acetylcysteine and melatonin)
on hypoxia due to carbonmonoxide poisoning.
Bratisl Lek Listy. 2010;111(4):189-93.
25. Berk M, Rathbone J, Mandriota-Carpenter SL.
Clotiapine for acute psychotic illnesses.
Cochrane Database of Systematic Reviews 2004;
4:CD002304

Author Information

Dott. Gabriele Nigro

Department of Psychiatry, SDPC-Ospedale

Chiara Bergesio

Department of Psychiatry A.S.L. TO 4 Piemonte –SPDC Ivrea