

# Benign Papillary Mesothelioma of the Tunica Vaginalis Testis

A Loganathan, N New, R Calleja

## Citation

A Loganathan, N New, R Calleja. *Benign Papillary Mesothelioma of the Tunica Vaginalis Testis*. The Internet Journal of Urology. 2003 Volume 2 Number 1.

## Abstract

We report on a case of benign papillary mesothelioma of the tunica vaginalis testis in a 33-year-old man presenting with a left sided hydrocoele. An abnormal calcified area was excised and histology revealed a papillary mesothelioma. The patient was free from recurrence or other symptoms at follow up.

## INTRODUCTION

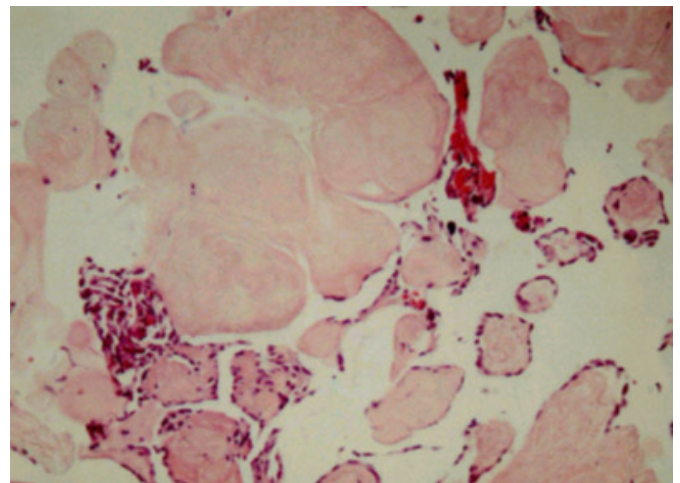
Benign mesothelial neoplasms of the paratesticular region are rare. The commonest histologic pattern is the adenomatoid pattern although rare reports of cystic mesothelioma have been described. We report on another variant; papillary mesothelioma which is very rarely described at this site.

## CASE REPORT

A 33-year-old man presented with a left sided scrotal swelling. Clinical examination demonstrated the presence of a hydrocoele and the patient was operated on for this. At operation he was noted to have an abnormal looking area with some calcification at the upper pole of the left testicle which was excised. Histology revealed a small papillary lesion projecting from the surface of the testis, which appeared to be in continuity with the mesothelium overlying the testis. There was no evidence of cytological atypia. The underlying testis showed no evidence of malignancy. Appearances were consistent with benign papillary mesothelioma. At follow up the wound had healed well and there were no other symptoms or evidence of recurrence.

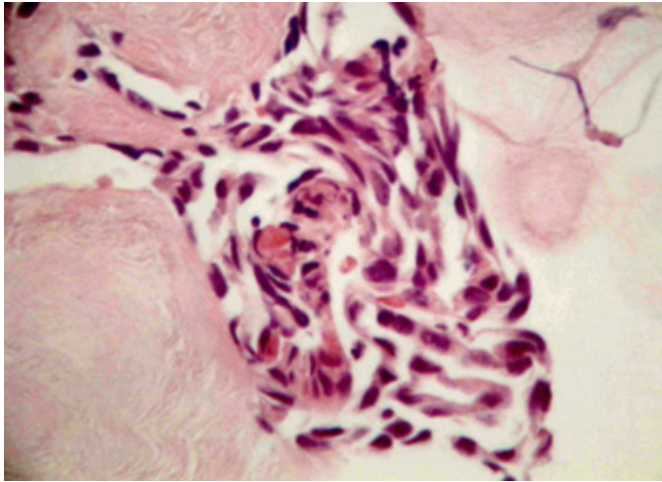
## Figure 1

Figure1 : Hyalinised connective tissue papillae covered by proliferated mesothelial cells. (Original magnification 100X)



**Figure 2**

Figure 2: The mesothelial cells are cytologically benign. (Original magnification 400X)



**DISCUSSION**

Benign mesothelioma of the tunica vaginalis can present as several variants. Adenomatoid tumours are the most common and are well circumscribed, firm solid nodules ranging from 0.4 to 5 cm in diameter. Most appear to occur at the head of the epididymis (1). A case of benign cystic mesothelioma has been reported in the tunica vaginalis (2). This presented as a hydrocoele and on exploration a large multicystic structure was demonstrated. Benign papillary mesothelioma is another rare variant. In our case report we

describe this variant presenting as a coincidental finding within a hydrocoele. Xiao et al reported on a similar case again presenting with a hydrocoele(3). Subsequent surgery revealed a polypoid mass in the epididymis which was resected. Histological examination revealed a well differentiated papillary mesothelioma. The patient remained well and free of recurrence 3 years later.

**CONCLUSION**

The aetiology and behaviour of these tumours remains poorly characterised. It is important that surgeons examine and biopsy unexpected and abnormal testicular lesions during surgery.

**CORRESPONDENCE TO**

Dr A.Loganathan Flat 2 the Firs, Queen Elizabeth Hospital  
Gayton Road Kings Lynn PE30 4ET United Kingdom Tel  
00 44 07951537629 Email:  
arun@logathan100.freemove.co.uk

**References**

1. Perez-Ordóñez B, Srigley J. Mesothelial lesions of the paratesticular region, *Seminars in Diagnostic Pathology* 2000; 17 294-306
2. Lane T, Schofield W, Trotter G. Benign cystic mesothelioma of the tunica vaginalis, *BJU International* 1999; 84 533-534
3. Xiao S, Rizzo P, Carbone M Benign papillary mesothelioma of the tunica vaginalis testis. *Arch Pathol Lab Med* 2000; 124 143-147

**Author Information**

**A. Loganathan, MBChB**

Department of Urology, Queen Elizabeth Hospital

**N.E. New, FRCPath**

Department of Pathology, Queen Elizabeth Hospital

**R.K. Calleja, FRCS (Urol)**

Department of Urology, Queen Elizabeth Hospital