

Syringing And Probing Under Local Anesthesia In Infants

V Sharma, S Vaidya, S Shrivastava

Citation

V Sharma, S Vaidya, S Shrivastava. *Syringing And Probing Under Local Anesthesia In Infants*. The Internet Journal of Ophthalmology and Visual Science. 2004 Volume 3 Number 2.

Abstract

Aim: This study was undertaken to evaluate the results of probing from lower punctum under local anesthesia in 6 \pm 1 months old infants.

Material and Method: 376 infants between 5 to 7 months of age with complaint of epiphora, with or without regurgitation on pressure over the lacrimal sac were included in the study. Syringing and probing was performed under topical anesthesia in all the cases. The infants were sedated by giving Triclofos sodium 500 mg per-orally and were immobilized by the technique of mummification. Syringing and if required probing was repeated, at weekly interval for two weeks.

Results: Success of probing was defined as complete remission of symptoms and negative regurgitation test. Patency of lacrimal passage was confirmed by syringing. Patients cured after first probing 77.4% (291 cases), while 19.7%(74) showed improvement after second sitting. Lastly, after the third sitting 31 patients (8.3%) got cured. (Total 97.1%) The number of patients who could not be cured was 11 (2.9%)

Discussion: Though there are only a few advocates of early probing as office procedure under local anesthesia, we have found that early probing can be done without general anesthesia, as it is easier to restrain the infant. This not only avoids the morbidity, hospital stay and hazards of general anesthesia, but also at the same time reduces the total cost of treatment. The procedure can be easily repeated. Though probing is advocated from upper punctum, in our study probing was done from lower punctum and no damage was found to the punctum or canaliculi even in a single case; on the contrary it is easier to perform from lower punctum.

Conclusion: Results are convincing to do early syringing and probing at the age of 6 months of age rather than waiting for spontaneous resolution. It is easier to do without hazards of general anesthesia and less apprehension to parents. At the same time repetition of procedure is not cumbersome to treating surgeon as it can be done as office procedure.

INTRODUCTION

The process of re-canalization of nasolacrimal duct (NLD) is complete in most of the cases at birth¹. It has however been reported that 20-30% of the newborn have obstruction of NLD^{2, 3,4}. Out of these affected infants 80-90% get spontaneous resolution between 2 months to 1 year of age^{5, 6}, but in 2-4% of these infants the obstruction of NLD persists, at the distal end even after 2 years of age^{7, 8}.

The timing of surgical interference by syringing and / or probing for congenital NLD obstruction has been a matter of controversy^{1,3,5}. Common consensus on the time and method of intervention has not evolved due to increased failure rates in these patients⁵. Also there are different views regarding

the timing of pediatric dacryocystorhinostomy (DCR). It is advocated that probing in congenital NLD obstruction should be done under general anesthesia and also that the preferred site is from upper punctum¹². The aim of this paper is to study the results of probing in 6 \pm 1 months old infants under local anesthesia and from lower punctum.

MATERIAL & METHOD

A retrospective study has been done of 376 consecutive patients, which had undergone probing for congenital nasolacrimal duct obstruction during the 1990 – 2004 attended eye clinic of the R.D.Gardi Medical College and Ujjain Charitable Hospital. The diagnosis of congenital nasolacrimal duct obstruction was based on the history of

watering from eye since birth or during first few weeks of life, with or without discharge and clinical examination as regurgitation from sac with or without obvious swelling in lacrimal region.

Along with the above criteria initial clinical examination included assessing anomalies of lid or face, site of lacrimal punctum, ruling out causes of lacrimation e.g. infectitious and allergic conjunctivitis, ophthalmia neonatarum, keratitis, buphthalmos etc.

Strict criteria for selection of cases observed. Infants should not be less than 5 ½ months in age as below this age spontaneous resolution is possible^{2,3}, whenever they presented before 5 month of age, medical management consisting of topical antibiotic and lacrimal massage was advocated. Infants of more than 7 months of age were excluded, as it is difficult to immobilize them by the method of mummification. Patients who had active infection showing purulent discharge were given systemic and topical broad-spectrum antibiotics along with non steroid anti-inflammatory drugs in syrup form, to control infection prior to do syringing and probing. Only clean cases were included in the study.

After taking consent from parents, three sittings of weekly interval were programmed. The procedure of syringing and probing was performed under local anesthesia in all cases. Nil by mouth was not required. One TSF Pedichloryl syrup – Triclofos sodium 500 mg. was given by mouth, 45 minutes prior and topical anesthesia - Xylocaine 2% with adrenaline 1:100000 was instilled in the conjunctival sac every 5 minutes for half an hour, particularly over the lower punctum. Adrenaline causes blanching of mucosa of passage so there are less chances of traumatic bleeding. A sterile cloth on O.T. table was used for mummification of the infant.

Dilatation of punctum was done by Nettleship punctum dilator (figure 1). Syringing was done from lower punctum with 5c.c. Normal saline added with ½ c.c. Gentamycine 80mgs. / Ml. Bowman's probe of 1 or 2 size was introduced from lower punctum - first vertically then horizontally (figure 2.) till the hard stop at medial wall of lacrimal sac was felt, then it was further pushed downward, backward and laterally in the naso-lacrimal duct, gently and firmly till it got engaged in the bony canal (figure 3). After removing the probe, syringing was repeated with saline and Gentamycin to confirm the patency of the drainage system.

Figure 1

Figure 1: Dilatation of lower punctum by nettle ship pnuclum dilator

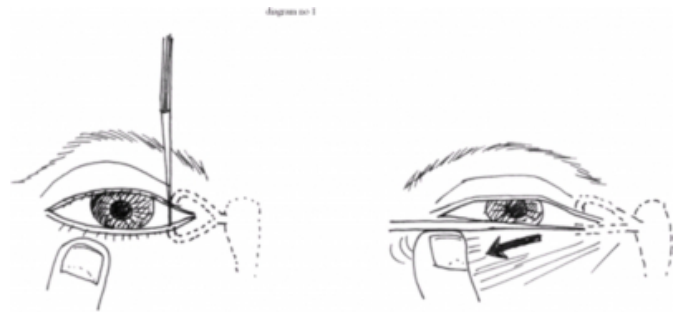

Figure 2

Figure 2: probing from lower punctum

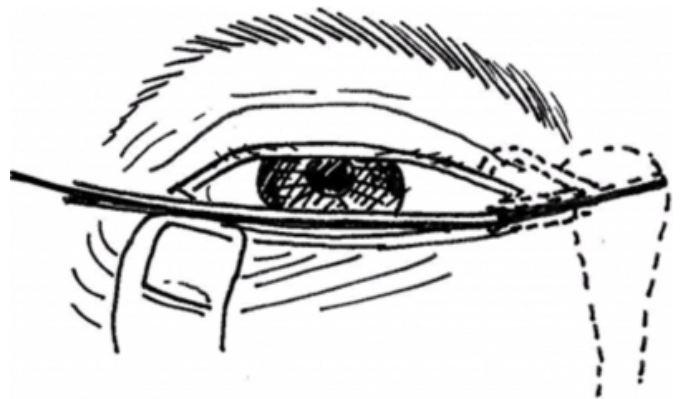
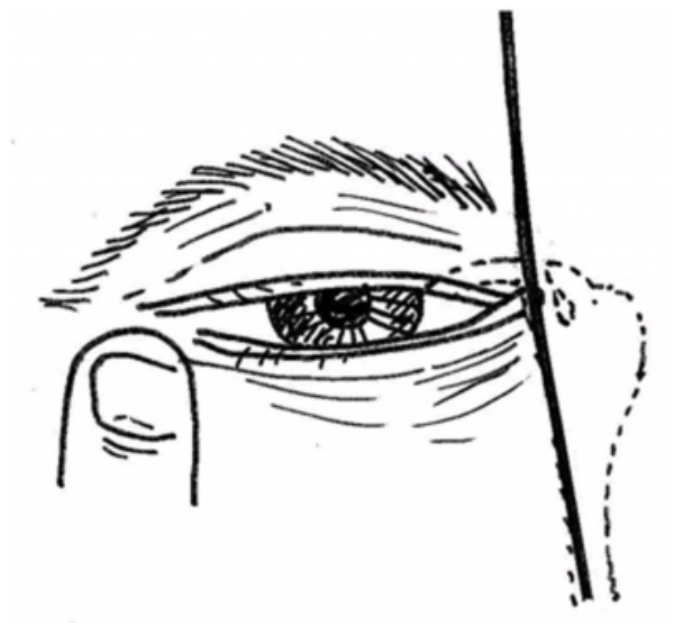

Figure 3

Figure 3: probing from lower punctum



The patient was sent home soon after the procedure with

systemic and topical antibiotics along with anti-inflammatory drugs, without any restriction of feedings to the child.

The patient was called up for review after a week for syringing; and if required probing was done. Same procedure was repeated in the next follow up visit after another one week. Then the patient was asked to come after three weeks for follow up. 83% cases presented for follow up.

RESULTS

Table 1 gives the group wise distribution of patients and the results of probing. There are three age ranges: 5 ½ to 6 months, 6 to 6 ½ months & 6 ½ to 7 months. Sex wise distribution has also been given. We have not taken into consideration the number of eyes but instead we have considered number of patients while finding the results.

Figure 4

Table 1: Group wise distribution of patients and results of probing.

Age Range	5 ½ - 6 months			6-6 ½ months			6 ½ - 7 months			Total	%
Sex	Male	Female	Total	Male	Female	Total	Male	Female	Total		
1 st Week	72	44	116	60	28	88	40	16	56	260	69.1%
2 nd Week	19	13	32	15	07	22	13	07	20	74	19.7%
3 rd Week	05	05	10	05	05	10	07	04	11	31	8.3%
Total	96	62	158	80	40	120	60	27	87	365	97.1%
Failure cases	04	03	07	02	-	02	01	01	02	11	2.9%
Grand Total	100	65	165	82	40	122	61	28	89	376	100%

It is clear from the table that after first sitting i.e. probing and syringing 260 patients (69.1%) got cured, while after second sitting 74 patients (19.7%) got cured while after third sitting 31 patients (8.3%) got cured. The number of patients who could not be cured was 11 (2.9%)

Only 10(2.6%) patients had complications. 6(1.6%) patients developed subcutaneous oedema probably because of formation of false passage by the surgery during the procedure. This was seen in those patients, which were not improved. 4(1.1%) cases had nasal bleeding, which continued for two days.

DISCUSSION

At 6 weeks of gestational age lacrimal drainage system begins forming as depression, termed as lacrimal groove. A solid cord of epithelium buried as the mesoderm develops

and extends from the eyelids to the nose. Canalization of cord begins at approximately 3.5 months of gestational age and is usually completed at or near the time of birth; with the lower level of the system being the last to open. Anomalies may occur anywhere along the course of the system^{7, 8}. Atresia of the NLD is the most common cause of epiphora in infants. The most common site of obstruction is at the mucosal entrance into the nose (valve of Hasner) under the inferior turbinate⁸.

Probing has been a time proven treatment for congenital nasolacrimal duct obstruction. Traditional option includes observation and medical management, then probing under G.A from upper punctum at the age of 1 year or office probing with topical anesthesia at the age of 4-6 months.

Present study shows encouraging results of early probing (5 ½ - 7 months) under topical anesthesia, from lower punctum. Cure rate was 97.1%. There are only a few advocates of early probing as office procedure under local anesthesia, in literature⁹.

Early surgical intervention avoids months of morbidity due to epiphora and chronic dacryocystitis. It is also suggested that postponement of procedure may result in decreased success with simple probing because of chronic inflammation and secondary fibrosis¹⁰. Early probing can be done without general anesthesia, as it is easier to restrain the infant. This avoids hazards of general anesthesia and avoids patient's stay in the hospital. It also decreases the cost of the treatment. It is also found that parents try to avoid procedures under general anesthesia and do not turn up when they are advised for such procedure due to their apprehension for general anesthesia. Also general anesthesia cannot be repeated at short intervals and hence repeating of syringing and probing becomes difficult. The parents have very little apprehension about local anesthesia and they agree for even repeated sittings.

The number of patients who could not be cured even after three sittings were only 11 i.e. 2.9%. Out of these 4(1.1%) cases had telecanthus, 4(1.1%) cases showed anomaly of bony canal in C.T. and in three Infants causes were obscure.

Majority of studies advocates probing from upper punctum^{11, 12}, as they want to preserve the lower punctum, which is major pathway of drainage. In our study probing was done from lower punctum in all the cases. No damage was found to the punctum or canaliculi. It was easier to do probing from lower than the upper punctum

CONCLUSION

To do syringing and probing in cases of congenital nasolacrimal duct obstruction at the age of 6 months, under local anesthesia is advantageous as results are satisfactory. It is cost effective with less apprehensive to parents, avoid hospital stay and hazards of general anesthesia. It is easier to do by lower punctum with fewer complications, at same time it can be repeated as office procedure.

References

1. James DH, Mac Ewen CJ. Managing congenital nasolacrimal duct obstruction in general practice. *British Medical Journal* 1997; 315: 293-96.
2. Arruga H. Ocular surgery. Translated from Spanish edition. Michael K. Hogan, Lewis Chaparro. McGraw Hill, New York 1962. P 945.
3. Stallard, Stallard's eye surgery - KM Verges Co. Bombay 1980 P. 272.
4. Pollack K., Sommer E. Analysis of congenital dacryostenosis in consideration of mucocoeles. *Jahrestagung der DOG*, 2002; 10:10-12.
5. Robb RM. Success rates of nasolacrimal duct probing at time intervals after 1 year of age. *Ophthalmology* 1998 Jul 105(7) 1307 - 9.
6. CJ MacEwen, JDH young, CW Barras, B Ram, PS White. Value of nasal endoscopy and probing in the diagnosis and management of children with congenital epiphora. *Br. J Ophthalmol* 2000; 85: 314-318.
7. Piest KL, Katowitz JA. Treatment of congenital nasolacrimal duct obstruction. *Ophthalmology clinics of North America* 1991; 4: 201-9.
8. Kerstein RC. Congenital lacrimal abnormalities In: *Principles and practice of ophthalmic plastic and Reconstructive surgery*. WB Saunders Company; 1996. Vol 2, P 731 - 747.
9. Bhinder GS, Bhinder HS. The art of probing in management of congenital naso lacrimal duct obstruction. *DOS Times* 2004; 10: 21-23.
10. Stager D, Baker JD, Frey T, Weakly DR Jr, Birch EE. Office probing for congenital nasolacrimal duct obstruction. *Ophthalmic surgery* 1992; 23; 482-84.
11. Yadav U, Bhatia A, Arora V. Congenital Dacryocystitis; How far have we come? 2004; 10:39 - 42.
12. Jack J. Kanski. *Clinical Ophthalmology* 5th Edition. P - 65.

Author Information

Virendra Kumar Sharma, M.S.

Associate Professor, Department of Ophthalmology, R.D.Gardi Medical College, Ujjain Charitable Trust Hospital
Budhwariya

Sudhakar Vaidya, D.L.O. D.N.B.

Associate Professor, Department of Ophthalmology, R.D.Gardi Medical College, Ujjain Charitable Trust Hospital
Budhwariya

Saurabh Shrivastava, M.S.

Senior Resident, Department of Ophthalmology, R.D.Gardi Medical College, Ujjain Charitable Trust Hospital Budhwariya