

Alzheimer's disease presenting with Sudden Onset Multiple Intracranial Bleeds

S Narsupalli, L Vaidyanathan

Citation

S Narsupalli, L Vaidyanathan. *Alzheimer's disease presenting with Sudden Onset Multiple Intracranial Bleeds*. The Internet Journal of Internal Medicine. 2008 Volume 8 Number 1.

Abstract

An 89 year old woman with a past history of dementia and hypertension, presented with sudden onset dysphasia. An initial computed tomography (CT) head showed two synchronous acute intracerebral hematomas, one in the left parieto-occipital region and the other in right frontal region. Subsequent magnetic resonance imaging (MRI) done a week later, showed multiple intracranial bleeds that had increased in number since the CT. There was no evidence of malignancy. She was managed conservatively

CASE REPORT

An 89 year old woman with a past history of dementia and hypertension, presented with sudden onset dysphasia. An initial computed tomography (CT) head showed two synchronous acute intracerebral hematomas, one in the left parieto-occipital region and the other in right frontal region (Figure 1). Subsequent magnetic resonance imaging (MRI) done a week later, showed multiple intracranial bleeds that had increased in number since the CT (Figure 2). There was no evidence of malignancy. She was managed conservatively and discharged from the hospital. Two weeks following discharge, she presented with collapse and weakness in the right upper limb. The CT scan at this time showed an acute hematoma within the right parietal region, which was not seen in the previous scan (Figure 3).

Figure 1

Figure 1: Initial CT done on first presentation

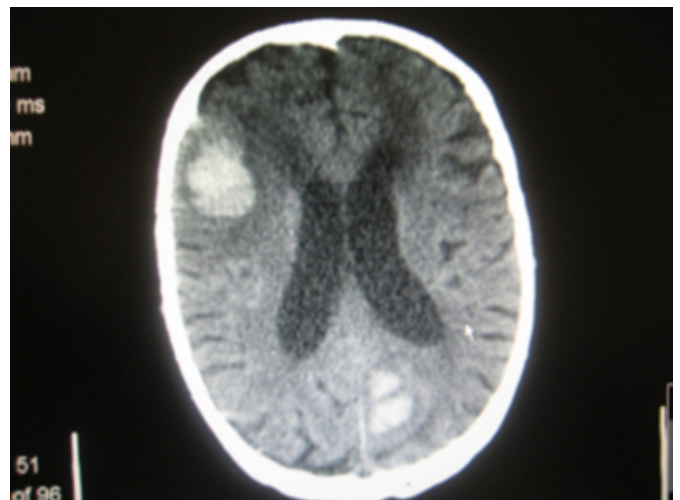


Figure 2

Figure 2: MRI done a week following initial CT

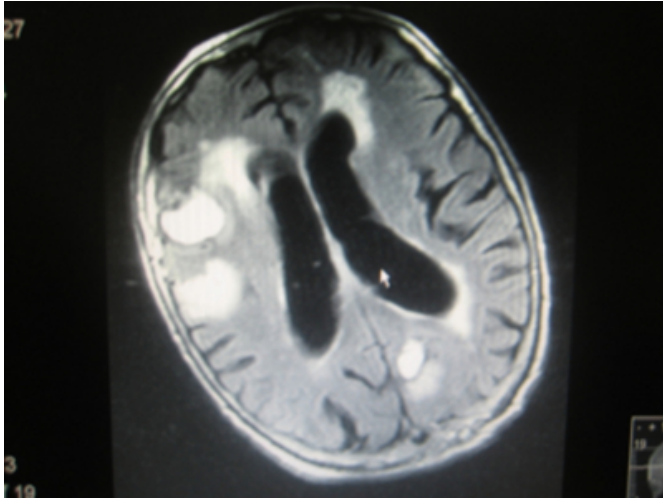
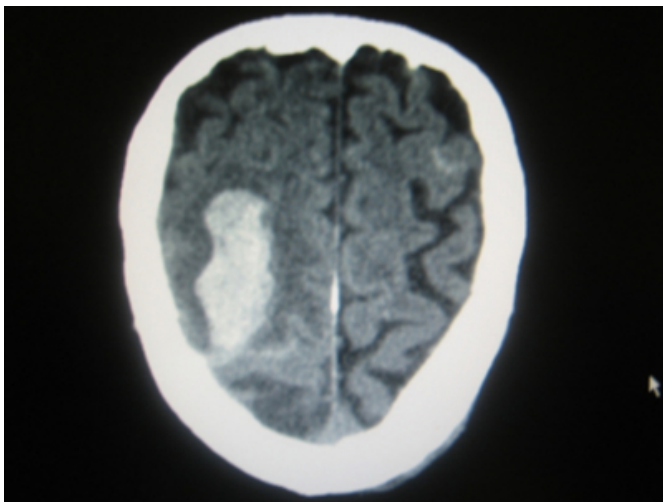


Figure 3

Figure 3: CT on second presentation



DIAGNOSIS

Multiple Intracranial Bleed following Cerebral Amyloid Angiopathy.

Our patient was managed conservatively and unfortunately died within a few days of her second presentation.

Though hypertension is one of the major culprits of primary intracerebral hemorrhage (ICH), pathological processes like Cerebral Amyloid Angiopathy (CAA) can present as ICH in elderly patients. CAA is one of the morphologic hallmarks of Alzheimer's disease.¹ Pathology includes deposition of β amyloid that damages the cortical and leptomeningeal vessels, leading to fibrinoid necrosis and microaneurysm formation thus progressing to hemorrhage. Impaired elimination and accumulation of β amyloid peptide may explain the link between CAA and Alzheimer's disease. Data from population-based studies give annual incidence rates for symptomatic lobar hemorrhage in patients over age 70 years of 30 to 40 per 100,000.²

Diagnosis can be based on clinical presentation and gradient-echo MRI findings.³ Histological examination is required for definitive diagnosis. The presence of CAA should be suspected clinically in patients over the age of 60 who have multiple lobar hemorrhages in the absence of an obvious cause.² Acute CAA related hemorrhage is treated symptomatically. Short term empiric use of anticonvulsants is administered if the patient is at risk for aspiration or other medical complications. Large hematomas are surgically resected. Inflammatory forms of CAA may be responsive to immunosuppressive therapy with corticosteroids or cyclophosphamide.⁴

References

1. K.A. Jellinger, Alzheimer disease and cerebrovascular pathology: an update, *J Neural Transm* 2002;109:813–836.
2. Greenberg SM. Cerebral amyloid angiopathy: prospects for clinical diagnosis and treatment. *Neurology* 1998;51(3):690-4.
3. Greenberg SM, Finklestein SP, Schaefer PW. Petechial hemorrhages accompanying lobar hemorrhages: detection by gradient-echo MRI. *Neurology* 1996;46:1751-1754.
4. Eng, JA, Frosch, MP, Choi, K, et al. Clinical manifestations of cerebral amyloid angiopathy-related inflammation. *Ann Neurol* 2004;55:250.

Author Information

S. Narsupalli, MBBS

Department of Acute Stroke Care, Mayday University Hospital, Croydon, Surrey, UK

L. Vaidyanathan, MBBS

Department of Emergency Medicine, Mayo Clinic, Rochester, Minnesota