

Giant Complicated Hydatid Cyst Of The Liver And Occult Duodenal Adenocarcinoma: A Case Report

G Guercio, C Ricotta, G Diana

Citation

G Guercio, C Ricotta, G Diana. *Giant Complicated Hydatid Cyst Of The Liver And Occult Duodenal Adenocarcinoma: A Case Report*. The Internet Journal of Surgery. 2006 Volume 10 Number 1.

Abstract

We present an original article about an interesting and challenging case: a patient with abdominal discomfort, dyspepsia due to a giant hydatid cyst of the liver causing obstruction of upper digestive canal, reduction of hepatic function, hepatomegaly and hiding an occult duodenal adenocarcinoma marked by a very fast evolution.

INTRODUCTION

Hydatid disease caused by infection with *Echinococcus granulosus* tapeworm or *E. multilocularis* is endemic in the Mediterranean basin, Central Asia, Africa and South America. However, as a result of increased migration and immigration, hydatidosis is becoming a worldwide health problem.^{1,2}

The key for a successful management is early detection by medical imaging and early intervention. However, treatment of liver hydatid disease is still a debated matter.

According to WHO Guidelines, chemotherapy with albendazol is the treatment of choice when surgery or PAIR (puncture- aspiration- instillation- re-aspiration) are not feasible or technically available.

Operative therapies are represented by minimally invasive (PAIR) and open or laparoscopic surgical procedures. Anyway, surgery is the cornerstone for radical treatment of hydatid liver disease.^{2,3,4}

The target of therapy is to treat local disease, its associated complications and to avoid disease recurrence.

It is also important to underline that all the operative procedures should be carefully chosen since hepatic hydatidosis is considered a benign disease.

The aim of this paper is to present a challenging and interesting case report of a patient with a giant hydatid cyst of the liver causing obstruction of the upper digestive canal, reduction of hepatic function, hepatomegaly and hiding an occult duodenal adenocarcinoma.

CASE REPORT

A 62-year-old man was referred to our unit for dyspepsia, abdominal tension and upper intestinal obstruction.

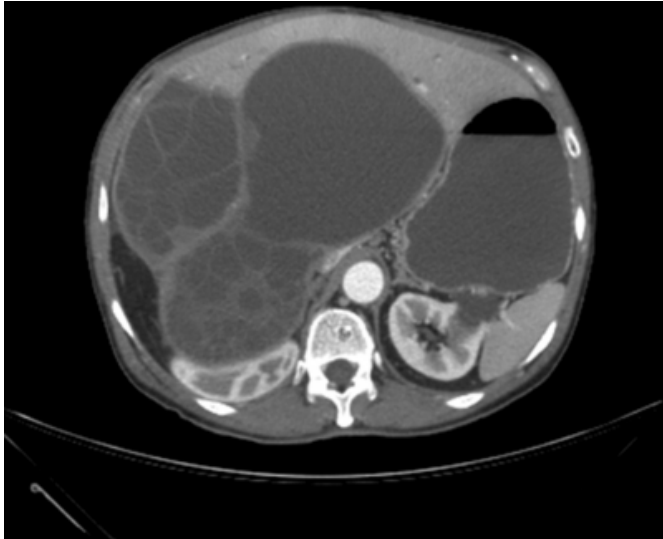
Some days before, he experienced nausea, vomiting and abdominal discomfort. At the time of admission the patient was in bad general condition.

Physical examination showed a giant palpable mass extending from the upper abdomen to 3 cm below the umbilicus.

Ultrasound and CT scan showed three 20 cm lesions occupying the major part of the liver parenchyma (figure 1). The cysts were detached and compressed the liver, the hepatic veins, the intra-hepatic vena cava, the second part of the duodenum and the right kidney. There was not any finding of duodenal obstruction or pancreatic head neoplasm. The biliary tree was dilated (choledochus 2 cm). We considered this bile-ducts dilatation as the consequence of external compression from the cysts. There was also a severe gastrectasia.

Figure 1

Figure 1: CT scan showing three 20 cm lesions occupying the majority of the liver parenchyma. Two cysts were detached and compressed the liver, the hepatic veins, the intra-hepatic vena cava, the second part of the duodenum and the right kidney. The biliary tree was dilated (choledochus 2 cm). There was also a severe gastrectasia.



One day after admission, the patient was started on albendazole 400 mg twice daily.

Six days after admission, we started parenteral nutrition (P.N.), because of the patient's nutritional condition.

Two weeks after admission, we operated the patient. We tried to remove the whole cyst, but a part of the cystic wall was tightly attached to the liver. Considering the hepatic function, we decided to do a partial pericystectomy and avoid a partial hepatic resection. During surgery, we did not find duodenal or pancreatic carcinoma. Soon after surgery the patient continued P.N. and started eating liquid food.

We leaved suction drains in and behind the liver. After few days the drains showed the presence of a high-flow biliary fistula_s.

A week after surgery the patient had another episode of vomiting, nausea and abdominal discomfort. The patient also started to have fever (39 °C). We considered different causes: a) viral infection; b) abdominal bacterial infection; c) peritonitis; d) another digestive obstruction. We started antibiotic therapy with ciprofloxacin 400mg and metronidazole 1g daily. We made blood exams that did not show any sign of infection. So we tried to evaluate the hypothesis of another obstruction. We made a duodenal dynamic radiography that showed an obstruction of the

second part of the duodenum. We also decided to do a gastroscopy that confirmed the duodenal obstruction and we made some biopsies.

The histological examination showed an adenocarcinoma of the duodenum, that we did not consider in our differential diagnosis since the first CT scan and the surgical exploration of the abdomen did not show any sign of duodenal obstruction or pancreatic head carcinoma.

Owing to the patient's condition and the duodenal obstruction we decided to operate him for the second time.

We planned two types of operation: pancreatoduodenectomy or palliative surgery.

During the operation we made a cytological examination of the ascitic liquid we found in the abdomen that showed the presence of atypical cells.

Considering the bad general condition of the patient and the results of pancreatoduodenectomy, we decided to do a palliative operation (gastro-enteric anastomosis and a cholecystojejunal anastomosis).

After this operation the patient started eating again and stopped parenteral nutrition.

After one month we evaluated the extension of the adenocarcinoma with a CT scan that showed a cancer involving the head of pancreas and the second part of the duodenum, metastases extended to the liver (S2,S4-S5) and to the hepatic, aortic and pancreatic lymphnodes. There was also a compression of the right kidney and the vena cava. Choledochus and Wirsung duct were dilated.

DISCUSSION

We present this case because, according to our knowledge, it is interesting and shows how it is possible to miss an important diagnosis.

We treated a benign disease (liver echinococcosis) that worsened the patient's quality of live. There were no clinical and radiological elements that could suggest a duodenal and pancreatic neoplasm.

The cancer showed to have a very quick diffusion. So we decided to do palliative surgery after considering the bad general condition of the patient and the survival after pancreatoduodenectomy.

We visited this patient again one month ago and he showed

all the clinical features of a patient with advanced cancer.

COMPETING INTERESTS

There are no competing interests and there is no conflict of interest.

AUTHORS' CONTRIBUTION

The authors contributed equally to this work

ACKNOWLEDGEMENTS

Written consent was obtained from the patient or their relative for publication of study

CORRESPONDENCE TO

Calogero Ricotta, Via Liborio Giuffrè n° 5, 90100 Palermo, Italy. Phone: +393391609919. Fax: +390916553795- 2713. E-mail: calogeroricotta@yahoo.com

References

1. Eckert J, Deplazes P: Biological, epidemiological and clinical aspects of echinococcosis, a zoonosis of increasing concern. Clin Microbiol Rev 2004; 17 (1): 107-35.
2. Alonso Casado O, Moreno Gonzalez E, Loinaz Seguro C, Gimeno Calvo A, Gonzalez Pinto I, Perez Saborido B, Paseiro Crespo G, Ortiz Johansson C: Results of 22 years of experience in radical surgical treatment of hepatic hydatid cysts. Hepatogastroenterology 2001; 48: 235-243.
3. Chautems R, Buhler L.H, Gold B, Giostra E, Poletti P, Chilcott M, Morel P, Menta G: Surgical management and long-term outcome of complicated liver hydatid cysts caused by Echinococcus granulosus. Surgery 2005; 137: 312-6.
4. Kjosson KT, Losanoff JE: Classification of hydatid liver cyst. Journal of Gastroenterology and Hepatology 2005; 20:352-359.
5. Kayaalp C, Bzeizi K, Demirbag AE, Akoglu M: Biliary complications after hydatid liver surgery: incidence and risk factors. J Gastrointest Surg 2002;6:706-712.
6. Frider B, Larrieu E, Odriozola M: Long-term outcome of asymptomatic liver hydatidosis. Journal of Hepatology 1999;30:228-231.

Author Information

Giovanni Guercio

University Researcher, GEN.UR.T.O. (Department of General Emergency and Transplant Surgery), Unit of General and Geriatric Surgery, University Hospital Policlinico “P. Giaccone”

Calogero Ricotta, MD

GEN.UR.T.O. (Department of General Emergency and Transplant Surgery), Unit of General and Geriatric Surgery, University Hospital Policlinico “P. Giaccone”

Guiseppe Diana

Ordinary Professor of Surgery, GEN.UR.T.O. (Department of General Emergency and Transplant Surgery), Unit of General and Geriatric Surgery, University Hospital Policlinico “P. Giaccone”