

# A Rare Differential Diagnosis For Ascites

A Karthikeyan, G Sivaprasad, L Gnanaraj

## Citation

A Karthikeyan, G Sivaprasad, L Gnanaraj. *A Rare Differential Diagnosis For Ascites*. The Internet Journal of Gastroenterology. 2004 Volume 4 Number 1.

## Abstract

Giant hydronephrosis is a term used to describe a hydronephrotic kidney with more than one litre of urine.<sup>1</sup> We report about a 23 years old man in whom repeated tapping of the hydronephrotic kidney was done due to an erroneous diagnosis of ascites. On evaluation he had giant hydronephrosis. Nephrectomy was done to relieve his symptoms.

## INTRODUCTION

Giant hydronephrosis is usually caused by congenital pelviureteric junction obstruction (PUJ). Impacted stones at PUJ<sub>2</sub> and ureterovesical junction<sub>3</sub> obstruction have also been reported as causes for giant hydronephrosis.

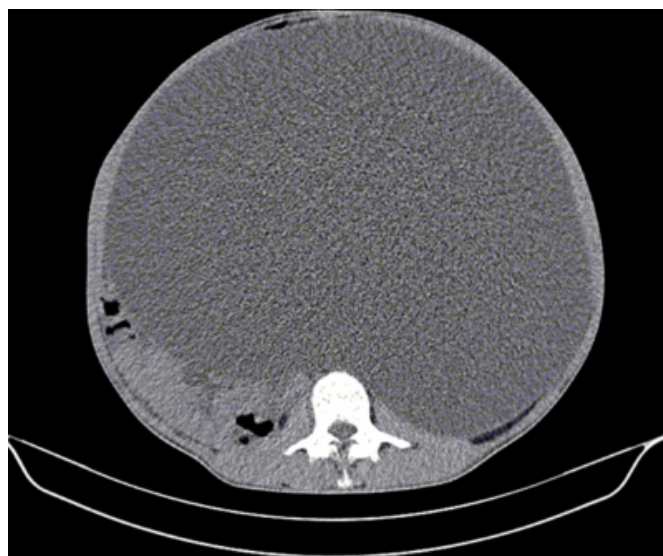
## CASE REPORT

A 23 year old man presented with diffuse progressive distension of the abdomen for the past ten years with exceptional dyspnoea. Paracentesis was done on three occasions and he had transient relief of symptoms. On examination there was diffuse distention of the abdomen with fluid thrill. Cardiovascular system was clinically normal.

Renal and liver functions were normal. Computed Tomography (Fig.1) of the abdomen revealed a huge cystic mass occupying the abdomen displacing the bowel to the right. Left kidney could not be visualized. An isotope study revealed a photopenic area in the left renal bed with no tracer uptake at three and half hours. Left subcostal exploration revealed a massive hydronephrotic kidney containing 22 liters of urine with PUJ obstruction. A left nephrectomy was done and he had symptomatic relief. A biopsy confirmed the clinical diagnosis of PUJ obstruction with evidence of chronic pyelonephritis. In poorly functioning hydronephrotic kidneys or with pyonephrosis the treatment of choice is nephrectomy. If the kidney is salvageable reconstructive procedures like pyeloplasty, calicovesicostomy<sub>4</sub> and Boari flap calico vesicostomy<sub>5</sub> can be done. Nephrectomy was done for our patient, as the kidney was nonfunctioning.

## Figure 1

Figure 1: Huge cystic mass on a CT scan displacing the bowel.



## CONCLUSION

Giant hydronephrosis presenting as a large abdominal mass mimicking ascites is a rare entity. Erroneous treatment can lead to persistence of symptoms, pyonephrosis and septicemia.

## ADDRESS FOR COMMUNICATION

Dr.Lionel Gnanaraj Prof. of Urology Christian Medical College Vellore – 632 004, Tamilnadu, India Phone No.: +91-0416-2282055 Fax No. : 0091-416-2232035 E-Mail: uro1@cmcvellore.ac.in

## References

1. Earham M S. Giant hydronephrosis. J Urol 1950; 63:195.
2. Kruger E. Giant hydronephrosis and contralateral ureteric bud. Problem of differential diagnosis. Urologe A 1993;

32:316-319.

3. Haque J, Mukherjee B, Prasad GR, Mitra SK, Pathak IC. Ureterovesical junction obstruction presenting as giant hydronephrosis. Indian J Pediatr 1985; 52:107-9.

4. Krzeski T, Milewski JB, Borkowski A et al.

Calycocystotomy in the treatment of giant hydronephrosis. Eur Urol 1987; 13:42.

5. Kumar A, Sharma SK, Madhoosudan P, Dhar ML. Indications for Boari flap calicovesicostomy. Br J Urol 1988; 60:367-8.

**Author Information**

**Aswathaman Karthikeyan, M.S.**

Senior Registrar, Department of Urology, Christian Medical College

**Gourabathini Sivaprasad, MS, MCh (Urol)**

Lecturer, Department of Urology, Christian Medical College

**Lionel Gnanaraj, MS, MCh (Urol)**

Professor, Department of Urology, Christian Medical College