

A rare association of parotid oncocytoma, lipoma, multinodular goitre and uterine adenomyosis

P Sinha, S Sharma, S Agarwal, R Ray

Citation

P Sinha, S Sharma, S Agarwal, R Ray. *A rare association of parotid oncocytoma, lipoma, multinodular goitre and uterine adenomyosis*. The Internet Journal of Otorhinolaryngology. 2007 Volume 7 Number 2.

Abstract

Objective: To demonstrate the syndromic association of cutaneous lesions, multinodal goitre, lipoma and uterine adenomyosis in a patient with parotid oncocytoma.

Case report: Oncocytoma is a rare tumor of the parotid gland. We describe a patient who presented with parotid oncocytoma in association with multiple cutaneous lesions, multinodular goitre, lipoma and uterine adenomyosis. The constellation of above lesions suggested a possibility of Birt-Hogg-Dube syndrome (BHDS). BHDS is a rare syndrome presenting with peculiar cutaneous lesions in varying combinations with multiple tumors. A review of literature did not reveal any previous reports on presence of uterine adenomyosis in a patient with BHDS.

Conclusion: Patients of BHDS may present with various head and neck manifestations. This makes its awareness important so that a complete systems review may direct appropriate age and gender-specific screening for malignancies. We also propose to add uterine adenomyosis to the list of tumors observed to be associated with BHDS.

INTRODUCTION

Oncocytoma constitutes 0.4 - 1% of all parotid tumors. They are less commonly seen in minor salivary glands, thyroid, parathyroid, mucous glands of nose, larynx, tracheobronchial tree, liver, esophagus, stomach, kidney, pancreas, testicles and fallopian tube. Reports exist suggesting association of parotid oncocytoma with Birt-Hogg-Dube syndrome.

Birt-Hogg-Dube syndrome (BHDS) is an inherited genodermatosis which describes a constellation of cutaneous lesions in association with a multitude of conditions some of them being: parotid oncocytoma, lipoma and multinodular goitre.

We report a patient with parotid oncocytoma and cutaneous lesions peculiar to Birt-Hogg-Dube syndrome along with lipoma, multinodular goitre and uterine adenomyosis.

CASE REPORT

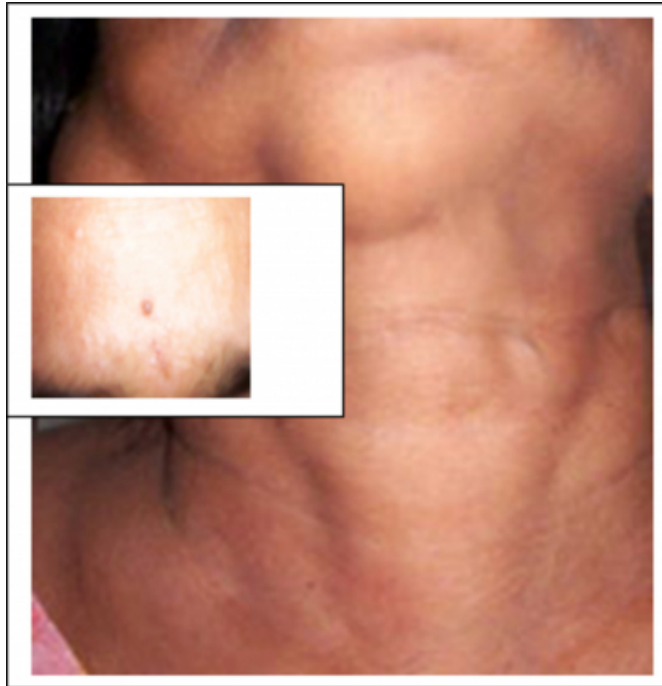A forty seven year old female presented with progressively increasing swellings in right parotid and submental region for four years. She had lesions in scalp and face which

appeared about ten years back. She was on thyroxine supplementation for multinodular goitre. She had undergone hysterectomy two years back for uterine adenomyosis.

Physical examination (Fig.1) showed a 6x6 cm non-tender mass in right parotid region. A 3x3 cm mobile mass with soft consistency was present in submental region. A 2x2 cm mass, moving with deglutition, was palpable in left thyroid lobe. Cutaneous examination revealed multiple 1-2 mm skin coloured papules on face, scalp, neck and upper trunk along with melanocytic naevi.

Figure 1

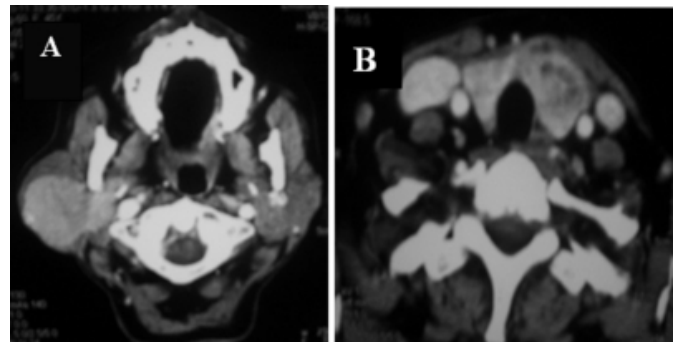
Figure 1: Multiple neck swellings & cutaneous lesions (inset)



Cytology from the parotid mass, submental swelling and thyroid lobe was reported as oncocytoma, lipoma and colloid goiter, respectively. Contrast enhanced CT imaging showed a well circumscribed enhancing lesion of the entire right superficial lobe of parotid gland extending into deep lobe (Fig.2). Enlargement and diffuse enhancement of left thyroid lobe was also seen. The cutaneous lesions on scalp and face were diagnosed by the dermatologist to be multiple fibrofolliculoma with a few melanocytic naevi. On these findings patient was diagnosed to be a possible case of Birt-Hogg-Dube syndrome. Ultrasonogram was performed to rule out any renal pathology known to be associated with this syndrome.

Figure 2

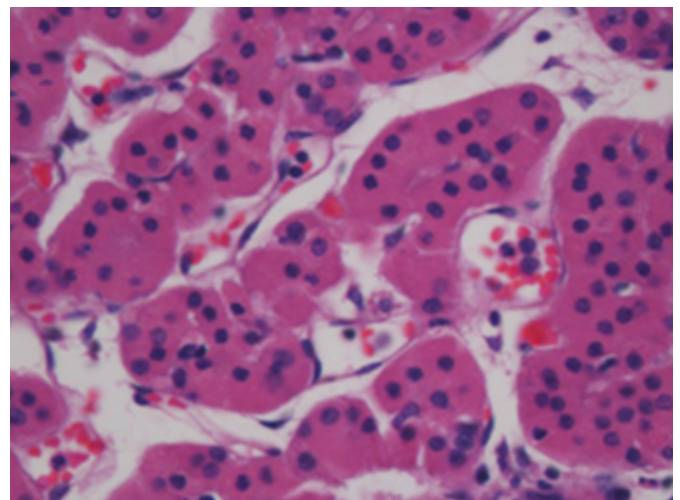
Figure 2: CT films showing (A) enhancing mass in superficial and deep lobe of parotid; (B) enlarged left thyroid lobe



The patient was planned for surgery. Total parotidectomy was performed to remove the right parotid tumor, preserving all branches of facial nerve. Lipoma was also excised in the same sitting. Histopathology confirmed the tumors to be parotid oncocytoma and lipoma, respectively (Fig. 3).

Figure 3

Figure 3: Microphotograph of parotid tumor showing oncocytes (H&E stain $\times 400$)



DISCUSSION

Oncocytomas are very rare tumors accounting for less than 1% of all parotid tumors¹. They usually present as slow growing unilateral parotid mass in age group of 50-70 years with a slightly greater preponderance in females¹. They are characterized by oncocytes which are cells originating from somatic transformation of epithelial cells lining salivary gland ducts and acini². Histopathologically they appear as polygonal cells with small rounded nuclei and intensely staining eosinophilic granular cytoplasm.

Parotid oncocytoma has been seen to be associated with

Birt-Hogg-Dube syndrome³. Birt, Hogg and Dube reported in 1977 about autosomal transmission of facial papules in a large family several of whose members were also afflicted with medullary cancer thyroid⁴. These papules were described to be a classical triad of fibrofolliculoma, trichodiscoma and acrochordons. Fibrofolliculoma are alone sufficient to be diagnostic of this syndrome. BHDS locus has been mapped to chromosome 17p12-q11.2⁵. It encodes a novel protein named follicullin. Though the mode of inheritance is autosomal dominant with variable penetrance, sporadic cases have also been observed⁶. The cause of mesodermal proliferation is not clear but an ectodermal – mesodermal interaction has been theorized. Studies have suggested that BHD gene may be a tumor suppressor gene, mutation of which leads to cutaneous and internal neoplasia⁶. In our patient, family history was negative for similar facial lesions, pointing towards a possible sporadic manifestation of the syndrome.

BHDS has been reported to be associated with renal tumor⁶ (oncocyoma, chromophobe renal cell carcinoma), colonic polyp and adenocarcinoma⁷, mucocutaneous lesions like flecked chorioretinopathy⁸ and other comorbid factors like pulmonary cysts and spontaneous pneumothorax⁵.

The syndrome has a myriad of known head and neck manifestations in the form of parotid oncocyoma³, medullary carcinoma thyroid⁴, parathyroid adenoma⁹, multinodular goitre¹⁰, lipoma⁹ and connective tissue naevus¹¹ and oral mucosal papules.¹²

Parotid oncocyoma, multinodular goitre, lipoma and a history of uterine adenomyosis with endometrial polyps in our patient with striking cutaneous lesions pointed towards possibility of some syndromic association. A search in literature followed by evaluation by dermatologist suggested the possibility of BHDS.

Uterine adenomyosis and endometrial polyps was a novel finding present in our patient. It has not yet been described in females with BHDS. Mesodermal proliferation, postulated as a basis of the internal neoplasia in BHDS, is an event observed in uterine adenomyosis as well. However, in this case, whether the association is merely coincidental or causal remains to be substantiated.

Presence of the above mentioned head and neck conditions in varying combination with peculiar cutaneous lesions should raise a suspicion of BHDS. It is important to be aware of the condition because failure in identification may

lead to development of serious complications, later in life. Hence, a complete physical examination and review of all physiological systems is warranted. Renal function test, thyroid function tests, colonoscopy, chest and renal imaging need be carried out to screen the known causes of morbidity in patients suspected of this syndrome. An addition to the already proposed battery of investigations may be pelvic examination and imaging in females afflicted with BHDS since uterine adenomyosis can be a risk factor for development of endometrial carcinoma¹³. The usual dominant mode of inheritance of this syndrome and risk of visceral neoplasia makes genetic counselling, yet another significant arena of management.

CORRESPONDENCE TO

Dr.Parul Sinha

Department of Otorhinolaryngology-Head & Neck Surgery,
All India Institute of Medical Sciences,
New Delhi-110029, India.

References

1. Johns ME, Regezi JA, Batsakis JG: Oncocytic neoplasms of the salivary glands: An ultrastructural study. *Laryngoscope* 1977; 87: 862-71.
2. Ellis GL, Auclair PL. Oncocytoma in tumors of the major salivary glands. Washington (DC): Armed Forces Institute of Pathology. 1996; p.103-14.
3. Liu V, Kwan T, Page HE. Parotid oncocyoma in Birt-Hogg-Dube syndrome. *Am Acad Dermatol*. 2000; 43:1120-1122.
4. Birt AR, Hogg GR, Dub?J. Hereditary multiple fibrofolliculomas with trichodiscomas and acrochordons. *Arch Dermatol* 1977;113:1674-77.
5. Schimdt LS, Warren MB, Nickerson ML. Birt-Hogg-Dube syndrome, a genodermatosis associated with spontaneous pneumothorax and kidney neoplasia maps to chromosome 17p11.2. *Am J Hum Genet* 2001; 69: 876-82.
6. Toro JR, Glenn G, Duray P, Darling T, Weirich G, Zbar B. Birt-Hogg-Dub?syndrome: a novel marker of kidney neoplasia. *Arch Dermatol* 1999;135:1195-202.
7. Rongioletti F, Hazini R, Gianotti G, Rebora A. Fibrofolliculomas, trichodiscomas, and acrochordons (Birt-Hogg-Dub? associated with intestinal polyposis. *Clin Exp Dermatol* 1989;14:72-4.
8. Walter P, Kirchhof B, Korge B, Heimann K. Flecked chorioretinopathy associated with Birt-Hogg-Dub?syndrome. *Graefes Arch Clin Exp Ophthalmol* 1997; 235: 359-61.
9. Chung JY, Ramos-Caro FA, Beers B, Ford MJ, Flowers F. Multiple lipomas, angioliipomas, and parathyroid adenomas in a patient with Birt-Hogg-Dub?syndrome. *Int J Dermatol* 1996; 35: 365 -7.
10. Drummond C, Grigoris I, Dutta B. Birt-Hogg-Dube syndrome and multinodular goitre. *Australas J Dermatol*. 2002;43:301- 4.
11. Jacob CI, Dover JS. Birt-Hogg-Dub?syndrome: Treatment of cutaneous manifestations with laser skin resurfacing. *Arch Dermatol* 2001;137:98-99.
12. Nadershahi NA, Wescott WB, Egbert B. Birt-Hogg-Dub?syndrome: a review and presentation of the first case

with oral lesions. Oral Surg Oral Med Oral Pathol Oral
Radiol Endod 1997; 83:496-500.
13. Takeuchi K, Yamanaka Y, Hamana S, Ohara N, Maruo

T. Invasive adenocarcinoma arising from uterine
adenomyosis involving rectosigmoid colon. Int J Gynec
Cancer.2004;14: 1004-06.

Author Information

Parul Sinha, MS

Research Fellow, Department of ENT, All India Institute of Medical Sciences

Suresh Chandra Sharma, MS

Professor, Department of ENT, All India Institute of Medical Sciences

Shipra Agarwal, MD

Senior Resident, Department of Pathology, All India Institute of Medical Sciences

Ruma Ray, MD

Associate Professor, Department of Pathology, All India Institute of Medical Sciences